51.173

Bd. May, 1885.



ROBERT TROUP PAINE
TO
HARVARD COLLEGE.
A LEGACY
IN HIS NAME BEING APPLIED
IN PART TO AN ANNUAL INCREASE
OF THE LIBRARY

Received 9 April, 1879.

Boston Oct. 23. 1825

Dear sir,

Mr. Thayer (allen) of mendon, if I mistake not, has ~~sometime~~ told me that you practise in his family, and from this circumstance I am induced to ~~you~~ communicate to you a detailed account of his recent sickness in this city.

On Friday about 11 o. clock the 21st Mr. T. called me to his lodging room. I found him labouring under most excruciating pain about the region of the right breast. no posture in which he could place himself would give relief even for a moment, - respiration ~~was~~ extremely difficult - countenance flushed - pulse 112 tongue coated - fever. - I was induced at first to regard his case as pure pluritis. In this opinion I was obliged to take great latitude from the fact that his pulse was much to frequent and soft for that affection ~~as I had generally found it.~~ A blister was applied ~~over~~ over the part affected, and an ounce of castor oil administered. I saw him again about 1. o. clock, and notwithstanding the pulse was frequent and easily compressed. I concluded to take blood ~~small quantity of blood~~, the quantity of which should be governed by the effect it produced upon the system during the operation

I took away 10. oz which induced partial fainting and found the pulse reduced to 100, with some increase of fullness.

The oil produced two or three discharges of a thin watery greenish coloured fluid. The pain was during the night less severe. He was quite restless all Friday night. and on Saturday morning I found his pulse again at 112 The blister which had drawn well, was removed and the vesicated surface dressed with simple cerate during the forenoon of Saturday he was somewhat freer from pain but on its returning again in the afternoon I ordered 30 m. of Laudanum. I saw him again at 6. o. clock and observed what what I had not before an irregularity in the pulse there was an intermission once in 3 or five beats I proposed to Mr T. to invite in my worthy instructor Dr. S. he acceded to the proposit and in the evening I accompanied Dr S. to his lodgings. Dr S. after satisfying himself as to the correctness of my views of the dis. advised the reapplicate of the blister on the stomach and colon and also recommended Tinct Sang ℥ii with Tinct opii ℥ss. to commence with a table spoonful and repeat once in three hours half the quantity. garlicks were also applied to the feet. Sundy morning found him without fever though the pulse was quite frequent with occasional intermission. gave through day the Sang. and dig italis. not together.

Monday morning found him rather easier. his discharges were less frequent. pulse 84 without any intermission. ordered him 10 drops of Dig. Tinct. which was repeated again at twelve. During the afternoon I saw him again his pulse 120 and the pain more acute. I here felt some little diffidence in proposing what I considered the only true cause of practice of phy. particularly a young man can not always be certain that he satisfies his patient however I ventured to propose again to vesicate the surface high up on the right breast which after much talking he agreed to submit to. I left him in the evening directing that should he not have any discharge by 3. a. clock on tuesday morning a dose of castor oil and Sp. terebinth in the proportion of ℥ss to the ounce to ℥ii of the latter.

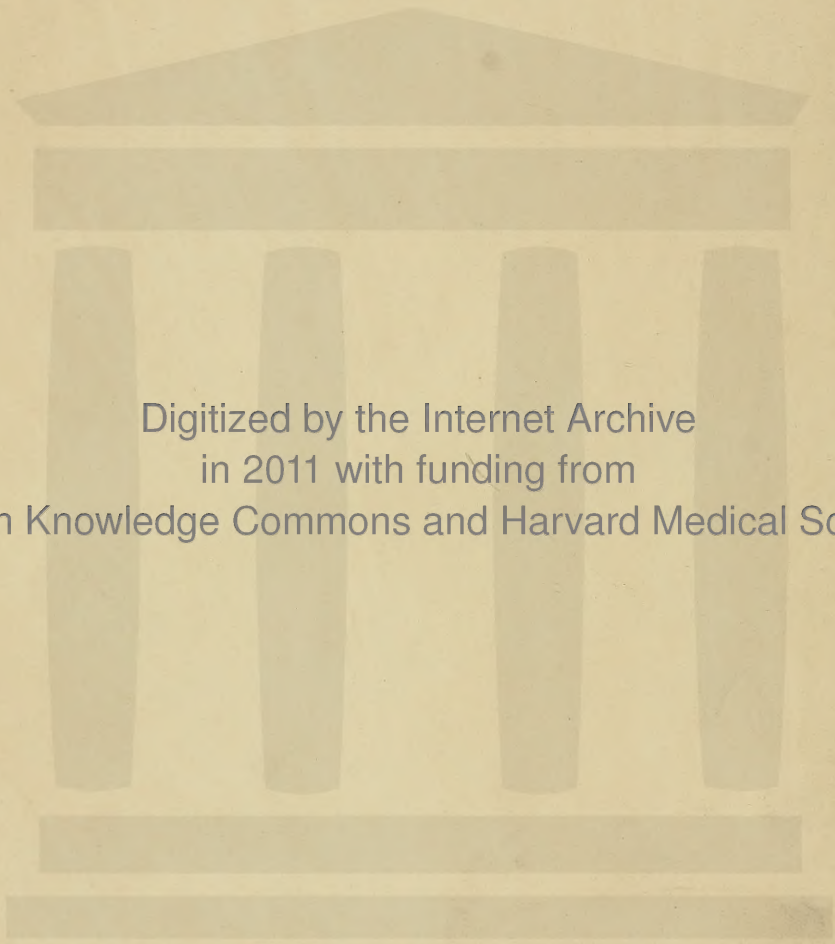

Digitized by the Internet Archive
in 2011 with funding from
Open Knowledge Commons and Harvard Medical School

http://www.archive.org/details/treatiseondisloc00coop

6-1-9
36 4

A

TREATISE

ON

DISLOCATIONS,

AND ON

FRACTURES

OF THE

JOINTS.

Robert Brough Paine
Jr
Harvard College.

LONDON:
PRINTED BY F. WARR,
RED LION PASSAGE, HOLBORN.

A

TREATISE

ON

DISLOCATIONS,

AND ON

FRACTURES

OF THE

JOINTS.

BY SIR ASTLEY COOPER, BART., F.R.S.
SURGEON TO THE KING,
&c., &c., &c.

FOURTH EDITION.

LONDON:
PUBLISHED FOR THE AUTHOR,
BY MESSRS. LONGMAN, HURST, REES, ORME, BROWN, AND GREEN, PATERNOSTER ROW;
S. HIGHLEY, 174, FLEET STREET; T. & G. UNDERWOOD, 32, FLEET STREET;
AND COX & SON, ST. THOMAS'S STREET, SOUTHWARK.

MDCCCXXIV.

TO THE

STUDENTS OF SAINT THOMAS'S AND GUY'S HOSPITALS.

My Dear Young Friends,

This Work having been composed for your use, my principal object will be attained if you derive advantage from it. I cannot, however, omit to embrace the opportunity of expressing my gratitude for the affectionate and respectful manner in which you have always received me as your instructor. Your parents and relatives, many of whom were my pupils, are also entitled to my most grateful acknowledgments; they fostered me in early life; and by their friendship and recommendation have largely contributed to procure to me a degree of success which, I fear, is beyond my merits, and a course of uninterrupted happiness which few have been permitted to enjoy.

Believe me, always,

Your affectionate Friend,

ASTLEY COOPER.

PREFACE

TO THE FOURTH EDITION.

It is incumbent on me to observe, that although I believe the matter of this Work to be correct, and regard it as the result of a considerable share of experience, yet, I am aware that the reader may detect a too familiar mode of expression, and may censure me for want of attention to its style. The familiarity of the language arises from my desire to be perspicuous. I prefer a significant expression to a finely turned sentence, just as I would a good plain suit to the finest embroidered dress, and am ready to own, that I think much more of the matter which I give, than of the manner in which it is conveyed.

I am much indebted to my friends for their communications; the life of man is too short to allow him, even with the greatest industry, zeal, and opportunity, to witness all the varieties of accident or disease; and I should feel that I was not properly discharging my duty, if I omitted to take advantage of all the evidence which might be adduced by those on whom I could depend.

Whilst, then, I sincerely thank my friends for their kindness, I wish to state to them and to others, that they will always oblige me, by giving me any information which it is in their power to convey upon this or any other subject in surgery.

In looking over the following pages on dislocations, I feel that my professional brethren will be disposed to think that I have limited to too short a period the attempts at reduction. It has been stated, that dislocations have been reduced at four and even six months after the injury had been received, which I am not disposed to deny; indeed, I have myself had an opportunity of witnessing examples of the fact; but, excepting in very emaciated, relaxed, and aged persons, I have observed that the injury done in the extension, has been greater than the advantage received from the reduction; and, therefore, in the case of a very strong muscular person, I am not disposed, after three months, to recommend the attempt, finding that the use of the limb is not, when reduced, greater than that which it would have acquired by having remained in its dislocated state. Let this be fairly represented to the patient; and then, at his request only, the reduction should be attempted; but "with all appliances and means to boot," the extension must be very gradually made, and without violence, to avoid injury to the muscles and nerves.

I have stated, that in fractures of the upper part of the thigh-bone, the foot is generally everted; to which there is

sometimes an exception; for I have seen a case of Mr. Langstaff's, surgeon in the City, in which the foot was inverted, and the bones, although they rubbed against each other, had not united.

Mr. Guthrie considers it probable, that the inversion of the foot in fractures of the upper part of the thigh-bone, which now and then happens, arises from a diagonal fracture through the trochanter major. The gluteus medius and minimus, with the tensor vaginæ femoris, draw the thigh-bone forwards, and roll it inwards. He shewed me a preparation which confirmed this opinion.

I have received from Mr. Brindley, surgeon of Wink Hill, an account of a dislocation of the os femoris, which the patient is able to produce and reduce when he chooses; the man is fifty years of age. Mr. Morley, of Uttoxeter, has transmitted to me a case of compound fracture of the head of the os humeri; the end of the bone was sawn off, the bone reduced, and the patient did well; the length of the limb differed but little from that of the other. And Mr. White, of the Westminster Hospital, has shewn me a case of dislocation of the os femoris from ulceration, in which the head of the femur was sawn off, and the person recovered.

I have been accused of publishing doctrines, respecting fractures of the neck of the thigh-bone, which differ from those of my medical brethren, and this I am ready and proud to acknowledge;

on the other hand, I have heard that I am abused for not having acknowledged that others had previously given similar opinions. To this animadversion I have only to reply, that I began to deliver lectures in the year 1792, and that I never failed in them to give publicity to the opinions which I have here advanced. I have procured early copies of my lectures, taken by some of my students, and I could obtain a great number of others, which shew that my opinions of non-union were those which this book contains. By a comparison of the dates of my lectures, with that of the publication alluded to,* it will be readily seen who had the priority in forming those opinions.

UNION OF THE FRACTURED CERVIX.

The earliest notes of my lectures, and I began to give lectures in 1792, ran thus:

Fractures of the Thigh-Bone at its Cervix.

"These fractures seldom, if ever, become afterwards united, for which two reasons may be given; *first,* that the uniting matter is thrown into, and lost in the joint; and, *secondly,* that the fractured portions of the bone are not in apposition, the

---

* Principles of Surgery, by John Bell, published in 1801.

thigh-bone being drawn from its head (which still remains in its socket) by the action of the glutei muscles."

Extract from Sir ASTLEY COOPER'S *Surgical Lectures, delivered in the year* 1793, *taken from the notes of Mr.* FISKE.

"When a bone which forms part of a joint is fractured transversely, union seldom takes place between the fractured ends, as in the patella and olecranon; where the same effusion of blood takes place, but is lost in the cavity of the joint, from which it receives vessels and becomes of a ligamentous substance. When the cervix of the os femoris is fractured, it becomes united to the capsular ligament by bands; the reason for this kind of union taking place is exactly the same as in a trepanned skull; for the action of the muscles inserted into the upper part of the bone draws it upwards, and those into the lower part draw it downwards, and the space becomes too great for the vessels of the bone to shoot into the coagulated blood and form it into bone. This, I think, will hold good, though it is different from the opinion of many men."

CHARLES FISKE.

Saffron Walden;
Nov. 14*th*, 1824.

From Mr. Lukyn, of Feversham.

Dear Sir,

I am sorry to say that my notes on your surgical lectures, delivered in 1793, are very short: in the one on simple fractures you said, "There are some fractures that happen in joints that never unite, as in the neck of the thigh-bone; the blood is extravasated into the joint, and only ligamentous matter deposited, the vessels shooting into the coagulum coming from the ligament. Another reason is, the parts cannot be kept in apposition."

I remain, dear Sir,

Feversham, Your very obedient Servant,

Nov. 12th, 1824. Robert Lukyn.

From Dr. Pidcock, of Watford.

My dear Sir,

In a copy I made of the lecture on simple fractures there is this brief remark on the subject of your inquiry: "In fractures of the cervix femoris, the ends of the bone are never opposite to each other; the callus is thrown into the acetabulum, and union never takes place."

Watford; I remain, very faithfully your's,

Nov. 14th, 1824. John Pidcock.

Pupil in 1794-5.

From Mr. Pulley, of Bedford.

Dear Sir,

I send you with much pleasure your observations on fractures of the neck of the thigh-bone. You will find my language incorrect in some parts, owing to the hurry of transcribing, arising from the multiplicity of matters then to be attended to; but I can vouch for the accuracy of the statement, and had much rather send you an exact copy of the lecture now in my possession, not knowing the reason of your present application.

" Fracture of the neck of the thigh-bone:—This fracture never unites; tell the patient this, and that he must be lame for life. When the injury happens with persons not more than fifty-five years of age, the recovery may be so far that the patient may be able to walk with a stick; but should it happen with very old people, they will never after be able to walk out without crutches. The fractured cervix does not unite, because the extravasated matter, or coagulable lymph thrown out for union, is lodged in the joint, so that it is not applied to the ends of the bone; besides, union cannot be effected, as the ends of the bone are so far removed from each other. Attempts have frequently been made to effect an union, but they have never succeeded."

I remain, dear Sir,

Bedford; Your most obedient Servant,

Nov. 12*th*, 1824. John Pulley.

Pupil in 1796.

From Mr. Weekes, of Hurtspur Point, Sussex.

Dear Sir,

I am sorry I have been prevented answering your letter before; but upon referring to your lectures I find the following observations, viz.:

"Of fracture of the cervix femoris: This is of frequent occurrence, but seldom or ever happening but in people of advanced age. These fractures are often supposed to be cured, but in reality they never are. People, after these fractures, should always walk with a stick; and if they are stout and fat, crutches are admissible.

"The reason why fractures of the cervix femoris do not get well so soon as fractures of the trochanter, is, that in the former the callus becomes extravasated in the joint, and renders union of the bone impracticable."

I remain, dear Sir,

Your very humble Servant,

Hurtspur Point, H. Weekes.

Sussex.

Pupil in 1796.

From Mr. Overend, of Sheffield.

Dear Sir,

In referring to my notes of your lecture on fracture of the cervix femoris, delivered in the year 1797, I find the following

observations. After describing the appearances indicating the fracture of this part of the thigh-bone my notes state:

"A crepitus in fracture of the cervix femoris can never be observed, originating from the two extremities of the broken bone never being in contact, and, consequently, a bony union never takes place; in the first instance, from the want of contact; and, secondly, from extravasation surrounding the affected part, which progressively becomes vascular, and forms a ligamentous union, if union at all."

Your obedient humble Servant,

Sheffield; HALL OVEREND.

Nov. 14*th*, 1824.

Dr. JEFFRIES, *of Liverpool, took the following notes of my Lectures in the year* 1797.

"In the cervix femoris, an union never takes place; the leg is much the shortest, the foot and knee turned outwards, and great motion at the hip-joint: occurs only in old people. The fractured surfaces become smooth by callus, but no union ever follows, because the two pieces of bone are never applied, and the callus matter is lost within the cavity of the joint."

From Mr. ALEXANDER, *of Newbury.*

"The cervix of the os femoris is a part that never unites. It

is an accident which generally occurs in old people after the age of fifty-six; the limb becomes shortened, and the knee and foot turned outwards. Ligamentous matter only is poured out into the joint and around the head of the bone."

RICHARD H. ALEXANDER.

Attended in 1797-8-9; believe the notes were taken in 1798.

From Mr. ROSE, of High Wycombe.

DEAR SIR,

I am sorry to have been prevented by various engagements attending to your request earlier, in sending you the extract from the lecture delivered by you, on the subject of fracture of the cervix of the os femoris, in the year 1798.

"The reason why this fracture does not unite; *first*, one cause is, that the callus is effused into the cavity of the joint; *secondly*, the head of the bone cannot be kept in apposition with the cervix, which explains why the patient is always lame."

You then related some cases published by Desault, wherein he stated his having succeeded, and union had taken place; but as they were in young subjects, you expressed your opinion, that they were fractures of the trochanter, and not of the cervix.

I am, dear Sir,

Your faithful and obedient Servant,

WILLIAM ROSE.

High Wycombe;
Aug. 30*th*, 1824.

Notes on Fracture of the Neck of the Thigh-Bone, taken from Sir Astley Cooper's Lectures in 1799, *by W. Jackson.*

"This fracture never unites, therefore you must inform your patients they will always be lame."

The expression of never uniting is a little too strong, for it will be seen in my work that I have mentioned certain exceptions in which such union might be possible; but still, lameness is a never-failing consequence; it may be also stated that in addition to the two causes of want of union which I have mentioned, there is a third, which I have much dwelt upon in this work, viz., the supply of blood to the head of the bone being cut off (excepting through the medium of the ligamentum teres) by the laceration of the reflected ligament and periosteum.

The question of union or non-union of the fracture of the neck of the thigh-bone, as a general principle, involves very important consequences; as the lameness which invariably follows these accidents would expose every surgeon in the kingdom to an action for neglect or want of skill, if such fractures would unite so as to render the limb firm, and prevent the lameness which in every case I ever saw was the uniform result, although union in a large proportion of them was attempted.

If I were called upon to give my evidence in a court of justice in such a case, I should say, that the lameness which was the

result was not imputable to any want of skill, but to the nature and seat of the fracture, as I have never seen an instance in which it did not occur. But to those who hold a contrary opinion, all that could be said is, that you have exposed yourself to this action from want of proper attention to the issue of these accidents, "and out of thy own mouth shalt thou be condemned."

Since writing the above observations, I have received the following letter and case.

DEAR SIR ASTLEY,

I beg to forward you a note of a case of fracture within the capsular ligament, which fully illustrates your opinion of the nature and consequences of that injury. I have abstained from drawing any conclusions on the case, confining myself to its history and dissection. The bones, not yet subjected to any preparation, are in my possession, and if considered as worthy a place in the museum, I shall feel great pleasure in forwarding them to you.

I am, with great respect,

Sheerness; Your obedient Servant,

Dec. 1*st*, 1824. ARCH. ROBERTSON.

CASE.

On the 25th of June, 1822, William Daruin, aged sixty-two, a tall athletic convict, of a sanguine temperament, fell with a very

inconsiderable violence across a piece of timber in the Dock-yard, his left hip coming in contact with the wood. On rising, he felt an acute pain in the region of the acetabulum, but no other inconvenience, for he walked on board to exhibit himself to the surgery man. From finding him *ranked up* with the sick of the hulk on my morning visit of the 26th, from his walking on board, and from his own account of the accident, I did not suspect any serious injury of the joint, and treated the case as one of concussion. On the 29th, however, he complained of a very sudden, and very agonizing accession of pain, which induced me to subject him to a more critical examination. No evident alteration in the size of either hip could be discerned, but a shortening of the limb was conspicuous, which was rendered more evident by making him stand on the sound limb; extension removed this difference, but on being freed from restraint, it again assumed its morbid shape; the knee and foot were everted, and rotation greatly increased his pain.

I removed him to the hospital as a case of fracture within the capsule, but a continued attention for a period of six months to position (chiefly with the view of restraining the motion of the pelvis, and of securing the limb), made no other alteration in the symptoms than a gradual diminution of pain. A pair of crutches were given him, he was placed on the invalid list, and remained so till the 26th of December, when he died from general dropsy.

On dissection, the injury proved a transverse fracture of the

head of the femur within the capsular ligament. No species of union had taken place. The upper portion of the fractured bone was retained in situ by the sound ligament; tolerably smooth on its surface, but without any ossific deposit. The lower portion very irregular, with several detached pieces of bone adhering to the insertion of the capsular ligament. Between the acetabulum and the portion of bone retained in situ by the ligament, several small oval shaped loose cartilaginous substances, apparently fragments of bone. The capsular ligament partially lacerated, in a line above the trochanter major, and greatly thickened in its insertions.

Convict Hospital Ship,
Sheerness, 1st Dec. 1824.

ARCH. ROBERTSON.

I may be permitted to add here, that I have just added to the collection at St. Thomas's Hospital, a fracture of the patella; in which the portions of bone are in contact, and in which an ossific union appeared at first sight to have been produced, and in the living body it must have been concluded to be united; yet the union is only ligamentous.

A. C.

Dec. 1824.

CONTENTS.

	Page.
On Dislocations in general	1
Particular Dislocations	31
Dislocations of the Hip-joint	31
Dislocation upwards, or on the Dorsum Ilii	33
Dislocation downwards, or into the Foramen Ovale	56
Dislocation backwards, or into the Ischiatic Notch	68
Dislocation on the Pubes	82
Fractures of the Os Innominatum	94
Fractures of the Upper Part of the Thigh-bone	102
Fractures of the Neck of the Thigh-bone, within the Capsular Ligament	104
Additional Observations on Fractures of the Neck of the Thigh-bone	139
Fractures of the Cervix Femoris, external to the Capsular Ligament, and into the Cancelli of the Trochanter Major	144
Fractures through the Trochanter Major	156
Fracture of the Epiphysis of the Trochanter Major	169
Fractures below the Trochanter	171
Dislocations of the Knee	174
Dislocation of the Patella	176
Dislocation of the Patella upwards	179
Dislocation of the Tibia at the Knee-joint	181
Partial Luxation of the Thigh-bone from the Semilunar Cartilages	186
Dislocation of the Knee-joint	190
Compound Dislocation of the Knee-joint	191
Dislocation of the Knee from Ulceration	194
Fractures of the Knee-joint	196
Fracture of the Patella	196
Perpendicular Fracture of the Patella	205
Compound Fracture of the Patella	208

PAGE.

Oblique Fractures of the Condyles of the os Femoris into the Joint - 212
Compound Fracture of the Condyles of the Femur - - - 215
Oblique Fractures of the Os Femoris, just above its Condyles - 217
Compound Fracture, just above the Condyles of the Os Femoris - 219
Simple Fracture above the Condyles of the Os Femoris - - 221
Fracture of the Head of the Tibia - - - - - 225
Dislocations of the Head of the Tibia - - - - 226
Dislocations of the Ancle-joint - - - - - 228
Simple Dislocation of the Tibia inwards - - - - 229
Simple Dislocation of the Tibia forwards - - - - 232
Partial Dislocation of the Tibia forwards - - - - 234
Simple Dislocation of the Tibia outwards - - - - 235
Compound Dislocation of the Ancle-joint - - - - - 237
Compound Dislocation of the Tibia inwards - - - 248
Compound Dislocation of the Tibia outwards - - - 249
On removing the Ends of the Bones - - - - 278
Additional Cases of Compound Dislocation of the Ancle-joint - 304
Cases which render Amputation necessary - - - - 310
Fractures of the Tibia and Fibula near the Ancle-joint - - 330
Fracture of the Tibia at the Ancle-joint - - - - 332
Dislocation of Tarsal Bones - - - - - - 334
Simple Dislocation of the Astragalus - - - - 334
Compound Dislocation of the Astragalus - - - - - 338
Dislocation of the Os Calcis and Astragalus - - - 348
Dislocation of the Os Cuneiforme Internum - - - - 354
Dislocation of the Toes from the Metatarsal-bones - - - 355
Dislocations of the Lower Jaw - - - - - 357
Complete Luxation of the Jaw - - - - - 359
Partial Dislocation of the Jaw - - - - - 362
Subluxation of the Jaw - - - - - - - 363
Dislocations of the Clavicle - - - - - - 365
Junction of the Sternal Extremity of the Clavicle with the Sternum - 365
Dislocation of the Sternal Extremity of the Clavicle - - - 367

PAGE.
Junction of the Clavicle with the Scapula - - - - - 372
Dislocation of the Scapular Extremity of the Clavicle - - 373
Dislocation of the Clavicle, with Fracture of the Acromion - - 376
Structure of the Shoulder-joint - - - - - 378
Dislocation of the Os Humeri - - - - - 382
Dislocation in the Axilla - - - - - - 383
Dislocation forwards behind the Pectoral Muscle, and below the middle of the Clavicle - - - - - - 398
Dislocation of the Os Humeri on the Dorsum Scapulæ - - 403
Partial Dislocation of the Os Humeri - - - - 407
Fracture of the Neck of the Os Humeri, with the Dislocation forwards under the Pectoral Muscle - - - - - 411
Compound Dislocation of the Os Humeri - - - - 412
Partial Dislocation of the Os Humeri forwards - - - 415
Dislocation of the Os Humeri backwards - - - - 416
Fractures near the Shoulder-joint, liable to be mistaken for Dislocations 418
Fractures of the Acromion - - - - - - - 418
Fracture of the Neck of the Scapulæ - - - - - 420
Fracture of the Neck of the Os Humeri - - - - 422
Structure of the Elbow-joint - - - - - 426
Dislocations of the Elbow-joint - - - - - 430
Dislocation of both bones backwards - - - - - 430
Dissection of the Dislocation of the Elbow-joint - - - 431
Compound Dislocation of the Os Humeri at the Elbow-joint - 433
Lateral Dislocation of the Elbow - - - - - 436
Dislocation of the Ulna backwards - - - - - 437
Dislocation of the Radius forwards - - - - - 439
Dislocation of the Radius backwards - - - - 443
Lateral Dislocation of the Radius - - - - - 444
Fractures of the Elbow-joint - - - - - - 445
Fractures above the Condyles of the Humeri - - - 445
Fracture of the Internal Condyle of the Os Humeri - - 448
Fracture of the External Condyle of the Os Humeri - - - 449

PAGE.

Fracture of the Coronoid Process of the Ulna - - - 451
Fracture of the Olecranon - - - - - - 453
Compound Fracture of the Olecranon - - - - 459
Fracture of the Neck of the Radius - - - - - 459
Compound Fractures and Dislocations of the Elbow-joint - - 460
Structure of the Wrist-joint - - - - - - 464
Dislocations of the Wrist-joint - - - - - 466
Dislocation of the Radius at the Wrist - - - - 468
Dislocation of the Ulna - - - - - - 469
Simple Fracture of the Radius, and Dislocation of the Ulna - - 470
Fracture of the lower End of the Radius, without Dislocation of the Ulna 472
Compound Dislocation of the Ulna, with Fracture of the Radius - 473
Dislocation of the Carpal-bones - - - - - 477
Compound Dislocation of the Carpal-bones - - - - 479
Dislocation of the Metacarpal-bones - - - - - 482
Fracture of the Head of the Metacarpal-bones - - - 484
Dislocations of the Fingers and Toes - - - - - 485
Dislocation from Contraction of the Tendon - - - - 486
Dislocation of the Thumb - - - - - - 488
Dislocation of the Metacarpal-bones from the Os Trapezium - 489
Dislocation of the First Phalanx - - - - - 493
Dislocation of the Second Phalanx - - - - - 495
Dislocation of the Ribs - - - - - - 497
Injuries of the Spine - - - - - - - 499
Concussion of the Spinal Marrow - - - - - 502
Extravasation in the Spinal Canal - - - - - 504
Fracture of the Spine - - - - - - 506
Fractures of the Bodies of the Vertebræ, with Displacement - 509
Inflammation and Ulceration of the Spinal Marrow - - - 517

Plates and Explanations.

A

TREATISE

ON

DISLOCATIONS.

DISLOCATIONS IN GENERAL.

A DISLOCATION is a displacement of the articulatory portion of a bone from the surface on which it was naturally received. Definition.

Of the various accidents which happen to the body there are few which require more prompt assistance, or which more directly endanger the reputation of a surgeon, than cases of luxation. If much time shall have elapsed before the attempt at reduction is made, the difficulty of accomplishing it is proportionably increased, and it is not unfrequently totally impracticable: and if the nature of the injury be unknown, and the luxation consequently remain unreduced, the patient will become a living memorial of the surgeon's ignorance or inattention. "What is the matter with me?" Necessity of prompt assistance. Instances of mistake.

said a patient who came to my house, placing himself before me and directing my attention to his shoulder: "Why, Sir, your arm is dislocated."—"Do you say so! Mr. —— told me it was not out."—"How long has it been dislocated?"—"Many weeks," he replied.—"Oh then you had better not have any attempt at reduction made."—He said, "Well, I will take care that Mr. —— has no more bones to set; for I will expose his ignorance in that part of the country in which I live."—He was a man of malevolent disposition, and carried his threat into execution, to the great injury of the surgeon, who was also frequently reminded of his want of skill, by meeting his former patient in his rounds; and what was worse, by hearing the following observation frequently repeated: "Mr. ——— is a good apothecary, but he knows nothing of surgery."

In a dislocation of the os femoris, which still remains unreduced, a consultation was held upon the nature of the injury, and after a long consideration, a report was made by one of the surgeons to this effect: "Well, Sir, thank God, we are all agreed that there is no dislocation."

Knowledge of Anatomy necessary.

A considerable share of anatomical knowledge is required to detect the nature of these accidents, as well as to suggest the best means of reduction; and it is much to be lamented, that students neglect to inform themselves sufficiently of the structure of the joints. They often dissect the muscles of a limb with great neatness and minuteness, and then throw it away, without any examination of the ligaments, cartilages, or ends of the bones; a knowledge of which, in a surgical point of view, is of infinitely greater importance; and from hence arise the errors into which

they fall when they embark in the practice of their profession; for the dislocations of the hip, the elbow, and the shoulder, are scarcely to be detected, but by those who possess accurate anatomical information. Even our hospital surgeons, who have neglected their anatomy, mistake these accidents; and I have known the pullies applied to an hospital patient, in a case of fracture of the neck of the thigh-bone, which had been mistaken for a dislocation, and the patient exposed, through the surgeon's ignorance, to a violent and protracted extension. It is therefore proper, that the form of the extremities of the bones, their mode of articulation, the ligaments by which they are connected, and the direction in which their most powerful muscles act, should be well understood.

Difficulty from tumefaction.

Yet it would be an injustice not to acknowledge, that the tumefaction arising from extravasation of blood, and the tension resulting from the inflammation, which frequently ensues, will, in the early days of the accident, render it difficult for the best surgeon to be perfectly assured of the exact extent of the injury; and, therefore, conclusions drawn at a time when the muscles are wasted, and the swelling is dispersed, when the head of the bone can be distinctly felt, and the motions of the limb are found to be impeded in a particular direction, if they tend to the prejudice of the individual who may have given a different opinion under circumstances so much less favourable for forming a correct conclusion, will be both illiberal and unjust.

Symptoms.

The immediate effect of dislocation is to change the form of the joint, and often to produce an alteration in the length of the limb; to occasion the almost entire loss of motion in the part after the

muscles have had time to contract, and to alter the axis of the limb. This altered position of the limb has been attributed, by some surgeons, to the influence of the remaining portion of ligament; but, in every accident, the direction of the bone is too much the same to induce the belief of its being chiefly the effect of muscular influence; for the ligament is extensively torn, in most cases scarcely any portion of it remaining whole, particularly in dislocations of the thigh, yet the position of the limb under the different species of dislocation is found subject to little variation. The form of the bone has, however, some influence on its future position: for in fracture of the neck of the thigh-bone, the knee is turned outwards; whilst in dislocations, it is turned inwards, a difference which arises from the greater capacity of the bone to roll upon its axis when the neck is broken.

In the first moments, however, of the dislocation, considerable motion remains, and the position is not so determinately fixed as it afterwards becomes; for I have seen a man brought into Guy's Hospital, who, but a few minutes before, had the thigh-bone dislocated into the foramen ovale, and I was surprised to find in a case otherwise so well marked, that a great mobility of the bone still existed at the dislocated part; but in less than three hours, it became firmly fixed in its new situation by the permanent, or, as it is called, *tonic* contraction of the muscles.

Length of limb altered.

In some dislocations the limb is rendered shorter, and thus the muscles influenced by it are immediately thrown into a state of relaxation; but if the limb be elongated, the tension of the principal muscles around the joint is extreme, and they are

sometimes stretched to laceration. Blood is often effused in considerable quantity around the joint, which renders detection of the accident difficult; the swelling being sometimes so considerable as to conceal entirely the ends of the bones. This effusion is in proportion to the size and number of the vessels lacerated. Effusion of blood.

A severe but obtuse pain arises from the pressure of the head of the bone upon the muscles, and, in some cases, this pain is rendered more acute from its pressure upon a large nerve. From this cause also is produced a paralysis of the parts below, instances of which occur in dislocations of the shoulder. In other cases, the bone presses upon important parts, so as to produce effects dangerous to life. I have for many years mentioned, in my lectures, a case of a dislocated clavicle, pressing upon the œsophagus so as to endanger life; which Mr. Davie, of Bungay, was so kind as to send me an account of. I shall give a more detailed history of this case hereafter. Effects of pressure from the dislocated bone.

In most dislocations, the head of the bone may be readily felt in its new situation; and the rotation of the limb best discovers the nature of the accident, as the head of the bone can be felt to roll. The natural prominences of the dislocated bone, in some instances, either disappear, or become less conspicuous, as the trochanter in luxations of the hip-joint; but the reverse of this happens in dislocations of the elbow, for there the olecranon is more than usually prominent, and serves as the principal guide for discovering the nature of the injury. Criterion of the accident by rotation.

The more remote effects of the accident are, that frequently a sensation of crepitus is produced by the effusion of adhesive matter Crepitus.

(fibrin) into the joint and bursæ; the synovia becomes inspissated, and crackles under motion, a circumstance of which every practitioner should be aware, as he may be otherwise induced erroneously to suspect the existence of fracture.

Inflammation and suppuration.

The degree of inflammation which succeeds to these accidents is generally slight; but in some cases it becomes so considerable as to produce a tumefaction, which, added to that resulting from extravasation of blood, frequently renders the detection of the injury exceedingly difficult. Sometimes, after the reduction of dislocations, suppuration ensues, and the patient falls a victim to excessive discharge and irritation. Mr. Howden, who was one of our most intelligent apprentices at Guy's Hospital, and was afterwards surgeon in the army, related the following case:— "A man had his thigh dislocated upwards and backwards on the ilium, which was soon after reduced; the next day a considerable swelling was observed on the part, which continued to increase, accompanied with rigours, and in four days the patient died. On dissection, the capsular ligaments, and ligamentum teres, were found entirely torn away, and a considerable quantity of pus extravasated in the surrounding parts." *See Minutes of the Physical Society, Guy's Hospital, November* 12, 1791.— I attended the master of a ship, who had dislocated his thigh upwards; an extension was made, apparently, with success; but in a few days a large abscess formed on the thigh, which destroyed the patient: fortunately, however, such a result is by no means common.

Stretching and laceration of muscles.

When, from length of time, or any other circumstance, the reduction of the limb is rendered impracticable, the bone forms for

itself a new bed, and some degree of motion is gradually recovered; although, in neglected dislocations of the lower extremity, the patient is ever after lame; and in those of the upper, the motion and power of the limb are very much diminished.

Appearances on dissection

On examination of the bodies of persons who die in consequence of dislocations arising from violence, the head of the bone is found completely removed from its socket. The capsular ligament is torn transversely to a great extent; the peculiar ligaments of joints, as the ligamentum teres of the hip, are torn through; but the tendon of the biceps, in dislocations of the os humeri, remains uninjured, as far as I have been able to ascertain by dissection; although I should be sorry to be understood to say that this is universally the case.

Ligaments.

Tendons.

The tendons which cover the ligaments are also torn; as the tendon of the sub-scapularis muscle, in the dislocation in the axilla; and according to the extent of this laceration, is the facility with which the accident recurs after reduction; a circumstance frequently very difficult to obviate.

Muscles.

The muscles also are influenced by the nature of the accident, being in some cases put upon the stretch, even to laceration; as the pectineus and abductor brevis, in dislocation of the thigh downward; and large quantities of blood become extravasated into the cellular membrane.

Dissections of old dislocations.

The appearance of joints which have long been dislocated, depends not only on the length of time that has elapsed from the accident, but also on the structure upon which the head of the dislocated bone is thrown; for if it be found embedded in muscle, its articular cartilage remains, and a new capsular ligament forms

Head of the bone embedded in muscle.

Formation of a new capsular ligament.

around it, which does not adhere to its cartilaginous surface. This ligament, in dislocations of the femur, contains within it the head of the bone, with the lacerated portion of the ligamentum teres united to it. (*See plate*) In these instances the bones themselves undergo little change. The capsular ligament is formed from the surrounding cellular tissue; which, being pressed upon by the head of the bone, becomes inflamed, thickened, and condensed. By this means a substance is produced somewhat less dense than original ligament, but still possessing sufficient firmness to bear considerable pressure, and to furnish some degree of support.

Manner of its formation.

Head of the bone resting on another bone.

But if the head of the dislocated bone be placed on the surface of another bone, or upon a thin muscle over it, that muscle becomes absorbed, and the bone undergoes a remarkable change; thus it is found, if the dislocation be not reduced, that both the ball and the bone which receives it are changed in their form. The pressure of the head of the bone produces absorption of the periosteum, and of the articular cartilaginous surface of the head of the bone; a smooth hollow surface is formed, and the ball becomes altered in its shape to adapt it to its new surface; and whilst this absorption proceeds upon the part on which the head of the bone rests, an ossific deposit takes place around it from the periosteum, which is there irritated but not absorbed. By the deposition of this bony matter between the periosteum and the original bone, a deep cup is formed to receive the head of the bone; and perhaps no instances can be adduced which more strongly mark the powers of nature in changing the form of parts to accommodate them to new circumstances, than these effects of dislocation. (*See plates 2, 3 and 4.*)

Formation of a new socket.

The new cup which is thus formed, sometimes so completely surrounds the neck of the bone, as to prevent its being removed from it without fracture *(see plate);* and the socket is smoothed upon its internal surface, so as to leave no projecting parts which can interrupt the motion of the bone in its new situation.

The muscles losing their action, become diminished in bulk, and reduced in their length, in proportion to the displacement of the bone towards their origin; and if the dislocation has been long unreduced, they lose their flexibility, and tear rather than yield to extension.

Dislocations from relaxation.

Although dislocations happening from violence are accompanied by laceration of the ligaments of the joint, yet they may occur from relaxation of the ligaments only, of which the following case is an example.

CASE.

Case.

A girl came to my house, who had the power of throwing her patellæ from the surfaces of the condyles of the os femoris. Her knees were bent considerably inwards; and when the rectus muscle acted upon the patella, it was drawn from the thigh-bone into a line with the tubercle of the tibia, and laid nearly flat upon the side of the external condyle of the femur. She came from the south of Europe, and said she had been brought up as a dancing girl from her earliest years, thus, gaining her daily bread, as we see children dancing upon elevated platforms in the streets of London; and

she imputed to these continued and early exertions the weakness under which she laboured.

Dislocation from accumulation of synovia.

A similar relaxation of ligaments, is also produced by an accumulation of synovia in joints. Mr. Shillito, surgeon at Hertford, requested me to see the servant of a gentleman in my neighbourhood, who had a great enlargement of the knee-joint from an inordinate secretion of synovia; and when this became absorbed, the ligaments remained so much relaxed, that the efforts of the muscles in walking dislocated the patella outwards. I ordered her into the hospital, that the students might observe this case, of which the following is an account.

CASE.

Dislocation from relaxation.

Ann Parish was admitted into Guy's Hospital in the autumn of 1810, for a dislocation of the left patella from relaxation of the ligaments. She had for four years previously a large accumulation of synovia in that knee, causing some pain, and much inconvenience in walking. Blisters had been applied without much effect, and other means tried, for four months before her admission. When the knee had acquired considerable size, the swelling spontaneously subsided, and she then first discovered that the patella became dislocated when she extended the limb. She suffered some pain whenever this happened, and she lost the power of the limb in walking, so that she fell when the patella slipped from its place, which it did whenever she attempted to walk without a bandage. The patella was placed upon the external condyle of the os femoris, when thrown from its natural situation, to which it did not return

without considerable pressure of the hand. In other respects her health was good. Straps of adhesive plaster were ordered to be applied, and a roller to be worn, which succeeded in preventing the dislocation so long as they were used, but the bone again slipped from its place whenever they were removed. A knee-cap, made to lace over the joint, was ordered for her.

Paralysis.

Dislocation sometimes arise from a loss of muscular power; for when the muscles are kept long and forciby extended, their tone becomes destroyed; or if, from a paralytic affection, they lose their action, a bone may be dislocated easily, but is as readily replaced: of the first of these two causes, the following case is an illustration.

CASE.

Mr. ———, a gentleman, now residing in the City, whilst in the East Indies, as a junior officer on board his ship, had been placed under the orders of one of the mates when the captain was on shore, and for some trifling offence this young gentleman was punished in the following manner:—His foot was placed upon a small projection on the deck, and his arm was lashed tightly towards the yard of the ship, and thus kept extended for an hour. When he returned to England, he had the power of readily throwing that arm from its socket, merely by raising it towards his head; but a very slight extension reduced it; the muscles were also wasted, as in a case of paralysis. A prosecution was commenced for this act of cruelty, and I was subpœnaed to give evidence; but the petty

tyrant chose to pay the forfeit of his misconduct prior to the commencement of the trial.

I have also seen in a dislocation of the thumb, the first phalanx capable of being thrown from the os metacarpi pollicis, merely by the action of the muscles, from a relaxed state of the ligament.

Of the influence of paralysis, the following case is an example:

CASE.

I was desired to see a young gentleman, who had one of those paralytic affections in his right side which frequently arise during dentition. The muscles of the shoulder were wasted; and he had the power of throwing his os humeri over the posterior edge of the glenoid cavity of the scapula, from whence it became easily reduced.

In these cases, particularly in the latter, no laceration of the ligaments could have occurred; and they shew the influence of the muscles in preventing dislocation from violence, and in impeding its reduction.

Dislocation from ulceration.

Dislocations arise from ulceration, by which the ligaments are detached, and the bones become altered in their form. We frequently find this state of parts in the hip-joint: the ligaments ulcerated, the edge of the acetabulum absorbed, the head of the thigh-bone changed both in its magnitude and figure, escaping from the acetabulum upon the ilium, and there forming for itself

a new socket. We have in the anatomical collection at St. Thomas's Hospital, a preparation of the knee dislocated by ulceration, anchylosed at right angles with the femur, and the tibia turned directly forwards. A boy, in Guy's Hospital, had his knee dislocated by ulceration, whose tibia was thrown on the inner side of the external condyle of the os femoris; and a girl, in the same hospital, had the knee dislocated by ulceration, the head of the tibia being placed behind the condyles of the os femoris.

Fracture and dislocation.

Dislocations are sometimes accompanied with fracture. At the ancle joint it rarely happens that dislocation occurs without a fracture of the fibula, and at the hip-joint the acetabulum is occasionally broken:—of this an example will be seen in the following

CASE.

Dislocation with organic lesion.

Thomas Steers was admitted into Guy's Hospital, on the 28th of October, 1805, with a dislocation of the os femoris into the ischiatic notch. The dislocation was reduced by a very slight extension, compared with that which is commonly required: this was imputed to the muscular relaxation caused by nausea, the patient having vomited at the time of his admission. But he soon complained of severe pain, extending over his abdomen, and he died on the day following his admission. Upon inspecting his body, the intestinum jejunum was found ruptured; and upon examination of the hip-joint, a portion of the edge of the acetabulum was discovered to be broken off.

Dislocations of the os humeri are also sometimes accompanied with fracture of the head of that bone, of which we have a specimen in the Museum at St. Thomas's Hospital. The coronoid process is sometimes broken in dislocations of the ulna, producing a species of luxation, which does not admit of the bone being afterwards preserved in its natural situation.

Dislocation and fracture.

When a bone is both broken and dislocated, it is proper to endeavour to reduce the dislocation without loss of time, taking care that the fractured part be strongly bandaged in splints, to prevent any injury to the muscles; for if this be not done at first, it cannot be afterwards effected without danger of re-producing the fracture.

If a compound fracture of the leg, and a dislocation of the shoulder, happen in an individual at the same time, the reduction of the arm should be immediately undertaken, after the fractured limb has been secured in splints. The Rev. Mr. H——, owing to his being thrown from his chaise, had a compound fracture of the leg, and a dislocation of the shoulder forwards. The dislocation was not at first observed, nor was its reduction attempted till a fortnight after the accident. The trial proved unsuccessful, as, from a dread of fever and of injury to the leg, sufficient extension could not be used.

The accidents which have been called dislocations of the spine, are generally fractures of the vertebræ, followed by displacement of the bones, but not of the intervertebral substance; and even the articulatory processes are broken, as well as the bodies of the vertebræ, so that they are not true dislocations of the spine, excepting those of the upper cervical vertebræ, dislocations of

which are said to have occasionally occurred. The injuries of the spine, which produce paralysis of the lower extremities, are fractures of the bodies of the vertebræ, pressing upon, and sometimes lacerating, the medulla spinalis.

In *compound dislocation*, not only the articulatory surfaces of the bone are displaced, but the cavity of the joint is laid open by a division of the skin and the capsular ligament. The immediate effect of compound dislocation is, to occasion the extravasation of blood into the joint, and to allow the escape of the synovia. Compound Dislocations

Compound dislocations are attended with great danger, and for the following reason: Danger.

When a joint is opened, inflammation of the lacerated ligaments and synovial surface speedily succeeds; in a few hours suppuration begins, and granulations arise from the surface of the secreting membrane; which, being of the mucous kind, is more disposed to the suppurative, than to the adhesive inflammation. But the same process does not immediately ensue upon the extremity of the bone, because it is covered by the articular cartilage. This cartilage, before the cavity fills with granulations, becomes absorbed, by an ulcerative process instituted on the end of the bones, but sometimes beginning from the synovial surface. The bone inflames, the cartilage becomes ulcerated, numerous abscesses are formed in different parts of the joint, and at length granulations spring from the extremities of the bones deprived of their cartilages, and fill up the cavity; generally these granulations become ossified, and anchylosis succeeds; but sometimes they remain of a softer texture, and some degree of motion in the joint is gradually regained.

This process of filling up joints requires great general, as well as local efforts; a high degree of irritation is produced; and if the constitution be weak, the patient, to preserve his life, is sometimes obliged to submit to amputation.

Injury to muscles, blood-vessels, &c.

In addition to the above circumstances, the violence necessarily inflicted on the parts, in compound dislocations, the injury which the muscles and tendons sustain, and the laceration of blood-vessels, necessarily lead to more important and dangerous consequences than those which follow simple dislocations.

Treatment.

With respect to the treatment of compound dislocations, it is not my intention, in this part of the work to describe it, but to reserve what I have to say on that subject for the description of compound dislocations of the ancle, where such observations will be required, and where they will be better understood; and thus a repetition, which would be both irksome and useless to the reader, will be avoided. I shall just remark, that some joints are more liable to compound dislocations than others. The hip-joint is scarcely ever so dislocated; of the shoulder I have known two instances; but the elbow, wrist, ancle, and fingers, are frequently the seats of this accident; and I have seen an instance of it at the knee.

Some joints more easily dislocated than others.

In consequence of their different formation, we find that in some joints, dislocation is much more frequent than in others. Those which have naturally extensive motions are easily luxated, and hence the dislocation of the os humeri occurs much more frequently than that of any other bone; and having once occurred, it happens again easily in the mere natural elevation of the arm. It is wisely ordained, that in those parts to which extensive motion is

assigned, and for which great strength is required, there is a multiplicity of joints. Thus, in the spine, in which great strength is necessary to protect the spinal marrow, numerous joints are formed, and the motion between any two bones is so small, that dislocations, except between the first and second vertebræ, rarely occur, although the bones are often displaced by fracture.

The carpus and the tarsus are constituted on a similar principle; they allow of considerable motion, yet maintain great strength of union. For if the motion between two bones, as in the spine, be multiplied by twenty-four, and that at the carpus by eight, the result will shew that great latitude of motion is given, and the strength of the part preserved; whilst, if the spine had been formed of a single joint, dislocations might have easily happened, and death from this cause might have been a frequent consequence.

Partial dislocations.

Dislocations are not always complete, since bones are sometimes but partially thrown from the articulatory surface on which they rested: this species of dislocation now and then occurs at the ancle-joint. An ancle was dissected at Guy's, by Mr. Tyrrell, and given to the collection of St. Thomas's, which was partially dislocated; the end of the tibia still rested in part upon the astragalus, but a larger portion of its surface on the os naviculare, and the tibia, altered by this change of place, had formed two new articulatory surfaces, with their faces turned in opposite directions towards the two tarsal bones. (*See plate.*) The dislocation had not been reduced. The knee-joint is, I believe, rarely dislocated laterally in any other way; for its extensive articular surfaces almost preclude the possibility of complete displacement.

Instance.

The os humeri sometimes rests upon the edge of the glenoid cavity, and readily returns into its socket; and the elbow-joint is dislocated partially, both in relation to the ulna and the radius.

The lower jaw is also sometimes partially dislocated, but in a different manner; one of the joints being luxated, and the other remaining in its place.

Cause.

Dislocations are generally occasioned by violence, and the force is usually applied whilst the bone is in an oblique direction to its socket; but it is necessary that the muscles should be in a great degree unprepared for resistance, otherwise the greatest force will hardly produce the effect: when they are unprepared, it will often ensue from very slight accidents. A fall, in walking, will sometimes dislocate the hip-joint, when the muscles have been prepared for a different exertion.

While dwelling on this subject in my lectures, I have usually adverted to the execution of Damien, as illustrative of this position.

Resistance of the muscles.

Damien was executed for the attempt to murder Lewis XV. Four young horses were fixed to his legs and arms, and were forced to make repeated efforts to tear his limbs from his body, but could not effect this purpose; and after fifty minutes, the executioners were obliged to cut the muscles and ligaments to effect his dismemberment.

The following is the French account of this execution:

"Il arriva à la place de Gréve à trois heures et un quart, regardant d'un œil sec et ferme le lieu, et les instrumens de son supplice. On lui brula d'abord la main droite; ensuite on le tenailla, et on versa sur ses plaies, de l'huile, du plomb fondu, et

de la poix-resine. On procéda ensuite a l'écartellement. Les quatre chevaux firent pendant cinquante minutes des efforts inutiles pour demembrer ce monstre. Au bout de ce tems là, Damien, etant encore plein de vie, les bourreaux lui couperent avec de bistouris, les chairs et les jointures nerveuses des cuisses, et des bras; ce qu'on avoit été obligé de faire en 1610 pour Ravaillac. Il respiroit encore aprés que les cuisses furent coupées, et il ne rendit l'ame que pendant qu'on lui coupoit les bras. Son supplice depuis l'instant qu'il fut mis sur l'echafaud, jusqu' au moment de sa mort, dura près d'une heure et demie. Il conserva toute sa connoissance, et releva sa tête sept ou huit fois, pour regarder les chevaux, et ses membres ténaillés et brulés. Au milieu des tourmens les plus affreux de la question il avoit laissé echapper des plaisanteries.—*Dictionnaire Historique.*"

Old persons are much less liable to dislocations than those of middle life, because the extremities of bones in advanced age are often so soft as to break under the force applied, rather than quit their natural situations. Persons of lax fibre are prone to dislocation, because their ligaments easily tear, and their muscles possess little power of resistance. From these circumstances old people would be exposed to frequent dislocations, but for the softened state of the extremities of their bones.

Dislocations rare in old persons.

Young persons are also very rarely the subjects of dislocations from violence; but now and then such accidents do occur; of which I have described an instance in a child at seven years of age. It generally happens that their bones break, or their epiphyses give way, rather than that the parts displace. I read of dislocations of the hip in children, but their history is that of

Dislocations rare in the young.

diseases of the hip-joint, in which the dislocation arises from ulceration. A child was brought to me from one of the counties north of London, who had repeated extensions made by one of those people called *bone-setters*,—but who ought rather to be called *dislocators*,—for a supposed dislocation of the hip-joint. Upon examination, I found the case to be that disease of the hip which is so common in children; and for this only, was a child wantonly exposed to a most painful extension. That in this enlightened country, men, without education, should be suffered with impunity to degrade a most useful profession, and put to the torture those who have the folly to apply to them, is a disgrace to our laws, that calls loudly for prevention.

Elbow-joint dislocations.

Dislocations of the elbow-joint in children are said to be of frequent occurrence. Surgeons have been heard to say, "I have a child under my care with luxation of its elbow, and I can easily return the bone into its place, but it directly dislocates again." Such a case is, in reality, an oblique fracture of the condyles of the os humeri, which produces the appearance of dislocation, by allowing the radius and ulna, or the ulna alone, to be drawn back with the fractured condyle, so as to produce considerable projection at the posterior part of the joint.

TREATMENT.

Reduction.

The reduction of dislocations is often difficult; and in some of the joints, the form of the bone may occasion impediments. Thus, when the socket is surrounded by a lip of bone, as in the hip-joint, the head of the bone, during the act of reduction, stops at this projection, and requires to be lifted over it; another difficulty

Difficulty in bone.

occurs when the head of the bone is much larger than its cervix, as for example, in the dislocation of the head of the radius; but still these causes are slight in comparison with others which we have to detail.

The capsular ligaments are supposed to resist reduction; but those who entertain that opinion must forget their inelastic structure, and cannot have had opportunities of witnessing, by dissection, the extensive laceration which they sustain in dislocations from violence. The capsular ligaments, in truth, possess but little strength either to prevent dislocation, or to resist the means of reduction; and if the tendons with which they are covered, and the peculiar ligaments of the joints did not exist, dislocation must be of very frequent occurrence. The capsular ligaments.

The joint of the shoulder, and those of the knee and elbow, are strongly protected by tendons; the shoulder by those of the spinati, sub-scapularis, and teres minor muscles; the elbow by the triceps and brachialis; the knee by the tendinous expansion of the vasti; but still some ligaments resist dislocations; these, however, are the peculiar, not the capsular ligaments. The wrist and the elbow have their appropriate lateral ligaments to give additional strength to these joints. The shoulder, instead of a peculiar ligament, has the tendon of the biceps received into it, which lessens the tendency to dislocation forwards; the ligamentum teres of the hip-joint prevents a ready dislocation downwards; the knee has its lateral and crucial ligaments; and the ancle, exposed as it is to the most severe injuries, is provided with its deltoid and fibular tarsal ligaments, of very extraordinary strength, to prevent dislocation. The bones of this joint often break rather than their Tendons. Peculiar ligaments.

ligaments give way; however, in many of the joints, as these ligaments are torn, they afford no resistance to the reduction of dislocations, as in the hip, elbow, and wrist; but if one of them remain, it produces difficulty in the reduction, as I have seen in the knee-joint.

Muscles.

The difficulty in reducing dislocations arises principally from the resistance which the muscles present by their contraction, and which is proportioned to the length of time which has elapsed from the injury; it is therefore desirable that the attempt at reduction should not be long delayed.

The common actions of the muscles are voluntary or involuntary, but they have a power of contraction independent of either state.

Fatigue of muscles.

A muscle, when excited to action by volition, soon becomes fatigued, and requires rest. The arm can be extended only for a few minutes, at right angles with the body, before it feels a fatigue which requires suspension of action; and, indeed, the same law governs involuntary action, as the heart has its contraction and relaxation.

Permanent contraction.

But when a muscle is divided, its parts contract; or when the antagonist muscle is cut, the undivided muscle draws the parts into which it is inserted, into a fixed situation. Thus, if the biceps muscle be divided, the triceps keeps the arm constantly extended; if the muscles on one side of the face are paralytic, the opposing muscles draw the face to their side. This contraction is not succeeded by fatigue or relaxation, but will continue an indefinite time, even until the structure of the muscle becomes changed; and its contraction increases from the first occurrence

of the accident. Thus it is, that when a bone is dislocated, the muscles draw it as far from the joint as the surrounding parts will allow, and there by their contraction they fix it. It is this resistance from muscles, aided by their voluntary contraction, which the surgeon is required to counteract. If an extension be made almost immediately after a dislocation has happened, the resistance produced by the muscles is easily overcome: but if the operation be postponed for a few days only, the utmost difficulty occurs in effecting it.

Vis tonica of muscles.

Mr. Forster, son of the surgeon of Guy's Hospital, informed me, that in a fatal case of fracture of the thigh-bone, which he had an opportunity of dissecting before its union, the ends of the bones overlapped, and the muscles had acquired a contraction so rigid, that he could not, even in the dead body, bring the bones to their natural position, after employing all the force he was capable of exerting; and it is this state of muscles in dislocations, which gives rise to the difficulty in their reduction; and which, even in the dead body, is still capable of opposing a very considerable resistance.

That the muscles are the chief cause of resistance, is strongly evinced by those cases in which the dislocation is accompanied by injury to any vital organ, and when the power of muscular action is diminished; for it is then found, that a very slight force is sufficient to return the bone to its situation. Thus, in the case already mentioned, of the man who had an injury to his jejunum, and a dislocation of his hip, the bone was restored to its place with little difficulty.

Other difficulties.

When a dislocation has long existed, difficulties arise from

three other circumstances. The extremity of the bone contracts adhesion to the surrounding parts, so that even when in dissection the muscles are removed, the bone cannot be reduced. In this state I found the head of a radius, which had been long dislocated upon the external condyle of the os humeri, and which is preserved in the collection at St. Thomas's Hospital *(see plate);* and in a similar state I have seen the os humeri when dislocated. The socket is also sometimes so filled with adhesive matter, that if the bone was reduced, it could not remain in its original situation, and the original cavity is in part filled with ossific matter, so as to render it incapable of receiving the head of the bone. Lastly: a new bony socket is sometimes formed, in which the head of the bone is so completely confined, that nothing but its fracture will allow it to escape from its new situation. (*See plate.*)

Means of reduction.

The means to be employed for the reduction of dislocations, are both constitutional and mechanical; it is generally wrong to employ force only, since it would be required in so great a degree as to occasion violence and injury; and it will in the sequel be shewn, that the most powerful mechanical means fail when unaided by constitutional remedies. The power and direction of the larger muscles are, in the first instance, to be duly appreciated, as these form the principal causes of resistance.

Constitutional.

The constitutional means to be employed for the purpose of reduction are those which produce a tendency to syncope, and this necessary state may be best induced by one or other of the following means, viz.: bleeding, warm bath, and nausea. Of these remedies, I consider bleeding the most powerful; and, that the effect may be produced as quickly as possible, the blood

should be drawn from a large orifice, and the patient kept in the erect position, for by this mode of depletion, syncope is produced before too large a quantity of blood is lost. However, the activity of this practice must be regulated by the constitution of the patient; if he be young, athletic, and muscular, the quantity removed should be considerable, and the method of taking it away should be that which I have described.

Secondly; in those cases in which the warm bath may be thought preferable, or where it may be considered improper to continue the bleeding, the bath should be employed at the temperature of 100° to 110°; and, as the object is the same as in bleeding, the person should be kept in the bath at the same heat till the fainting effect is produced, when he should be immediately placed in a chair, wrapped in a blanket, and the mechanical means employed which I shall hereafter particularly describe.

Of late years, I have practised a third mode of lowering the action of the muscles, by exhibiting nauseating doses of tartarized antimony; but as its action is uncertain, frequently producing vomiting, which is unnecessary, I rather recommend its application merely to keep up the state of syncope already produced by the two preceding means; which its nauseating effects will most readily do, and so powerfully overcome the tone of the muscles, that dislocations may be reduced with much less effort, and at a much more distant period from the accident, than can be effected in any other way.

The two cases related in the following pages, one from Mr. Norwood, surgeon, at Hertford, and the other from Mr. Thomas, apothecary to St. Luke's Hospital, will illustrate the efficacy of

the treatment recommended. By the combination of bleeding, the warm bath, and nauseating doses of tartarized antimony, two dislocations were reduced at a more distant period from the accident than I have ever known in any other example. One of these cases occurred at Guy's, and the other at St. Thomas's Hospital, at the time when these gentlemen were officiating as dressers. *(See cases of dislocation on the ilium.)*

Opium. The effect of opium I have never tried, but it would probably be useful in a large dose, from its power of diminishing muscular and nervous influence.

Mechanical means. The reduction of the bone is to be attempted, after lessening the powers of the muscles, by fixing one bone, and drawing the other towards its socket. It is now generally agreed among the

Force gradual. most eminent surgeons, that force should be only gradually applied; for violence is as likely to tear sound parts, as to reduce those which are luxated; and it is apt to excite all the powers of resistance to oppose the efforts of the surgeon. But it is his duty to produce, gradually, that state of fatigue and relaxation which is sure to follow continued extension, and not to attempt at once to overpower the action of the muscles.

One great cause of failure in the attempt to reduce dislocations, arises from insufficient attention to fixing that bone in which the socket is placed. As for example: in attempting to reduce a dislocation of the shoulder, if the scapula be not fixed, or one person pull at the scapula and two at the arm, the scapula will be necessarily drawn with the os humeri, and the extension will be very imperfectly made; the one bone, therefore, must be firmly fixed, or drawn in the opposite direction, whilst the other is extended.

The force required, may be applied either by the exertion of assistants, or by a compound pulley; but the object is to extend the muscles by gradual, regular, and continued efforts; the pulley, in cases of difficulty, should always be resorted to; its effect may be gentle, continued, and directed by the surgeon's mind; but when assistants are employed, their exertions are sudden, violent, and often ill-directed; and the force is more likely to produce laceration of parts, than to restore the bone to its situation. Their efforts are also frequently uncombined, and their muscles as necessarily fatigue, as those of the patient, whose resistance they are employed to overcome. Compound pulley.

In dislocation of the hip-joint, pullies should always be employed; and in those dislocations of the shoulder which have long remained unreduced, they should also be resorted to. I do not mean to doubt the possibility of reducing dislocations of the hip by the aid of men only, but to point out the inferiority of this mode to the pullies. The employment of pullies in dislocations, is not a modern practice; Ambrose Paré was in the habit of employing pullies, and good practical surgeons have used them since his time;—and most writers on surgery have mentioned their use, but they have not duly appreciated them. Mr. Cline, whose professional judgment every one must acknowledge, always strongly recommended them.

During the attempt to reduce luxations, the surgeon should endeavour to obtain a relaxation of the stronger opposing muscles. The limb should therefore be kept in a position between flexion and extension, as far as it can be obtained. Who has not seen, in the attempt to reduce a compound fracture in the extended Relaxation of the stronger muscles.

position of a limb, the bone, which could not be brought into apposition under the most violent efforts, quickly replaced by an intelligent surgeon, who has directed the limb to be bent, and the muscles to be placed in a comparative state of relaxation?

Whether the extension should be applied to the dislocated bone.

A difference of opinion prevails, whether it is best to apply the extension on the dislocated bone, or on the limb below. M. Boyer, who has long taken the lead in surgery in Paris, prefers the latter mode. As far as I have had an opportunity of observing, it is generally best to apply the extension to the bone which is dislocated. There are, however, exceptions to this rule in the dislocation of the shoulder, which I generally reduce by placing the heel in the axilla, and by drawing the arm at the wrist in a line with the side of the body.

Influence of the mind.

In the reduction of dislocations, great advantage is derived from attending to the patient's mind; the muscles opposing the efforts of the surgeon, by acting in obedience to the will, may have that action suspended, by directing the mind to other muscles. Several years since, a surgeon in Blackfriars' Road, asked me to see a patient of his with a dislocated shoulder, which had resisted the various attempts he had made at reduction. I found the patient in bed, with his right arm dislocated; I sat down on the bed by his side, placed my heel in the axilla, and drew the arm at the wrist; the dislocated bone remained unmoved. I said, "Rise from your bed, Sir;" he made an effort to do so, whilst I continued my extension, and the bone snapped into its socket; for a similar reason, a slight effort, when the muscles are unprepared, will succeed in the reduction of dislocation, after violent measures have failed.

The reduction of the limb is known to have been effected by the restoration of its natural form, the recovery of its original motion, and by a snap, which is heard when the bone returns into its articulatory cavity.

When a bone has been reduced by the pullies, it will not remain in its situation without the aid of bandages to support it till muscular action returns. In the hip, however, dislocation rarely occurs a second time, but the shoulder and the lower jaw very frequently slip again from their sockets, owing to the little depth of the cavity into which the head of the bone is received; and, therefore, they require bandages for a considerable period subsequent to reduction.

Second dislocation.

Rest is necessary for some time after the reduction of the limb, in order to produce an union of the ruptured ligament, which would be prevented by exercise. The strength of the muscles and ligaments may also be greatly promoted by pouring cold water upon the limb, and by the subsequent employment of friction.

Rest of the limb.

I believe that much mischief is produced by attempts to reduce dislocations of long standing in very muscular persons. I have seen great contusion of the integuments, laceration and bruises of muscles, tension of nerves, leading to an insensibility and paralysis of the hand, occasioned by an abortive attempt to reduce a dislocation of the shoulder; so that the patient's condition has been rendered much worse than before. In such cases, even when the bone is replaced, it is often rather an evil than a good, from the violence of the extension.

Old dislocations not to be reduced.

In those instances, in which the bone remains in the axilla, in dislocations of the shoulder, a serviceable limb, and very

extensive motions of it may be regained, although reduction has not been effected. Captain S———, who dislocated his shoulder four years ago, called to shew me how much motion he had recovered, although the arm still remained unreduced.

Time for attempting reduction.

I am of opinion, that three months after the accident for the shoulder, and eight weeks for the hip, may be fixed as the period at which it would be imprudent to make the attempt at reduction, except in persons of extremely relaxed fibre, or of advanced age. At the same time, I am fully aware, that the shoulder has been reduced at a more distant period than that which I have mentioned, but, in most instances, with the results I have just been deprecating.

In cases of unreduced dislocation, the only course which the surgeon can adopt, after the inflammation which the injury produces has subsided, is, to advise motion of the limb, and friction of the injured part:—The former, to produce a new cavity for the head of the bone, to assist in forming a new ligament, and in restoring action to muscles, which would otherwise lose it by repose;—the latter, to promote absorption, and remove the swelling and adhesions which the accident has produced.

PARTICULAR DISLOCATIONS.

DISLOCATIONS OF THE HIP-JOINT.

Anatomy of the joint.

The acetabulum of the hip-joint is deepened by a cartilaginous ridge, which surrounds its brim; and although in the skeleton it is not a complete cup, yet it is rendered such in the living subject, by an additional portion of cartilage, which fills up a depression in the bone in the inferior and anterior part of the cavity.

Ligaments.

The ligaments are two: the capsular arises from the edge of the acetabulum, and passing over the head and neck of the bone, is inserted into the cervix of the os femoris at the root of the trochanter major. It is much more extensive upon the anterior than on the posterior portion of the neck of the bone. The inner side of this ligament is a secreting surface, producing the synovia; and a reflected portion of it towards the head of the bone is also provided with a similar secreting surface.

On the anterior surface of the neck of the thigh-bone, the capsular ligament is received into a line, which extends from the

trochanter major to the trochanter minor. The synovial secreting surface is reflected towards the head of the bone, and the ligament is reflected close on the neck of the bone, to form the periosteum; whilst its fibres are blended in with the common periosteum, below the insertion of the ligament, into the bone.

On the posterior surface the capsular ligament is received upon the neck of the bone, nearly midway between the edge of the head of the bone and the trochanter major. The common periosteum on the neck of the bone blends in with the reflected ligament, to form the periosteum of the neck of the bone within the capsule.*

The ligamentum teres is contained within the capsular ligament, and proceeds from a depression in the lower and inner part of the acetabulum, to be fixed in a hollow upon the inner side of the thigh-bone: it has a tendency to prevent dislocations in all directions, but particularly the dislocation downwards; for when this dislocation occurs, the thighs are widely separated from each other, as in fencing; and the head of the thigh-bone would be in danger of slipping from its socket, but that this ligament prevents it;—an example of its use, which shews the principal reason of its formation.

Mode of dislocation.

The thigh-bone I have seen dislocated in four directions:—First, upwards, or upon the dorsum of the ilium. Secondly, downwards, or into the foramen ovale. Thirdly, backwards,

---

* *Query*:—Can this ligamentous periosteum be one cause of a ligamentous union in fractures within the joints? I believe that when an union of the neck of the thigh-bone is met with, it will be in a case in which this ligamentous sheath of the cervix is not torn. *(See plate XIII fig. 3.)*

and upwards, or into the ischiatic notch; and, Fourthly, forwards, and upwards, or upon the body of the pubes. A dislocation downwards and backwards, has been described by some surgeons, who have had opportunities for observation; but I have to remark, that no dislocation of that description has occurred at St. Thomas's or Guy's Hospital, within the last thirty years, or in my private practice; and although I would not deny the possibility of its occurrence, yet I am disposed to believe that some mistake has arisen upon this subject.

DISLOCATION UPWARDS, OR ON THE DORSUM ILII.

Dislocation on the dorsum ilii.

This dislocation is the most frequent of those which happen to the hip-joint; and the following are the signs of its existence:

Symptoms.

The dislocated limb, is from one inch and a half, to two inches and a half shorter than the other, as is well seen by comparing the malleoli interni, when the foot is bent at right angles with the leg. The toe rests upon the tarsus of the other foot; the knee and foot are turned inwards, and the knee is a little advanced upon the other. When the attempt is made to separate the leg from the other, it cannot be accomplished, for the limb is fimly fixed in its new situation, so far as regards its motion outwards; but the thigh can be slightly bent across the other. If the bone be not concealed by extravasation of blood, the head of the thigh-bone can be perceived during rotation of the knee inwards, moving upon the dorsum ilii; and the trochanter major advances towards its anterior and superior spinous process, so as

to be felt much nearer to it than usual. The trochanter is less prominent than on the opposite side, for the neck of the bone and the trochanter rest in the line of the surface of the dorsum ilii; and upon a comparison of the two hips, the roundness of the dislocated side will be found to have disappeared. A surgeon, then, called to a severe and recent injury of the hip-joint, looks for a difference in length, change of position inwards, diminution of motion, and decreased projection of the trochanter.

Distinction from fracture of the neck of the femur.

The accident with which the dislocation upwards is liable to be confounded, is the fracture of the neck of the thigh-bone within the capsular ligament. Yet the marks of distinction are, in general, sufficiently strong to prevent an error in a person commonly attentive. In a fracture of the neck of the thigh-bone, the knee and foot are generally turned outwards; the trochanter is drawn upwards and backwards, resting upon the dorsum ilii; the thigh can be readily bent towards the abdomen, although with some pain; but, above all, the limb, which is shortened according to the duration of the accident, from one to two inches, by the contraction of the muscles, can be made of the length of the other by a slight extension; and when the extension is abandoned, the leg is again shortened. If, when drawn down, the limb is rotated, a crepitus can often be felt, which ceases to be perceived, when rotation is performed under a shortened state of the limb. Fracture of the neck of the thigh-bone, within the capsular ligament, rarely occurs but in advanced age, and it is the effect of the most trifling accident, owing to the interstitial absorption which this part of the bone undergoes at advanced periods of life. Fractures externally to the capsular ligament, occur at any age, and they

are easily distinguished by the crepitus which attends them, if the limb be rotated and the trochanter compressed with the hand. The position is the same as in fractures within the ligament. Fractures of the neck of the thigh-bone are very frequent accidents when compared with dislocations. *(See the plate of the positions of the limb in dislocations.)*

Diseases of the hip-joint

Diseases of the hip-joint can scarcely ever be confounded with dislocations from violence, but by those who are ignorant of anatomy, and who are very superficial observers. The gradual progress of the symptoms, the pain in the knee, with the apparent elongation at first, and real shortening afterwards; the capacity for motion, yet the pain given under extremes of rotation, as well as of flexion and extension, are marks of difference which would strike the most careless observer. The consequences of a disease of this kind, when it has existed a great length of time, are, ulceration of the ligaments, acetabulum, and head of the bone, which allow of such a change of situation of parts, as sometimes to give to the limb the position of dislocation; but the history of the case at once informs the medical attendant of the nature of the disease.

Cause.

This dislocation may be caused by a fall when the knee and foot of the patient are turned inwards, or by a blow whilst the limb is in that position; and the head of the bone is thus displaced upwards, and turned backwards.

In the reduction of this dislocation, the following plan is to be adopted:—take from the patient from twelve to twenty ounces of blood, or even more, if he be a very strong man; and then place him in a warm bath, at the heat of 100°, and gradually

increase it to 110°, until he feels faint. During the time he is in the warm bath, give him a grain of tartarized antimony every ten minutes until he feels some nausea; then remove him from the bath and put him in blankets: he is then to be placed between two strong posts about ten feet asunder, in which two staples are fixed; or rings may be screwed into the floor, and the patient be laid upon it. My usual method is, to place him on a table covered with a thick blanket, upon his back; then a strong girt is passed between his pudendum and thigh, and this is fixed to one of the staples. *(See plate.)* A wetted linen roller is tightly applied just above the knee, and upon this a leather strap is buckled, having two straps with rings at right angles with the circular part. The knee is to be slightly bent, but not quite at a right angle, and brought across the other thigh a little above the knee of that limb. The pullies are fixed in the other staple, and in the straps above the knee. The patient being thus adjusted, the surgeon slightly draws the string of the pulley, and when he sees that every part of the bandage is upon the stretch, and the patient begins to complain, he waits a little to give the muscles time to fatigue; he then draws again, and when the patient suffers much, again rests, until the muscles yield. Thus he gradually proceeds until he finds the head of the bone approach the acetabulum. When it reaches the lip of that cavity, he gives the pulley to an assistant, and desires him to preserve the same state of extension, and the surgeon then rotates the knee and foot gently, but not with a violence to excite opposition in the muscles, and in this act the bone slips into its place. In general, it does not return with a snap into its socket

when the pullies are employed, because the muscles are so much relaxed, that they have not sufficient tone remaining to permit them to act with violence, and the surgeon ascertaining the reduction only by loosening the bandages, and comparing the length of the limbs.

It often happens that the bandages get loose before the extension is completed, an accident which should be guarded against as much as possible, by having them well secured at first; but if they require to be renewed, this should be expeditiously performed, to prevent the muscles having time to recover their tone.

It is sometimes necessary to lift the bone, by placing the arm under it, near the joint, when there is difficulty in bringing it over the lip of the acetabulum; or a napkin may be passed under it as near the head of the bone as possible, and by its means an assistant may raise it. After the reduction, in consequence of the relaxed state of the muscles, great care is required in removing the patient to his bed.

I have seen a reduction of the bone effected, even where the extension was not made in the best possible direction; for when the muscles have not had time to settle, they will allow the bone to be restored into its socket, even when extension is made in a direction not the most favourable for its reduction. I cannot by any means subscribe to the method adopted by the late Mr. Hey, although no person feels greater respect for his talents, more highly appreciates his acquirements, or is more disposed to pursue the study of the profession in the mode which he so successfully adopted. The direction which he gave to a limb, in the case which he has represented of this accident, was one little calculated

to succeed, where the means were not used immediately after the injury had been sustained. But I state this with great deference, because I am not sure, that in all respects, I understand the description of the method which he adopted; nor do I think that I should be able, from that description, to be certain that I was pursuing the means by which he succeeded.

I may here observe, and I trust without ostentation, that the plans which I have recommended, are the result of considerable experience; that they have been successful in a great number of cases; and that they have very rarely failed, under the most disadvantageous circumstances: they may require a little variation, from some slight difference in the position, but this will only be an exception to a general rule, and will very rarely occur.

The following cases will serve as illustrations of the history and treatment of dislocations on the dorsum ilii: the first of them points out in a striking manner the evils that ensue when dislocation of the hip-joint remains unreduced, and the advantages arising from the use of pullies in effecting its reduction. It shews also that such dislocation may happen in a strong healthy man, even after he has attained the age of sixty.

Cases of Dislocation on the Dorsum Ilii.

CASE I.

James Ivory, aged sixty-two, of Pottensend, Herts, on the 7th of Feb. 1810, was working in a clay-pit about twenty-five feet below the surface of the earth, when a large quantity of clay fell

in upon him, while he was in the act of stooping with his left knee bent rather behind the other; and he was in this position buried under the earth. Being soon removed from his perilous situation, and carried home, a surgeon was sent for, who, discovering the accident to be a dislocation, directly employed some men to extend the limb, whilst he attempted to push the head of the bone into the acetabulum; but all his efforts were unavailing, as, unfortunately for the patient, pullies were not employed. The appearances of the limb at present, when nine years have elapsed since the accident, are these: the limb is three inches and a half shorter than the other, and the patient is obliged to wear a shoe having an additional sole of three inches on that side, which lessens, though it does not prevent, his halt in walking. When he stands, the foot of the injured limb rests upon the other; the toes are turned inwards, and the knee, which is advanced upon the other, is also inverted, and rests upon the side of the patella of the sound limb, and upon the vastus internus muscle; it is also bent, and cannot be completely extended. The thigh, from the unemployed state of several of the muscles, is very much wasted; but the semi-tendinosus, semi-membranosus, and biceps, owing to the shortened state of the limb, form a considerable rounded projection on the back part of the thigh. The trochanter major is seven eighths of an inch nearer to the spine of the ilium of the injured side than of the other. On viewing him behind, the trochanter major is seen projecting on the injured side much farther than on the other; the situation of the head of the bone on the dorsum ilii, is easily perceived; and when the limb is rotated

inwards, it is still more obvious. The spinous processes of the ilia are of an equal height. In the sitting posture, the foot is turned very much inwards, and the knee is placed behind the other, whilst the toe only reaches the ground. If fatigued, he experiences pain in the opposite hip, and in the thigh of the injured limb. This unfortunate man has an arduous task to gain his bread by his labour, as he cannot stoop but with the greatest difficulty, and is therefore obliged to seek those employments which least require that position. When he attempts to take any thing from the ground, he bends the knee of the injured limb at right angles with the thigh, and throws it far back. He can now stand for a few seconds upon the dislocated limb, but it was twelve months before he could do so. When in bed, it is painful to him to lie on the injured side. His hip, without any apparent cause, is much weaker at some times than at others. When sitting down to evacuate his fæces, he is obliged to support himself by resting the injured knee against the tendo Achillis of the other leg, placing his right hand on the ground. He now walks with two sticks; at first he employed crutches, and these he used for twelve months, after which, he was enabled to trust to one crutch and a stick, until his limb acquired greater strength. In getting over a stile, he raises the injured limb two steps, and then turns over the sound limb; but this he cannot accomplish when the steps are far apart; and he is frequently obliged either to turn back, or to take a circuitous route. When lying with his face downwards, the dislocated hip projects very much. He sometimes falls in walking, and would very frequently do so, but that he

takes extreme care,' as the least check to his motion throws him down. The knee is bent, and the shortening of the limb partly depends upon that circumstance.

The following cases illustrate the method of reduction detailed in the preceding pages, and shew in strong colours, the advantages to be derived from constitutional treatment, and the use of pullies.

CASE II.

John Forster, aged twenty-two years, was admitted into the Chester Infirmary, July 10th, 1818, with a dislocation of the thigh on the dorsum ilii, occasioned by a cart passing over the pelvis. Upon examination, I found the leg shorter than the other, and the knee and foot turned inwards. The patient being firmly confined upon a table, I extended the limb by pullies, for fifty minutes without success, and he was returned to bed for three hours; after which he was put in the warm bath for twenty minutes, and the extension was repeated for fifteen minutes unsuccessfully; I therefore took twenty-four ounces of blood from him, and gave him forty drops of tinct. opii. Continuing the extension, but not succeeding in producing faintness, I gave small doses of a solution of tartrate of antimony, which, in a quarter of an hour, produced nausea; in ten minutes afterwards, I succeeded in reducing the limb, and in less than a fortnight he left the Infirmary quite well. Unfortunately, he began to work hard immediately, and brought on an inflammation of the hip, of which he has not recovered.

Chester. S. R. Bennett.

CASE III.

Sir,

I beg leave to forward to you the particulars of the following case :—

John Lee, aged thirty-three, of a strong and robust constitution, in passing over a foot-bridge, October 9th, 1819, fell from a height of about four feet on a large stone, and dislocated his left hip. I did not see him until the 4th of December, when I found the limb full three inches shorter than the other, the knee turned in, the foot directed over the opposite tarsus, and the trochanter major brought nearer the spinous process of the ilium. On laying the man on his face, the head of the femur and trochanter could be distinctly seen on the dorsum ilii, so as to leave not the slightest doubt of the nature of the injury. With the assistance of a neighbouring practitioner, I immediately set about to reduce it; a girt was applied between the legs, and a bandage over the knee, to fix the pullies, &c., in the usual manner. I then made the extension downwards and inwards, crossing the opposite thigh two thirds downwards; and immediately when the extension was commenced, I gave him a solution of two grains of tartar emetic, which was repeated five times every ten minutes, but it produced very slight nausea. I shortly after bled him to sixty ounces without syncope; and after keeping up the extension gradually for about two hours, with all the force one man could employ with the pullies, we found the limb as long as the opposite; we then endeavoured to lift the head of the bone over the acetabulum, by means of a towel under the thigh and over one of our heads, at the same

time rotating the limb outwards with all the force we were able to exert; the foot at length became somewhat turned out, and the head of the bone to be less distinctly felt, and in about half an hour we heard a grating of the head of the bone, when the man instantly exclaimed it was replaced;* and, upon examination, finding the foot turned out, the limb of its natural length, and no appearance of the head of the bone on the dorsum ilii, we concluded it must be within the acetabulum, and desisted from any further violence, put the man to bed, and tied his legs together; his foot immediately became sensible, which it had not been before since the accident, and he altogether felt easier. A large blister was applied over the trochanter, and he slept well in the night, and complained of pain only in the perineum and just above the knee, where the bandages had been applied; there was no subsequent fever, nor any unpleasant symptom whatever.

In a few days the man could bear slight flexion and extension without pain, and in a week some degree of rotation; the limb became gradually stronger, and the power of motion so increased, that on the twelfth day he could by himself bring the thigh at right angles with the body. He was now taken out of bed, and bandages were applied round the thigh and pelvis, and he could stand perfectly upright, so as to walk with his heel on the ground with the assistance of crutches: and, from exercise, he grew so rapidly stronger, that on the twenty-second day he left off one crutch, and on the twenty-fifth the other. In a month he was able

* In dislocations which have remained long unreduced, the bone does not usually snap into its socket at its reduction.—A. C.

to walk without a stick; and in five weeks, having particular business, he walked nearly twenty miles, perfectly upright, and without the least limping.

I am, my dear Sir,

Collumpton, Devon. Your's very truly,

Jan. 27, 1820. S. Nott.

The following case forms a striking contrast to the preceding, and to some of those hereafter related.

CASE IV.

I was desired to visit a man aged twenty-eight years, who, by the overturning of a coach, had dislocated his left hip more than five weeks before; and who had been declared not to have a dislocation, although the case was extremely well marked. His leg was full two inches shorter than the other; his knee and foot were turned inwards; and the inner side of the foot rested upon the metatarsal bones of the other leg. The thigh was slightly bent towards the abdomen, and the knee was advanced over the other thigh. The head of the thigh-bone could be distinctly felt upon the dorsum of the ilium; and when the two hips were compared, the natural roundness of the dislocated side had disappeared. I used only mechanical means in my attempts at reduction, and although I employed the pullies, and varied the direction of repeated extensions, I could not succeed in replacing the bone, and this person returned to the country with the dislocation unreduced.

The following case was communicated by Mr. Norwood, surgeon, Hertford.

CASE V.

William Newman, a strong muscular man, nearly thirty years of age, was admitted into Guy's Hospital, on Wednesday, December 4th, 1812, under the care of Mr. Astley Cooper, for a dislocation of the hip-joint. In springing from the shafts of a waggon, on Thursday, November 7th, his foot slipped, and his hip was driven against the wheel with considerable force. He immediately fell, and being found unable to walk, was carried to Kingston Workhouse, which was near the place where the accident happened. On the evening of that day, he was examined by a medical man, but the nature of the accident was not ascertained. He remained at Kingston until the 30th of November, and was then removed to Guildford, his place of residence, and from thence, on the 4th of December, to Guy's Hospital. On examination, the head of the thigh-bone was found resting on the dorsum ilii; the trochanter was thrown forward towards the anterior superior spinous process of the ilium. The knee and foot were turned inwards, and the limb shortened one inch and a half; the great toe rested upon the metatarsal bone of the other foot, and there was but little motion in the limb.

On Saturday, the 7th of December, being thirty days after the accident, an extension was made to reduce the limb; and previously to the application of the bandage, he was bled to twenty-four ounces from his arm; in about ten minutes after this he was put into a warm bath, where he remained until he became faint, which

happened in fifteen minutes; he then had a grain of tartarized antimony given him, which was repeated in sixteen minutes, as the first dose did not produce nausea. The most distressing nausea was now quickly produced, but he did not vomit; and while under the influence of this debilitating cause, he was carried into the operating theatre in a state of great exhaustion. Being placed on a table on his left side, the bandage was applied in the usual manner to fix the pelvis, and the pullies were fastened to a strap around the knee; the thigh was drawn obliquely across the other, not quite two thirds of its length downwards, and the extension was continued for ten minutes, when the bone slipped into its socket. The man was discharged from the hospital in three weeks from the period of his admission, making rapid progress towards a recovery of the perfect use and strength of the limb.

For the history of the following case, I am obliged to Mr. Thomas, apothecary to St. Luke's Hospital, who attended this case while acting as dresser at St. Thomas's Hospital.

CASE VI.

William Chapman, aged fifty years, was admitted into St. Thomas's Hospital, on Thursday, September 10th, 1812, with a dislocation of the left hip upon the dorsum ilii, which was occasioned by the mast of a ship falling upon the part and throwing him down, on the Wednesday *six weeks* prior to his admission into the hospital. It was reduced on Friday, the 11th of September, in the following manner. The patient was bled by opening a

vein in each arm, and thirty-four ounces of blood were taken away. He was then put into a warm bath, and a grain of tartarized antimony given to him, which was repeated every ten minutes; this, with the previous means, produced fainting and nausea.

The patient was then placed on a table on his right side, and a girt was carried between his thighs and over his pelvis, so as completely to confine it; a wetted roller was applied above the knee, and upon it a leathern belt, with rings for the pullies. The extension was then made in a direction causing the dislocated thigh to cross the other below its middle, and in half an hour the reduction was accomplished.

The three following cases shew that we are not to despair of success, even after a considerable time from the accident has elapsed.

CASE VII.

Mr. Mayo has mentioned the case of William Honey, who came into the hospital in August, 1812: the dislocation had taken place seven weeks before, and was reduced the day after his admission; he was discharged, cured, on the 18th of November. This was a dislocation on the dorsum ilii.

CASE VIII.

Mr. Tripe, surgeon at Plymouth, has sent to the Medico-Chirurgical Society, an account of a case of dislocation of the thigh-bone on the dorsum ilii, which had happened seven weeks and one day

prior to his making an extension, in which he was so fortunate as to succeed in restoring the bone to its natural situation.

The following instances prove, indeed, that the dislocation on the dorsum ilii may be reduced without pullies; but they shew, at the same time, how desirable the pullies would have been, especially in the two first instances.

CASE IX.

William Piper, aged twenty-five years, sustained an injury from the wheel of a cart, laden with hay, which passed between his legs and over the upper part of his right thigh. Mr. Holt, surgeon at Tottenham, was sent for nearly a month after the accident had happened; he found him in great pain, attended with fever, and with much local inflammation and tension. He bled him largely, purged him freely, and applied leeches. The leg was shorter than the other, and the head of the bone was seated upon the dorsum ilii; the knee and foot were turned inwards.

As I visited Tottenham frequently at that time, Mr. Holt asked me to accompany him to see the man, and we agreed to the propriety of making a trial at reduction. Mr. Holt and myself, assisted by five strong men, exerted our best endeavours for that purpose. Repeatedly fatigued, we were several times obliged to pause and then renew our attempts. At length, exhausted, we were about to abandon any further trial, but agreed to make one last effort; when, at fifty-two minutes after the commencement of the attempt, the bone slipped into its socket.

CASE X.

I also, in a case which I attended with Mr. Dyson, in Fore Street, succeeded in reducing the limb without the pullies; but the violence used was so great, and the extension so unequal (our fatigue being nearly as severe as that of the patient), that I am confident no person who had used pullies in dislocation of the hip, would have recourse to any other mode, excepting in the dislocation into the foramen ovale.

CASE XI.

Mary Bailey, aged seven years, was admitted into Guy's Hospital, June 16th, 1819, under the care of Mr. Astley Cooper, for a dislocation of the os femoris upwards on the dorsum ilii. This accident was occasioned by the child swinging on the shaft of a cart, which, being insecurely propped, suddenly gave way, and she fell to the ground upon her side. The nature of the accident was exceedingly evident; the limb on the dislocated side was at least two inches shorter than the other; the toe rested on the tarsus of the opposite foot, and was turned inwards; the knee was also inverted and rested on the other. The child was admitted into the hospital at half-past five in the afternoon, the accident having happened a little more than half an hour before. Where so little resistance was expected the pullies appeared unnecessary, and towels were substituted, one being applied above the knee, and the other between the pudendum and thigh; then, bending the knee, and bringing the thigh across the other just above the knee, gradual extension was made, and in about four minutes the head

of the bone suddenly snapt into its socket. On the seventh day the child was walking in her ward, and suffered little inconvenience.

To Mr. Daniel, one of Mr. Lucas's dressers, I am obliged for the foregoing particulars; he having reduced the limb in the presence of many of the students.

CASE XII.

In this case the extension was made at the ancle, and it is consequently worthy of attention:

My dear Sir,

William Sharpe, an athletic young man, in wrestling, received a fall; his antagonist falling with and upon him, their legs were so entangled that he cannot say how he came to the ground. He complained of great pain in the hip, and was incapable of rising. About twenty minutes after the accident, I found him lying on his belly in the field where it had occurred, and the left limb in a trifling state of abduction, shortened, and the knee and foot turned inwards, the prominency of the trochanter gone, and the head of the bone obscurely felt on the dorsum ilii. He was conveyed home, and in order to reduce the dislocation, for such I considered it, I placed the man on his right side diagonally across a four-post bedstead. The centre of a large sheet, rolled up, was passed in front and behind the body, and fastened to the upper bed-post, as low as possible. The centre of a napkin, rolled in like manner, was then applied upon the dorsum ilii, between its crista and the dislocated bone; and each extremity being brought

under the sheet, forwards and backwards, was reflected over it and tied in the centre, by which means I hoped to keep the pelvis secure; the counter-extending force was applied above the ancle (it appearing to me to interfere less with the muscles upon the thigh), first, by rolling round a wetted towel, and then placing upon this the end of a long or jack-towel: three men were now directed to pull gradually and steadily; and when I perceived that the head of the femur was brought down to the edge of the acetabulum, I raised it a little with my clasped hands, placed under the upper part of the thigh, and immediately the head of the bone entered the cotyloide cavity with a smart snapping noise. The man had considerable pain about the hip and knee for some time, but is now quite well.

I am, dear Sir,

Nottingham, Your's truly,

August 8th, 1819. HENRY OLDNOW.

CASE XIII.

Dudley, January 19th, 1824.

DEAR SIR,

A youth, about sixteen or eighteen years of age, while at his work in a pit, was buried under a fall of coals; and besides being severely injured in several other parts of his body, had one hip dislocated on to the dorsum of the ilium, and the same thigh broken about the middle of the bone. As the reduction of the hip was, of course, impracticable, the thigh was bound up in the usual manner, and treated without any reference to the dislocation of the joint, with a hope that when the thigh-bone was re-united,

the hip might possibly be reduced. At the end of five weeks, the bone appearing tolerably firm, I had a very careful but unremitting extension of the limb made by means of pullies, and, in less than half an hour, had the satisfaction of feeling the head of the bone re-enter the socket. It is very probable that the reduction would have been accomplished in less time, had I dared to allow a more powerful extension of the limb, but I very much feared lest a separation of the newly united bone should be produced by it. The patient became so upright as to shew scarcely any signs of lameness afterwards.

I have met with several instances of these accidents conjoined with another injury, which at first sight presented a complication sufficiently embarrassing, but without being, in reality, productive of much additional difficulty. I allude to cases in which, with dislocation of one hip, there has been a fracture of the bone of the opposite thigh. In such circumstances I have fixed some splints temporarily, but very firmly, upon the broken limb, and then, turning the patient on that side, have proceeded to the reduction of the dislocated hip in the usual way. After this has been accomplished, I have taken the splints from the broken limb, and bound it up again in the customary manner; and every case which I have seen has done well, without any additional inconvenience.

I once witnessed a case, which I mention rather for its singularity than for any practical inference which it furnishes.—A man had received (I forget how) a severe hurt on one of his hips. When laid on a bed for examination, the thigh-bone was found not to be broken, and the limbs were exactly of the same length;

but the foot of the injured side turned somewhat inwards, and any attempt to move the hip-joint was extremely painful. On a more careful examination of the parts about the hip, it was plain that the thigh-bone was dislocated, and that its head was on the dorsum of the ilium, and yet the limb seemed not at all shortened. A brief enquiry, however, led to an explanation of this apparent anomaly. It appeared that the opposite thigh-bone had been formerly broken, and had united in such a way as to leave the limb several inches shorter than it had originally been; and the dislocation of the other thigh upwards, had now brought that to a corresponding length. It is scarcely needful to add, that the reduction of the dislocation restored the patient to his former lameness, and to the deformity produced by limbs of unequal length.

With the greatest respect,
I remain, dear Sir,
Your most obedient Servant,
JOHN BADLEY.

To Sir Astley Cooper.

CASE XIV.

DISLOCATION OF THE THIGH UPON THE DORSUM ILII, WITH FRACTURE OF THE THIGH-BONE.

Abraham Harman, aged thirteen years, a patient under Mr. Forster, in Guy's Hospital, gave the following account of his accident:

About four months since, he drove his master's horses to a chalk-pit; he went down into the pit to pack the chalk, and to break it into small pieces, and whilst he was thus occupied, the side of the pit gave way, and a large piece of chalk striking him violently on the hip, knocked him down. Being immediately taken to a neighbouring public-house, a surgeon was sent for. The thigh was discovered to be fractured near its middle, but very considerable contusions prevented the dislocation from being at first discovered. Fomentation and other means of reducing the swelling at the hip being employed, it was ascertained that the thigh was also dislocated, and some attempts were made to reduce it; but the fracture would not then bear the extension, and the boy was sent to the hospital. No attempts have been made to reduce the bone.

This case presented unusual difficulties; and the probability is, that dislocation thus complicated with fracture, will, generally, not admit of reduction; as an extension cannot be made, until three or four months have elapsed from the accident, and then only with strong splints upon the thigh, to prevent the risk of disuniting the fracture.

CASE XV.

Marlborough, Feb. 12, 1823.

Sir,

Permit me to send you the following case of dislocation of the thigh-bone on the dorsum of the ilium.

George Davies, aged thirty-five, on the first of the present

month, in descending a flight of steps at a mill in this neighbourhood, with a sack of wheat on his back, missed a step or two, and in endeavouring to regain his footing, the whole weight of the load fell upon him, and the violence of the shock bore him down several steps lower, where he lay totally incapable of further motion till assistance was procured.

He was then conveyed to the adjoining village. On examination, the limb was found considerably shorter than its fellow, the foot turned inwards, and resting upon the tarsus of the other leg. The head of the bone was distinctly felt, lodged among the glutei muscles. All the other symptoms were unequivocal. In about three hours after the occurrence of the accident, due preparation having been made, thirty ounces of blood were taken from the arm, the pullies were adjusted according to your directions, and gradual extension being made, the head of the bone was eventually brought on a line with the acetabulum; a towel was now passed under the thigh, by which means the bone was elevated, and suddenly, with an audible snap, it slipped into its proper cavity. The man is going on well, but as he is still suffering from the effect of the contusion, he has not been allowed to make much use of his limb.

I am, Sir,

Your's respectfully,

T. Maurice.

P.S. The reduction was accomplished in about ten minutes.

DISLOCATION DOWNWARDS, OR INTO THE FORAMEN OVALE.

Anatomy.

The foramen ovale is formed by the junction of two bones, the ischium and the pubes; it is situated below the acetabulum, and is somewhat nearer the axis of the body. It is filled by a ligament which proceeds from the edges of the foramen, and has an opening in its upper and anterior part, to permit the passage of the obturator blood-vessels, and the obturator nerve. It is covered on its external and internal surface by the obturator externus, and obturator internus muscles.

Mode of accident.

This dislocation happens when the thighs are widely separated from each other. The ligamentum teres and the lower part of the capsular ligament are torn through, and the head of the bone becomes situated in the posterior and inner part of the thigh, upon the obturator externus muscle.

It has been erroneously supposed, that the ligamentum teres is not torn through in this dislocation; because in the dead body, when the capsular ligament is divided, the head of the bone can be drawn over the lower edge of the acetabulum without tearing the ligamentum teres. But the dislocation in the foramen ovale happens whilst the thighs are widely separated, during which act the ligamentum teres is upon the stretch; and when the head of the bone is thrown from the acetabulum, this ligament is torn through before it entirely quits the cavity.

Symptoms.

The limb is in this case two inches longer than the other. The head of the bone can be felt by pressure of the hand, upon the

inner and upper part of the thigh towards the perineum, but only in very thin persons. The trochanter major is less prominent than on the opposite side. The body is bent forwards, owing to the tension of the psoas and iliacus internus muscles. The knee is considerably advanced if the body be erect; it is widely separated from the other, and cannot be brought, without great difficulty, near the axis of the body to touch the other knee, owing to the extension of the glutei and pyriformis muscles. The foot, though widely separated from the other, is, generally, neither turned outwards nor inwards, although I have seen it varying a little in this respect in different instances; but the position of the foot does not in this case mark the accident. The bent position of the body, the separated knees, and the increased length of the limb, are the diagnostic symptoms. The position of the head of the bone is below, and a little anterior to, the axis of the acetabulum; and a hollow is perceived below Poupart's ligament.

We have an excellent preparation of this accident in the collection at St. Thomas's Hospital, which I dissected many years ago. The head of the thigh-bone was found resting in the foramen ovale, but the obturator externus muscle was completely absorbed, as well as the ligament naturally occupying the foramen, now entirely filled by bone. Around the foramen ovale, bony matter was deposited so as to form a deep cup, in which the head of the thigh-bone was inclosed, but in such a manner as to allow of considerable motion; and the cup thus formed, surrounded the neck of the thigh-bone without touching it, and so inclosed its head, that it could not be removed from its new socket without breaking its edges. The inner side of this new cup was extremely

Dissection.

smooth, not having the least ossific projection at any part to impede the motion of the head of the bone; which was only restrained by the muscles from extensive movements. The original acetabulum was half filled by bone, so that it could not have received the ball of the thigh-bone if an attempt had been made to return it into its natural situation. The head of the thigh-bone was very little altered; its articular cartilage still remained; the ligamentum teres was entirely broken, and the capsular ligament partially torn through; the pectinalis muscle and adductor brevis had been lacerated, but were united by tendon; the psoas muscle and iliacus internus, the glutei and pyriformis, were all upon the stretch. Nothing can be more curious, or, to the surgeon and physiologist, more beautiful, than the changes produced by this neglected accident, which exemplify the resources of nature in producing restoration.

Reduction.

The reduction of this dislocation is in general very easily effected. If the accident has happened recently, it is requisite to place the patient upon his back, to separate the thighs as widely as possible, and to place a girt between the pudendum and the upper part of the luxated thigh, fixing it to a staple in the wall. The surgeon then puts his hand upon the ancle of the dislocated side, and draws it over the sound leg, or, if the thigh be very large, behind the sound limb, and the head of the bone slips into its socket. Thus I saw a dislocation reduced, which had happened very recently, and which was subjected to an extension in St. Thomas's Hospital, almost immediately after the patient's admission. In a similar case, the thigh might be fixed by a bed-post received between the pudendum and the upper part of the limb, and the leg be carried

inwards across the other. But in general it is required to fix the pelvis by a girt passed around it, and crossed under that which passes around the thigh, to which pullies are to be attached, otherwise the pelvis will move in the same direction with the head of the bone. *(See plate.)*

In those cases in which the dislocation has existed for three or four weeks, it is best to place the patient upon his sound side; to fix the pelvis by one bandage, and to carry under the dislocated thigh another bandage, to which the pullies are to be affixed perpendicularly; then to draw the thigh upwards, whilst the surgeon presses down the knee and foot, to prevent the lower part of the limb being drawn with the thigh-bone. Thus the limb is used as a lever of very considerable power. Great care must be taken not to advance the leg in any considerable degree, otherwise the head of the thigh-bone will be forced behind the acetabulum into the ischiatic notch, from whence it cannot be afterwards reduced.

Dislocation of the Right Thigh into the Foramen Ovale.

CASE I.

A gentleman was thrown from his horse on the 4th of January, 1818, by the animal suddenly starting to the right side; and whilst he endeavoured to keep his seat by the pressure of the right thigh against the saddle, he was thrown, and from the fall received a severe contusion upon his head, which produced alarming symptoms. On the following day it was observed that the right thigh

was useless, and that the knee was raised and could not be brought into a straight line with the other, having at the same time a direction outwards, which required it to be tied to the other knee: the symptoms of injury to the head precluded, at this time, the attempt at reduction. In fourteen days he was so far recovered that he was able to rise from his bed, and in a month he began to walk with crutches.

On November 1st, 1818, I first saw him; and the appearances of the injured limb were then as follow:—the thigh was longer than the other by the length of the patella; the knee was advanced; and when he was in the recumbent posture, the injured leg could not be drawn down to the same length with the other. The upper part of the thigh-bone was thrown backwards, so as to render the hollow of the groin on the injured side deeper than that on the other. The toes were rather everted, but when the body was erect, were capable of resting on the ground, though the heel was not. The head of the bone could not be felt, and the trochanter was much less prominent than usual. When the upper part of the thigh-bone was pressed against the new acetabulum, and moved, there was a sensation of friction between two cartilaginous surfaces, which, although not easily described, is readily distinguished from the crepitus occasioned by a fractured bone. In a sitting posture the injured leg was two inches longer than the other; and to that degree the knee was projected beyond the sound one. In progression the knee was bent; and the body being thrown forwards the patient rested chiefly upon his toe, and halted exceedingly in walking. The sartorious and gracilis muscles were very much put upon the stretch. At first he suffered much

from pain in the dislocated hip and thigh, but is now free from pain, unless when he attempts to stand on that limb only. His toe, at first, was with difficulty brought to the ground, but he is now improved in walking; for when he first made trial, with the assistance of a crutch and stick, he could not exceed half a mile, but he is now capable to walk two miles. In flexion his thigh admits of considerable motion, but he cannot extend it further than to bring the ham to the plane of the other patella. The knees cannot be brought together, but he advances one before the other in the attempt. He can sit without pain, but the jolting of a carriage hurts him exceedingly; and the attempt to sit on horseback produces excessive suffering. He cannot straighten his leg when his body is erect, nor can he stoop to tie his shoe on the injured side. Pain is produced by resting on that hip in bed. No attempt was made to reduce the limb; the injury to the head might have rendered it dangerous in the commencement, and at the time when I saw him there was no chance of success.

Sir,

Inclosed is the case of dislocation which you requested me to forward to you, and I am sorry it has not been in my power to put you in possession of it before, for reasons which I stated when I saw you last.

I am, Sir,

Leadenhall Street,
February 18*th*, 1820.

Your obliged Servant,
J. S. Daniell.

Dislocation of the Right Femur Downwards, or into the Foramen Ovale.

CASE II.

Mr. Thomas Clarke, a farmer, about fifty years of age, was driving home in his cart from market, when the horse took fright and ran away with him. The following is the account he gives of the manner in which the accident happened:—in his endeavour to stop the horse, he fell over the front of the cart on his face, and the knee struck against some part of it in the act of falling, by which means the thighs were separated; the wheel, he also states, passed over his hip.*

My friend, Mr. Potter, of Ongar, in Essex, whose ability as a surgeon in that neighbourhood is justly appreciated, was consulted in this case, between two and three weeks after the accident had happened; and, as I was visiting him at the time, I had the pleasure of accompanying him.

The nature of the accident was extremely evident; the limb was fully three inches longer than the other, the body bent forwards, the knees separated, and the foot rather inclined outwards; these were the leading diagnostic marks. Mr. Potter, having clearly ascertained the position of the dislocated limb, I accompanied him the following morning, in order to assist in the reduction; and the following were the means employed.

Our first object was to produce relaxation; and finding the

---

* *Query.*—Was this, or the extended state of the limbs, the cause of the dislocation?

patient was sufficiently strong to bear the plan usually recommended in cases of dislocation, where much resistance is expected, we drew away some blood from the arm; this, however, was not sufficient for our purpose, and a solution of tartar emetic, which we had brought with us, was administered. The patient was laid upon his side, close to the edge of the bed (that being the most convenient place), a girt was passed round the pelvis, and carried through the frame of the bedstead, which completely prevented the possibility of the body moving whilst extension was going on; a second girt was applied between the thighs, fixed to the one above, to which the pullies were attached. Whilst extension was making, Mr. Potter took hold of the limb at the knee, and drew it rather upwards, and towards the sound thigh, occasionally rotating the limb. When the extension had been continued about ten minutes, the nausea produced by the tartar emetic was so excessive, that the patient begged of us to desist until the morrow, observing, he felt so bad that he was fearful of falling off the bed: this exclamation, it hardly need be said, was a stimulus to our proceeding; and in five minutes after, the limb was suddenly heard to snap into its original cavity. The patient was put to bed, a roller being applied round the pelvis, and at the end of five days, he felt so well that he left his room; and at the expiration of a short time, suffered no other inconvenience than stiffness in the joint.

J. S. Daniell.

Mr. Daniell's knowledge of his profession, and his zeal in the pursuit of it, which I have had frequent opportunities of observing, will ensure his success whenever he embarks in practice.

A. C.

Mischief from improper extension.

Although a dislocation into the foramen ovale may be occasionally reduced by attempts made in a very inappropriate direction, yet an instance has occurred which shews the mischief that may arise from an error in this respect.

Case.

I once saw the following case:—a boy, sixteen years old, had a dislocation of the thigh into the foramen ovale: he was placed upon his sound side, and an extension of the superior part of the thigh was made perpendicularly; the surgeon then pressed down the knee, but the thigh being at that moment advanced, the head of the bone was thrown backwards, and passed into the ischiatic notch; from which situation it could not be reduced.

I am indebted to Mr. Key, for the particulars of the annexed case, which was admitted into Guy's Hospital, under Mr. Forster.

Dislocation of the Thigh into the Foramen Ovale.

CASE III.

Stephen Holmes, aged forty-one, while working in a gravel pit, at Camberwell, was suddenly overwhelmed by a large mass of gravel, and remained buried under it, till dug out by his companions. When the gravel was removed, he was found in a sitting posture with his legs widely separated, and unable to approximate them. In this position he was brought to Guy's, about seven o'clock in the evening, an hour after the accident had happened, and was placed under the care of Mr. Carey, dresser to Mr. Forster.

Being undressed and placed in bed in the recumbent posture, he was seen lying with his left thigh bent upon the pelvis, his knee consequently elevated, and the whole limb fixed at a considerable distance from the other. On carrying the eye to the upper part of the thigh near the hip-joint, a considerable change in form was manifest; the projection of the trochanter was entirely lost, and in its place a deep hollow was perceptible; and at the inner part of the thigh, near the pubes, a distinct projection appeared, having the form of the head of the bone covered by the adductor muscles. From these general appearances, we regarded the accident as a dislocation of the femur into the foramen ovale of the pelvis, and proceeded to make a more minute examination of the limb, to ascertain the precise nature of the injury.

The man was desired to rise from his bed and sit on the edge of it, which he did without inconvenience or pain; in this position his left knee projected at least two inches and a half beyond the sound limb; this apparent elongation of the leg, arose principally from the oblique bearing of the pelvis, the real elongation being afterwards ascertained to be not more than an inch and a quarter. In the erect posture, which he maintained with some difficulty, his body was bent forward in consequence of the projection of the pelvis over the thigh; the knee was bent, and the toe, which was slightly inverted, rested on the ground; the whole limb was advanced before the sound one, and remained in a state of abduction. He was then laid upon a firm table on his back, and the capability of motion in the limb was carefully noted. His knee was first bent toward his breast without any difficulty, and to as full an extent as the opposite limb; the power of

abduction was also complete, and the attempt was unattended with pain; but extension and adduction of the thigh were the motions most impeded. When the limb was made to approximate to the sound one, which could not be done without producing pain and numbness on the inner side of the thigh, the patellæ remained eleven inches distant from each other; and as soon as the hand was withdrawn from the ancle, the leg flew outward with a spring, from the reaction of the two small glutœi. The limb could not be carried backward, but remained permanently bent at the hip-joint; and when any attempt was made to fix it, the patient complained of great pain in the direction of the psoas and iliacus muscles. The depression observed at the site of the trochanter was such as to render it difficult to feel that process; while on the inner side of the thigh, a distinct projection was formed by the head of the bone, which could be felt under the adductors. These latter muscles were rendered very tense by the projecting bone. The nates appeared to preserve their usual form.

Reduction.—Having never had an opportunity of witnessing this kind of dislocation since my attendance at the hospitals, during the last eight years, I wished to see how far the method of reduction which you have laid down was applicable in the present case. Your "Treatise on Dislocations and Fractures" being in the hands of one of the students, we referred to the plate, and proceeded to apply the pullies and bandage in the manner there delineated. The apparatus being once carefully and securely adjusted, required no alteration, as it neither slipped from its situation, nor occasioned any inconvenience to the patient. Extension was then made by drawing the displaced limb across its fellow,

while the pullies drew the head of the bone outwards; but in doing this, we ran some risque of throwing the head of the femur into the ischiatic notch; for the thigh being large and fleshy at the back part, was, when drawn across the other, necessarily carried somewhat forward, and thus tilted the head of the bone backward: had any alteration taken place in the situation of the head of the femur during this extension, it would have been carried under the acetabulum into the ischiatic notch, it was therefore thought adviseable to carry the leg behind the sound one; and as soon as this was done, the head returned, with an audible crash, into the acetabulum. The whole extension occupied fifteen minutes.

This species of dislocation of the femur, is by far the most easy of reduction of any that has come under my observation; and it may be presumed, that had the leg at first been carried behind instead of before the other, the replacement of the limb might have been effected immediately. Where the limb is large it is impossible to carry it in a right line across its fellow; and, perhaps, in order to avoid the danger to which I have alluded, and which I have often heard you point out in your lectures, it would be as well to adopt the line of extension which in this instance answered so well.

October 15, 1822.—This patient could stand by the side of his bed without support in a week after the accident.

W. A. Key.

DISLOCATION BACKWARDS, OR INTO THE ISCHIATIC NOTCH.

Anatomical structure.

The space which is called the ischiatic notch is bounded above and anteriorly by the ilium, posteriorly by the sacrum, and inferiorly by the sacro-sciatic ligament. It is formed for the purpose of giving passage to the pyriformis muscle and to the sciatic nerve, as well as to the three arteries, the glutæal, the ischiatic, and the internal pudendal. In the natural position of the pelvis, it is situated posteriorly to the acetabulum and a little above its level. When the head of the bone is thrown into this space, it is placed backwards and upwards, with respect to the acetabulum; therefore, although I call this the dislocation backwards, it is to be remembered that it is a dislocation backwards and a little upwards.

Nature of the accident.

In this dislocation the head of the thigh-bone is placed on the pyriformis muscle, between the edge of the bone which forms the upper part of the ischiatic notch, and the sacro-sciatic ligaments, behind the acetabulum, and a little above the level of the middle of that cavity.

Detection difficult.

This dislocation is the most difficult both to detect and to reduce: to detect, because the length of the limb differs but little, and its position, in regard to the knee and foot, is not so much changed as in the dislocations upwards: to reduce, because the head of the bone is placed deep behind the acetabulum, and it therefore requires to be lifted over the edge of that cavity, as well as to be drawn towards its socket.

The signs of this dislocation are, that the limb is from half an inch to one inch shorter than the other, but generally not more than half an inch; that the trochanter major is behind its usual place, but is still remaining nearly at right angles with the ilium, with a slight inclination towards the acetabulum. The head of the bone is so buried in the ischiatic notch that it cannot be distinctly felt, except in thin persons, and then only by rolling the thigh-bone forwards as far as the comparatively fixed state of the limb will allow. The knee and foot are turned inwards, but less than in the dislocation upwards; and the toe rests against the ball of the great toe of the other foot. When the patient is standing, the toe touches the ground, but the heel does not quite reach it. The knee is not so much advanced as in the dislocation upwards, but is still brought a little more forwards than the other, and is slightly bent. The limb is so fixed that flexion and rotation are in a great degree prevented. Signs.

We have a good specimen of this accident in the collection at St. Thomas's Hospital, which I met with accidentally, in a subject brought for dissection. The original acetabulum is entirely filled with a ligamentous substance, so that the head of the bone could not have been returned into it. The capsular ligament is torn from its connection with the acetabulum, at its anterior and posterior junction, but not at its superior and inferior. The ligamentum teres is broken, and an inch of it still adheres to the head of the bone. The head of the bone rests behind the acetabulum on the pyriformis muscle, at the edge of the notch, above the sacro-sciatic ligaments. The muscle on which it rests is diminished, but there has been no attempt made to form a new Dissection.

bony socket for the head of the os femoris. Around the head of the thigh-bone a new capsular ligament is formed; it does not adhere to the articulatory cartilage of the ball of the bone which it surrounds, but could, when opened, be turned back to the neck of the thigh-bone, so as to leave its head completely exposed. Within this new capsular ligament, which is formed of the surrounding cellular membrane, the broken ligamentum teres is found. *(See plate.)* The trochanter major is placed rather behind the acetabulum, but inclined towards it relatively to the head of the bone.

In this specimen, from the appearance of the parts, the dislocation must have existed many years; the adhesions were too strong to have admitted of any reduction, and if reduced, the bone could not have remained in its original socket.

Cause. This species of dislocation is produced by the application of force, when the body is bent forward upon the thigh, or when the thigh is bent at right angles with the abdomen; when, if the knee be pressed inward, the head of the bone is thrown behind the acetabulum.

The reduction of the dislocation in the ischiatic notch, is, in general, extremely difficult, and is best effected in the following manner: the patient should be laid on a table upon his side, and a girt should be placed between the pudendum and the inner part of the thigh, to fix the pelvis. Then a wetted roller is to be applied around the knee, and the leathern strap over it. A napkin is to be carried under the upper part of the thigh. The thigh-bone is then to be brought across the middle of the other thigh, measuring from the pubes to the knee, and the extension is to be

made with the pullies. Whilst this is in progress, an assistant pulls the napkin at the upper part of the thigh with one hand, rests the other upon the brim of the pelvis, and thus lifts the bone, as it is drawn towards the acetabulum, over its lip. For the napkin I have seen a round towel very conveniently substituted, and this was carried under the upper part of the thigh, and over the shoulders of an assistant, who then rested both his hands on the pelvis, as he raised his body, and lifted the thigh. *(See plate.)*

Although the preceding is the method in which this dislocation is most easily reduced, yet I have seen a different mode practised; and I shall mention it here, as it shews how the muscles opposing the pullies, will draw the head of the bone to its socket, when it is lifted from the cavity into which it has fallen.

CASE I.

A man, aged twenty-five, was admitted into Guy's Hospital, under the care of Mr. Lucas; upon examination, the thigh was found dislocated backwards; the limb scarcely differed in length from the other, not being more than half an inch shorter; the groin appeared depressed; the trochanter was resting a little behind the acetabulum, but inclined upon it; the knee and foot were turned inwards, and the head of the bone could, in this case, be felt behind the acetabulum. An extension was made by pullies in a right line with the body; at the same time, the trochanter major was thrust forward with the hand, and the bone returned in about two minutes into its socket with a violent snap.

I have already mentioned, that I have seen no instance of a

dislocation downwards and backwards; and when I state, that I have been an attentive observer of the practice of our hospitals for thirty years, was also for many years in the habit of daily seeing the poor of London at my house early in the morning, and have had a considerable share of private practice, I may be allowed to observe, that if such a case does ever occur, it must be extremely rare. I cannot help thinking, also, that some anatomical error must have given rise to this opinion, as, in the dislocation downwards and backwards, the head of the bone is described as being received still into the ischiatic notch; but this notch is, in the natural position of the pelvis, above the level of the line drawn through the middle of the acetabulum; and hence it is, that the leg becomes, not shorter, but longer, when the bone is dislocated into the ischiatic notch.

Dislocation of the Right Thigh into the Ischiatic Notch.

The following case I received from Mr. Rogers, a very intelligent surgeon, at Manningtree.

CASE II.

Dear Sir,

William Dawson, aged thirty-four, on the 15th of August, 1818, while spending his harvest-home with several of his companions, became quarrelsome with one of them, who threw him down and trod upon him. Upon extricating himself, and endeavouring to rise, he found some serious injury to his right

thigh, rendering him incapable of standing; in this state he was dragged by his associates for many hundred yards into a stable, where he lay till the next morning. I then saw him lying upon a mattress, with the hip and thigh, on the right side, prodigiously swollen and painful; and I was particularly struck with the appearances of the knee and foot on the same side, which were very much turned inwards, but the limb was scarcely shortened. I ordered him to be carefully conveyed home upon a shutter, supported by six men, a distance of about half a mile. From the immense swelling and general enlargement of the whole of the thigh, and of the soft parts around the pelvis, it was impossible to ascertain exactly the state of the injury; but it was fully impressed upon my mind, that there was some unusual dislocation of the head of the thigh-bone. He was accordingly ordered immediately to lose blood, both by general and topical means, and emollient poultices were applied to the whole of the swollen parts; brisk purgatives were also administered, succeeded by saline medicines, and a quiet position was enjoined for eleven days, by which time the swelling began somewhat to subside. Still the precise nature of the injury was not satisfactorily evident; but it was thought by Mr. Nunn, of Colchester, and Mr. Travis, of East Bergholt, who had kindly come over to witness it, that there was a luxation. The only difficulty we had in reconciling this notion to ourselves was, the belief in our minds that no author had adduced an instance of this accident, without an alteration in the length of the limb, except it might be Mr. Astley Cooper, in his new publication, which neither of us had yet seen. We accordingly had recourse to a minute examination of the skeleton;

when we immediately fancied we could account for the absence of the usual marked signs of displacement of the head of the bone, excepting the inversion of the knee and foot, in this kind of luxation; for we noticed, that if the head of the bone be luxated sideways into the ischiatic notch, it will produce scarcely any difference in the length of the limb. Trusting that a little further delay might not be attended with any material disadvantage, but give a chance for the entire subsidence of all the inflammation and swelling, we proposed meeting again as soon as we conveniently could, by which time we might consult Mr. Cooper's book. We accordingly met on Sunday, the 30th of August, which was fifteen days after the accident; and from the complete removal of all swelling, the whole of the femoral bone was satisfactorily traced to its rounded head, which was lodged in the ischiatic notch. Upon referring to the "Essays," which we had now before us, we had the case delineated and described; and as it was exhibited in a plate, we had only to imitate, in order to accomplish the reduction of the bone. In the presence of two or three other medical gentlemen, who had now joined us, we commenced the operation; and as it would be unnecessary to state every particular, considering the manner in which the position of the patient, and the fixing of the pullies and towels, are demonstrated by that publication, suffice it for me to remark, that, after ten or twelve minutes of gradual extension, the reduction of the bone was most readily and admirably accomplished.

Preparatory to commencing the operation, we took thirty ounces of blood from the arm *ad deliquium*, and afterwards, while fixing the pullies, &c., we gave four grains of tartarized

antimony, at intervals, to produce nausea. Immediately after the operation, we gave one grain of opium, applied sedative lotions to the parts, and proceeding carefully for about a fortnight, the patient was enabled to move upon crutches, and was shortly after sent home perfectly well.

I am your's,

Manningtree,
August 15*th*, 1818.

JOHN ROGERS.

The relation of the foregoing case, from the kind manner in which Mr. Rogers has expressed himself, may savour a little of vanity; but I shall readily suffer this imputation; as it will ever be my greatest gratification to find that my humble endeavours may, in the slightest degree, have conduced to the advantage of my professional brethren, or to the benefit of those who may be placed under their care.

Incorrect description by authors.

The dislocation in the ischiatic notch has been, as far as I know, in every author who has written on the subject, incorrectly described; for it has been stated, that the limb was lengthened in this accident, and I need scarcely mention the mistakes in practice to which so erroneous an opinion has given rise; one instance, however, of such an error I must here give. A gentleman wrote to me from the country in these words:—"I have a case under my care of injury to the hip, and I should suppose it a dislocation into the ischiatic notch, but that the limb is shorter, instead of being longer, as authors state it to be." Into this error those authors must have fallen from having examined a pelvis separated

from the skeleton, and observed that the ischiatic notch was below the level of the acetabulum when the pelvis was horizontal, although it is above the acetabulum in the natural oblique position of the pelvis, at least, as regards the horizontal axis of the two cavities. It is to be remembered, that there is no such accident as a dislocation of the hip downwards and backwards.

CASE III.

John Cockburn, a strong muscular man, aged thirty-three, was admitted into Guy's Hospital on the 31st of July, 1819. While carrying a bag of sand, at Hastings, on the 24th of June, he slipped, and dislocated the left hip-joint; and the following is the account he gives of the accident:—the foot on the affected side was plunged suddenly into a hollow in the road, which turned his knee inwards at the same time that his body fell with violence forwards. On the day on which the accident happened, two attempts were made to reduce the dislocation by pullies, but without success; and, on the 27th of June, a third, but equally unsuccessful, trial was made, although continued for nearly an hour. He was directed to Guy's Hospital by Mr. Stewart, surgeon at Hastings.

It was found upon examination, after he had been admitted, that the thigh was dislocated backwards into the ischiatic notch, the limb was a little shortened, the knee and foot were turned inwards, and the toe rested on the ball of the great toe of the other foot; the head of the bone could not be felt; the trochanter major was opposite the acetabulum, the rim of which could be distinctly perceived. When the body was fixed, the thigh could

be bent so as nearly to touch the abdomen. The patient was carried into the operating theatre soon after his admission; and when two pounds of blood had been taken from him, and he had been nauseated by two grains of tartarized antimony, gradually administered, extension was made with the pullies in a right line with the body, and the upper part of the thigh was raised while the knee was depressed; the extension was continued at least for an hour and a half, during which time he took two grains more of tartarized antimony, by which he was thoroughly nauseated; the attempts, however, at reduction, did not succeed.

On the 3rd of August, the tenth day from the accident, Mr. Astley Cooper succeeded in reducing it in the following manner: —he ordered so much blood to be taken from the arm as to produce a feeling of faintness. A table was placed in the centre, between two staples, upon which the patient was laid on his right side; a girt was passed between the scrotum and the thigh, and carried over the pelvis to the staple behind him; and thus the pelvis was, as far as possible, fixed; a wetted roller was carried around the lower part of the thigh, just above the knee, and a leathern strap buckled on it, to which, and to a staple before the limb, the pullies were fixed. The body was bent at right angles with the thigh, which crossed the upper part of the other thigh: then the extension with the pullies was begun, and gradually increased until it became as great as the patient could bear. An assistant was then directed to get upon the table, and to carry a strong band under the upper part of the thigh, by which he lifted it from the pelvis, so as to give an opportunity for the head of the bone to be turned into its socket. Mr. South, who held the leg,

was directed to rotate the limb inwards, and the bone, in thirteen minutes, was heard to snap suddenly and violently into its socket.

JAMES CHAPMAN,
Dresser at Guy's Hospital.

To whom I am indebted for the foregoing statement.

I believe that, in this case, I should not have succeeded in reducing the limb, but from attention to two circumstances: first, I observed that the pelvis advanced within the strap which was employed to confine it, so that the thigh did not remain at right angles; and I was obliged to bend the body forwards to preserve the right angle during extension; and, secondly, the extension might have been continued for any length of time, yet the limb would never have been reduced, but by the rotation of the head of the thigh-bone towards the acetabulum.

Mr. Wickham, jun. of Winchester, has had the kindness to inform me of a case of this dislocation which had been admitted into the Winchester Hospital, under the care of Mr. Mayo, one of the surgeons of that Institution, whose permission I have to state the following circumstances.

CASE IV.

Winchester, August 10, 1819.

John Norgott, aged forty, was brought to the hospital on the 27th of December, 1817, from the neighbourhood of Alton, with

an injury of the hip; twelve days had elapsed since the accident, without his being aware of the nature of the injury. He reported that his horse had fallen with him and on him, so that one leg was under the horse, whilst his body was in a half-bent position, leaning against a bank. He was of middle stature, but very muscular; the leg was very inconsiderably shorter than the other, and but little advancing over it; in fact, the immobility of the limb was the chief criterion of the dislocation; for the head of the bone was thrown into the ischiatic notch. The mode of reduction was simple: Mr. Mayo had the limb extended by the pullies, so as to bring the head of the bone to the edge of the acetabulum, over which it was then tilted by a towel, fastened round the patient's thigh and the neck of an assistant. The man remained three or four weeks before he was allowed to leave the house; but on the 4th of February he was discharged, cured.

The following case was communicated by Mr. Worts, dresser to Mr. Chandler, surgeon to St. Thomas's Hospital.

CASE V.

James Hodgson, a sailor, aged thirty-eight years, a strong muscular man, was admitted into St. Thomas's Hospital, on Tuesday, the 18th of February, for an injury which he had received in his left hip; his foot was raised from the ground upon a chest of fruit, when another fell upon his thigh, striking the knee inwards; he fell, and being taken up extremely hurt, he was directly brought to the hospital. Upon examination, I conceived that it was a dislocation of the hip-joint, and that the

head of the bone was thrown into the ischiatic notch. Some difference of opinion, however, arose upon the subject; and as considerable tension existed, which prevented the head of the bone from being distinctly felt, I ordered an evaporating lotion, and left the case for future investigation. Upon further consideration, my opinion was strengthened concerning the nature of the injury, as it was clearly pointed out by the diminished length of the leg, which was three quarters of an inch shorter than the other, and by the inversion of the foot; although there was in this case more power of flexion in the limb than might have been expected, but no rotation outwards. Mr. Chandler saw the case on Saturday the 12th, and, on account of the tension, he ordered some leeches to be applied to the part, and the lotion to be continued. Mr. Cline saw it this afternoon, and thought it a dislocation in the ischiatic notch.

Monday morning, the 14th. The swelling had greatly subsided, and I thought I could now feel the head of the bone on rotation of the limb. Mr. Chandler saw the case again this morning, and expressed a wish for Mr. A. Cooper to see it. Mr. Cooper, at my request, very kindly saw it in the evening, and immediately declared it to be a dislocation into the ischiatic notch; and upon his rotating the thigh, I could much more distinctly than before feel the head of the bone in the ischiatic notch. Mr. Cooper recommended me to take away blood, which I did the next morning, to the amount of sixteen ounces; this considerably relieved the pain the man had previously suffered, and the tension continued to abate till the Saturday morning following, when Mr. Chandler again saw him, and he thought it had sufficiently

subsided to justify the attempt at reduction. I accordingly made preparations in the following manner:—at about half-past two o'clock, I took sixteen ounces of blood from the patient, which produced no sensible effect; at ten minutes past three, I took about twenty-seven ounces more, and while the blood was flowing, gave him a grain of emetic tartar; this I repeated till he had taken five grains at intervals of a few minutes; and as he was becoming faint, he was taken into the theatre. I applied the bandages and pullies to the pelvis and to the knee, bringing the thigh over the other; we kept up the extension about ten or twelve minutes before we used the strap to raise the head of the bone, and until I thought it had made some progress towards the acetabulum. We then continued the extension, gradually increasing it, at the same time endeavouring to raise the head of the bone and turning the knee outwards, for about fifteen minutes. I had now lost the head of the bone, but still, as it had not made the usual noise in its reduction, I thought that it would be wrong to remove the pullies, as the action of the muscles, if the bone had not been reduced, would have again drawn it up, in which opinion Mr. Martin, who assisted me, concurred. The man was now very faint, the extension was therefore continued for about twenty-five minutes longer, when the strap at the knee getting rather loose, we removed the pullies, upon which it was found that the thigh could now be moved in any direction, and that its position was perfectly natural. The bone was replaced, but at what time it had gained its situation no one could judge, neither could the man describe any feeling that could have indicated it; he was carried to bed in a very faint state.

He had no sickness during or after the extension. I gave him a grain and a half of opium at night, which procured rest.

Sunday morning.—He had some pain remaining, but it was greatly abated, and the thigh could be moved in any direction.

W. Worts,

Feb. 22, 1820. *Dresser to St. Thomas's.*

Mr. Worts naturally expresses surprise that the bone was reduced without its entering the acetabulum with the usual *noise;* but when the muscles have been some time contracted, and when the patient is rendered faint by bleeding, and by the nausea of tartarized antimony, they do not act with the same violence as in the first few hours after the accident.

DISLOCATION ON THE PUBES.

This dislocation is more easy of detection than any other of the thigh. It happens when a person, while walking, puts his foot into some unexpected hollow in the ground; and his body at the moment being bent backwards, the head of the bone is thrown forwards upon the os pubis. A gentleman, who had met with this dislocation in his own person, informed me that it happened whilst he was walking across a paved yard in the dark: he did not know that one of the stones had been taken up, and his foot suddenly sunk into the hollow, and he fell backwards. When his limb was

Cause.

examined, the head of the thigh-bone was found upon the os pubis.

In this species of dislocation the limb is an inch shorter than the other, the knee and the foot are turned outwards, and cannot be rotated inwards, but there is a slight flexion forwards and outwards; and in a dislocation which had been long unreduced, the motion of the knee backwards and forwards was full twelve inches; but the striking criterion of this dislocation is, that the head of the thigh-bone may be distinctly felt upon the pubes, above the level of Poupart's ligament, on the outer side of the femoral artery and vein; and it feels as a hard ball there, which is readily perceived to move by bending the thigh-bone. Symptoms.

Although this dislocation is apparently easy of detection, I have known three instances in which it was overlooked, until it was too late for reduction; of one, we have now a preparation at St. Thomas's Hospital; another occurred to a gentleman from the country, in whom it was not discovered until some weeks after the accident, who then submitted to an extension which did not succeed, and came to London to ask my opinion, when I advised him against a further attempt; and, indeed, he himself was disinclined to any other trial. The third was a patient in Guy's Hospital, who was admitted for an ulcerated leg, and was found to have a dislocation upon the pubes, which had happened some years before. It really must be great carelessness which leads to this error, as the case is so strikingly marked. Not detected

I dissected one of these dislocations, and we have it preserved in our anatomical collection. It shews changes of parts nearly equal to those of the dislocation into the foramen ovale. The Dissected.

original acetabulum is partially filled by bone, and in part occupied by the trochanter major, and both are much altered in their form. The capsular ligament is extensively lacerated, and the ligamentum teres broken. The head of the thigh-bone had torn up Poupart's ligament, so as to be admitted between it and the pubes. The head and neck of the bone were thrown into a position under the iliacus internus and psoas muscles; the tendons of which, in passing to their insertions over the neck of the bone, were elevated by it, and put on the stretch. The crural nerve passed on the fore part of the neck of the bone upon the iliacus internus and psoas muscles. The head and neck of the thigh-bone were flattened, and much changed in their form. Upon the pubes a new acetabulum is formed for the neck of the thigh-bone, for the head of the bone is above the level of the pubes. The new acetabulum extends upon each side of the neck of the bone, so as to lock it laterally upon the pubes. *(See plate.)* Poupart's ligament confines it on the fore part; on the inner side of the neck of the bone passed the artery and vein, so that the head of the bone was seated between the crural sheath and the anterior and inferior spinous process of the ilium.

Distinguished from fracture.

This accident might, by an inattentive observer, be mistaken for a fracture of the neck of the thigh-bone; but the head of the bone felt upon the pubes will decide its nature.

Reduction.

In the reduction of this dislocation, the patient is to be placed on his side on a table; a girt is to be carried between the pudendum and inner part of the thigh, and fixed in a staple a little before the line of the body. The pullies are fixed above the knee, as in the dislocation upwards, and then the extension

is to be made in a line behind the axis of the body, the thigh-bone being drawn backwards. *(See plate.)* After this extension has been for some time continued, a napkin is to be placed under the upper part of the thigh, and an assistant, pressing with one hand on the pelvis, lifts the head of the bone, by means of the napkin, over the pubes and edge of the acetabulum.

The following case, which occurred in Guy's Hospital at the time when my friend, Mr. now Dr. Gaitskill, was dresser to Mr. Forster, will best exemplify the mode of reduction. He was a dresser in the years 1803 and 1804.

Bath, August 13, 1817.

Dear Sir,

The report of the case of dislocated thigh, which I have sent you, contains every material circumstance within my recollection; it will afford me much pleasure if you can extract any thing from it useful or conducive to your purpose.

I remain your's most sincerely,

Joseph A. Gaitskill.

CASE.

A. B. with a dislocation of the os femoris upon the pubes, was admitted into Guy's Hospital, under Mr. Forster, during the time I was one of his dressers.

The length of the limb was somewhat diminished; the foot and knee were turned outwards; but the circumstance which

more clearly evinced the nature of the accident was, that the head of the thigh-bone could be distinctly perceived under the integuments near the groin, where its shape could be ascertained, as well as its motion felt, when the thigh was moved. The accident had happened from a slip or fall he had sustained about three hours before.

With respect to the reduction; as the man was brought into the hospital in the evening, when Mr. Forster was absent, I considered it to be my duty to attempt to replace the bone immediately. I therefore ordered the patient to be carried into the operating theatre; whilst this was doing, I invited my three brother dressers into the surgery, informed them of the accident, and, to avoid confusion, requested each to take some particular part in the process of reduction. The patient was placed on his sound side on a table, the pullies applied to the thigh in the usual manner, and extension began in a straight line, with the design of raising the head of the bone into its socket, but without success. Reflecting then a moment on the mechanism of the bones, and their new relative situation, I changed the line of extension to a little backwards and downwards, and passing a towel over my own shoulders, and under the superior part of the man's thigh, raised it by extending my body.

The leg being kept bent, as from the beginning of the operation, nearly to a right angle with the thigh, I requested one of the dressers to take hold of the ancle, and raise it, keeping the knee at the same time depressed, by which means the thigh was turned over inwards, and in a very short time, the head of the bone snapped into its acetabulum.

J. A. G.

The following case was admitted into St. Thomas's Hospital, under the care of Mr. Tyrrell.

CASE.

Guildhall, February 7th, 1823.

My dear Sir,

I take this opportunity of giving you the particulars of the case of dislocation on the pubes, which you wished for.

Charles Pugh, aged fifty-five, a cooper, about the middle size, on the evening of the 23rd of January, during the time he was making water at the corner of a street, was struck on the back part of the right hip by the wheel of a cart; and the blow knocked him down. He was taken up by some persons passing, who, finding that he was not able to walk, took him to St. Thomas's Hospital. The accident happened about nine o'clock in the evening, and I was sent for between twelve and one o'clock, when I found a dislocation of the right femur on the pubis, the particulars of which were as follows:—

The head of the bone could be distinctly felt below Poupart's ligament, immediately on the outer side of the femoral vessels. The foot and knee were turned outwards, with very little alteration in the length of the limb. The thigh was not flexed towards the abdomen, and was almost immoveable, admitting only of partial adduction and abduction. The limb could be rotated outwards, but not at all inwards. I immediately had the man taken into the operating theatre, and speedily succeeded in reducing the dislocation by the following means:—the patient

was placed on his left side, a broad band was passed between the thighs, and, being tied over the crista of the ilium on the right side, was made fast to a ring fixed in the wall. A wet roller having been put on above the right knee, a bandage was buckled over it, and its straps attached to the hooks of the pullies, by which a gradual extension was made, drawing the thigh a little backwards and downwards. When this extension had been kept up a short time, I directed another bandage to be applied round the upper part of the thigh, close to the perineum, by means of which the head of the bone was raised, and in the course of a few minutes the reduction was easily accomplished. The patient had not been bled or taken any medicine, he suffered but little after the reduction, and was able to walk without pain or inconvenience five or six days afterwards. On the day following the accident, he could move the limb freely in all directions without pain, but did not attempt to walk until the period I have mentioned.

If I have omitted any points, or if you have any wish for further particulars, a message or a note by post, will much oblige

Your's very sincerely,

Frederick Tyrrell,

Surgeon to St. Thomas's Hospital.

From what I have had an opportunity of observing on the subject of dislocations, I believe that the relative proportion of

cases will be in twenty as follows: twelve on the dorsum ilii; five in the ischiatic notch; two in the foramen ovale; and one on the pubes.

The cases I have here detailed, with the dates at which they occurred, shew the frequency with which these accidents happen. The manner in which it escaped the observation of surgeons of eminence of former times, can only be accounted for by the difficulties which then existed in the pursuit of anatomy, and more especially of morbid anatomy: and it is a curious circumstance, that Mr. Sharpe, formerly surgeon of Guy's Hospital, author of a Treatise on Surgery, and in many respects an excellent surgeon, who had a large share of the practice of this town, did not, as I was informed by Mr. Cline, believe that a dislocation of the thigh-bone ever occurred.

It is really gratifying to observe the difference of knowledge in the profession at the present period compared with that of fifty years ago. What should we think of a surgeon in the metropolis in the present day, with all his opportunities of seeing disease in the large hospitals of this city, who doubted the existence of a dislocation of the thigh, when we find that our provincial surgeons immediately detect the nature of these injuries, and generally succeed in their attempts to reduce them? Let them never forget, however, that it is to their knowledge of anatomy, and, more especially, of morbid anatomy, that they are indebted for this superiority.

Mr. Charles H. Todd, surgeon to the Richmond Surgical Hospital, and Professor of Anatomy and Surgery at Dublin, has lately published "An Account of a Dissection of the Hip-Joint after recent Luxation, with Observations on the Dislocations of the Femur upwards and backwards;" from which the following case is extracted:

CASE.

In the summer of 1818, a robust young man, in attempting to escape from his bed-room window, in the second floor of a lofty house, fell into a flagged area; by which accident, his cranium was fractured, and his left thigh dislocated upwards and backwards.

The dislocation was reduced without difficulty; however, an extensive extravasation of blood having taken place on the brain, the patient lingered in a comatose state for about twenty-four hours, and then died. On the next day, dissection was performed, and the following appearances were observed in the injured joint and the parts contiguous to it:

On raising the gluteus maximus, a large cavity, filled with coagulated blood, was found between that muscle and the posterior part of the gluteus medius: this was the situation which had been occupied by the dislocated extremity of the femur. The gluteus medius and minimus were uninjured. The pyriformis, gemini, obturatores, and quadratus, were completely torn across. Some fibres of the pectinalis were also torn. The iliacus, psoas, and adductores were uninjured. The orbicular ligament was entire at the superior and anterior part only, and it was irregularly lacerated throughout the remainder of its extent. The

inter-articular ligament was torn out of the depression on the head of the femur, as in Dr. Scott's case, its attachment to the acetabulum remaining perfect. The bones had not sustained any injury.

The following case, which has recently appeared in one of the Medical Journals, from Mr. Cornish, surgeon at Falmouth, I have thought proper to subjoin, though I must observe, that there is reason to suspect some mistake in the relation, not of the narrator of the case, but of the man himself; as I have carefully examined the books of both hospitals at the period specified, and can find no such name. It is, however, possible that the patient may be able to explain the difficulty; but I wish Mr. Cornish to make further enquiries.

CASE.

In 1812, Mac Fadder, a seaman, about twenty years of age, in coming up from Greenwich to London on the outside of one of the stages, fell from the coach and injured his hip. He was carried into St. Thomas's Hospital, and became Mr. Cline's patient. His case was treated as fracture of the neck of the thigh-bone. Having, after the lapse of some months, experienced no relief from the means that were adopted, he was dismissed with the assurance, that the limb would be useless to him as long as he lived.

The man was subsequently taken into Guy's Hospital. Sir A. Cooper, whose patient he became, thought the head of the femur out of the socket; and after bleeding him, putting him into the warm bath, and administering nauseating doses of tartrate of

antimony, attempted to reduce the dislocation. The attempt was unsuccessful, as were also others that were afterwards made, and he was again dismissed as an incurable cripple.

In 1813, about twelve months after the accident, the man presented himself on crutches at the Falmouth Dispensary, when he gave me the foregoing history of his case. On examining him, I found the injured limb about two inches and a half shorter than the other, entirely useless, producing great pain on bringing it to the ground, and the knee and foot turned inwards. There was considerable distortion about the joint; and the head of the bone appeared to have formed a bed for itself among the muscles on the dorsum ilii. In short, he had every diagnostic symptom of the dislocation upwards.

In consequence of the duration of the accident, and the failure of the attempts at reduction under the management of Sir. A. Cooper, I considered his case a hopeless one, and therefore did nothing for him.

In March, 1818, I met the man carrying a heavy basket on each arm, and walking without the slightest degree of lameness. Although I intimately knew his person, having seen him on crutches about the town for two or three years, I passed him, hardly believing it within the compass of possibility, that he could be my lame patient; but after having walked twenty yards or more, I ran back after him to ascertain the fact. On satisfying myself of his identity, of which I entertained such doubt, and on enquiring into the cause of his cure, he informed me, that in the summer of 1817, *five years after the accident*, whilst on a passage from Falmouth to Plymouth, in a little

coasting vessel, "the ship made a lurch," by which he was thrown out of his birth. At the moment he fell, he heard a loud crack in his hip, and from that time he put aside his crutches, and recovered the perfect use of his limb. The man is now doing duty, as an able seaman, on board a ship which trades from this port to London.

The practical importance of this case is not, perhaps, equal to the curious character of its termination. "It proves," says Mr. Cornish, "the possibility of reducing a displaced joint, even after the lapse of years, when every impediment to reduction may be fairly supposed to exist (particularly the obliteration of the acetabulum), and when most surgeons would judge the attempt hopeless; and it serves to illustrate the proposition, that 'a slight effort, when the muscles are unprepared, will succeed in reduction of dislocation, after violent measures have failed.'"

FRACTURES OF THE OS INNOMINATUM.

Mistake.

As these accidents are liable to be mistaken for dislocations, and as any extension made for them adds extremely to the patient's sufferings, and would be liable to produce fatal consequences if there existed previously a probability of recovery, I am anxious to say a few words upon them.

Symptoms.

When a fracture of the os innominatum happens through the acetabulum, the head of the bone is drawn upwards, and the trochanter somewhat forwards, so that the leg is shortened, and the knee and foot are turned inwards: such a case may be readily mistaken for dislocation into the ischiatic notch. If the os innominatum is disjointed from the sacrum, and the pubes and ischium are broken, the limb is a slight degree shorter than the other; but in this case the knee and foot are not turned inwards, but outwards. Of the first of these accidents I have seen two examples, of the latter only one.

These accidents are generally to be detected by a perceptible crepitus on the motion of the thigh, if the hand be placed upon the crista of the ilium; and they are attended with more motion than occurs in dislocations. Detection.

With respect to the appearances on dissection, they will be seen in plate seventh.

CASE.

A man was brought into St. Thomas's Hospital, in January, 1791, on whom a hogshead of sugar had fallen. Upon examination the right leg was found about two inches shorter than the left, and the knee and foot were turned inwards; these circumstances induced the surgeon under whose care he fell to think the case a dislocation, although, as he stated, the limb appeared to be more moveable than usually happens in such accidents, and there was a great contusion and considerable extravasation of blood. The surgeon used the utmost caution in making a very slight extension, in order to bring the legs to an equal length, in which he did not succeed; and whilst it was performing, a crepitus was discovered in the os innominatum. The man had a remarkable depression of strength, and paleness of countenance, and appeared to be sinking. In the evening he died.

Upon examination of the body the following appearances were observed:—The posterior part of the acetabulum was broken off, and the head of the thigh-bone had slipped from its socket; the tendon of the obturator internus, and the gemini, tightly embraced the neck of the bone; the fracture extended from the acetabulum across the os innominatum to the pubes; the ossa pubis were

separated at the symphysis nearly an inch asunder, and a portion of the cartilage was torn from the right pubes, and adhered to that on the left side; the ilia were separated on each side, and the pubes, ischium, and ilium broken on the left side; the abdomen contained about a pint of blood, and the left kidney was greatly bruised; the integuments were stript off the patella and knee on one side, so as to expose the capsular ligament.

In a second case of this kind, which was admitted into St. Thomas's Hospital, having the appearance of the dislocation backwards, the patient lived four days. On examination, the fracture was found passing through the acetabulum, dividing the bone into three parts; and the head of the thigh-bone was deeply sunk into the cavity of the pelvis.

The following case of fracture and dislocation of the bones of the pelvis lately occurred in Guy's Hospital: I am obliged for the particulars to Mr. Sandford, who attended to this patient as dresser.

CASE.

Mary Griffiths, aged thirty years, was admitted into Guy's Hospital at five o'clock in the afternoon of the 8th of August, 1817. Her pelvis had sustained a severe injury, from her body being pressed by the wheel of a cart against a lamp-post.

A small quantity of blood had been taken from her arm previous to her admission; and as she was very pale, her pulse extremely weak, and her fæces passed involuntary, no more blood was drawn.

Soon after her admission she was examined; when, by placing her on the face, with one of my hands on the back of the right ilium, and the other on the pubes of the same side, a distinct motion and crepitus could be perceived. The posterior spine of the ilium projected upwards, above its usual junction with the sacrum, and it was thought that the ilium was dislocated from the sacrum, with some fracture, either of the ilium, or the sacrum. When she was turned on the back, and examined *per vaginam*, the pubes were found passing more into the cavity of the pelvis than usual. A large quantity of blood was effused from the last rib to the upper part of the thigh, on the right side.

It was now a question whether this extravasated blood should not be discharged by making an opening through the integuments, as it appeared to be fluid; but upon consideration, it was thought that the vessels would still bleed, that she could not bear the loss of blood in her weakened state, and that the blood, when coagulated, would form the best security against further effusion. All that was done, therefore, was to roll a broad bandage round the pelvis to fix it firmly, to give tinct. opii. gt. xxx., and to draw off the urine from her bladder, which contained about a pint.

In the evening, the extravasation of blood was somewhat increased, and she complained of a pricking sensation in the right thigh and leg, which induced her to loosen the bandage. She had vomited; her feet were cold: she had severe pain, and great thirst; her pulse was 90, and small.

On the 9th, she complained of a sensation of one side tearing from the other; and, upon examination of the lower extremities, that on the right side was found shorter than the other; there

was numbness also on that side. Her tongue was furred, but her pain and thirst somewhat less; and she had not the same coldness in her feet as she had the night previous.

As her bowels had not been relieved since her admission, aperient medicine was given to her; and the bladder being incapable of emptying itself, a catheter was employed. The ecchymosis was of great extent, and it was doubtful whether it could be absorbed. A pillow was placed against the right side to support the pelvis, and another was put under the knee, to preserve the limb in an easy position.

In the evening of this day, her pulse was 112. She complained much of pain in the right side and groin. The catheter was again obliged to be used, and aperient medicines to be repeated.

On the morning of the 10th, she complained of the bones of the pelvis moving upon each other, even more than at any former period, and that she had suffered severe pain; the tongue was now furred, her pulse fuller, but her bowels had been relieved, and she had made water without assistance. At one o'clock this day, her pulse being fuller, and 120 in a minute, with great heat of skin, I bled her to the amount of ten ounces; but the blood did not exhibit any signs of inflammation, nor did the loss of blood produce any apparent effect in relieving her symptoms.

In the evening, her pain and fever had increased; and as she complained of the tightness of the bandage which still surrounded the pelvis, it was removed. The catheter was again obliged to be employed. Some saline medicine, with opium, was directed for her.

On the 11th, she stated that she had passed a good night. Her

pulse was 120 and softer; her tongue furred: she was directed to continue her medicines.

A stimulating lotion was ordered her on the 12th, to produce an absorption of the extravasated blood. Some spots appeared of a very dark colour, where the ecchymosis had been most severe, and the cuticle was abraded upon those parts.

On the 13th her report was more favourable; her bowels were open, and her bladder did not require the assistance of the catheter. However, she still complained of severe pain in the hip.

14th. As the excoriated parts seemed disposed to slough, a puncture was made through the integuments, nearly opposite to the trochanter major, and a quart of serum, mixed with the red particles of blood, and with a substance which appeared adipose, was discharged.

On the 15th the fæces and urine had passed into her bed, and she requested to be removed to another; her pulse was 112. The puncture made yesterday does not seem disposed to heal, and a poultice was directed for it.

16th. She expressed herself relieved by her removal into another bed; her pain is less severe; her pulse but 108. She was now directed a diet to support her strength, and some porter was given her; but on the 17th, as she had been observed to be slightly delirious the preceding night, the quantity of porter was lessened.

On the 18th the sloughing of the part, which had been excessively bruised, had considerably increased; yet her tongue was cleaner, and her skin of its natural heat.

On the following day she appeared better; had passed a good night: she was ordered a poultice of stale beer-grounds to the hip; and as she strongly requested it, she was turned on her left side, as her impression was, it would relieve the pain she felt on the right side.

The sloughing of the superior and posterior part of the thigh had increased upon the 20th; and she was ordered the decoction and tincture of bark, with saline medicine if her thirst became urgent; and a more nutritious diet.

On the 21st, the sloughing had increased; the tongue was furred; her pulse was 120. On the 22nd she was worse; and on the 23rd, her stomach rejected every thing: she had a strong impression that she could not recover; she refused her medicine, and the slough had increased. In the evening of the 24th, she died.

Examination.

On the 25th, the body was examined.—A fracture was found passing through the body of the pubes on the left side, and through the ramus of the left ischium.

The right os innominatum was separated from the sacrum at the sacro-iliac symphysis, and a part of the transverse processes of the sacrum was broken off, and torn from the sacrum with the ligaments. The cartilage and ligaments of the symphysis pubis were torn, and the left sacro-iliac symphysis had given way; the ligament over it being torn, and the bones separated sufficiently to admit of the handle of a scalpel being received between them. *(See plate.)*

Blood was found extravasated in the pelvis, behind the peritoneum.

JONATHAN SANDFORD.

I have known three instances of recovery from simple fracture of the os innominatum: two of these were fractures of the ilium, and the nature of the accident was easily detected by the crepitus which was perceived upon moving the crista of the ilium; the third case was a fracture at the junction of the ramus of the ischium and pubes. In the two first a circular roller was applied upon the pelvis, and the patient was freely bled; but in the latter no bandage was employed. I have also known a compound fracture of the os innominatum recover; but Mr. Hulbert, surgeon, sent me a compound fracture of the ilium, which had proved fatal.

Several cases have also occurred within my knowledge of fracture of the pubes, near its symphysis, accompanied with laceration of the bladder, each of which proved destructive; but when the bones have been broken without injury to the bladder, the patients have recovered.* The bladder is burst or not, in this accident, according to its state of distention or emptiness at the moment of the accident; for, if empty, it escapes injury.

---

* There is at this time (Sept. 1823), a case in Guy's Hospital, in which the bladder is believed to be ruptured below the reflexion of the peritoneum, and between it and the pubes, and the man appears recovering by wearing a catheter. But in cases where the injury is above the line of reflexion of the peritoneum, the urine escapes into the cavity of the abdomen, and excites general inflammation.

FRACTURES OF THE UPPER PART OF THE THIGH-BONE.

Before I enter into a description of the dislocations of other joints, it will be proper to point out the fractures incident to the upper part of the thigh-bone, as it is essentially necessary that these accidents should not be confounded with dislocations, or with each other, a mistake which has but too frequently happened. Indeed it must be confessed, that their discriminating marks are sometimes with difficulty detected, and that the different species of fracture are likewise frequently confounded; for three distinct species, very different in their nature and in their result, have been described and classed under the indiscriminate appellation of fracture of the neck of the thigh-bone. Hence has arisen that difference of opinion, which has led to much discussion respecting the processes which nature employs for their cure, and which less hypothetical reasoning, and more attention to the development of such accidents by dissection, would have been

the means of preventing. Whilst one surgeon asserts that all attempts to cure them are unavailing, another maintains that they admit of union like fractures of other bones; which latter opinion is only true as far as regards two species of these fractures.

I shall now, therefore, proceed to state the results of my observations in living persons who have been the subjects of these accidents; of my examination of the dead body; and of some experiments upon inferior animals, which illustrate this subject.

These accidents are more frequent than dislocations of the thigh-bone; for whilst we receive into our hospitals of Guy's and St. Thomas's (containing about nine hundred persons), not more upon an average than two such dislocations in a year, our wards are seldom without an example of fracture of the upper part of the thigh-bone.

Different Species of Fracture of the Upper Part of the Thigh-Bone.

These are, as we have already observed, three in number.

First: That in which the fracture happens through the neck of the bone entirely within the capsular ligament.

Secondly: A fracture external to the ligament, through the neck of the thigh-bone at its junction with the trochanter major; by which the trochanter is split, and the neck of the thigh-bone is received into its cancelli.

Thirdly: A fracture through the trochanter major, beyond its junction with the cervix femoris.

FRACTURES OF THE NECK OF THE THIGH-BONE, WITHIN THE CAPSULAR LIGAMENT.

Appearances

The appearances which are produced by this fracture are as follows:—the leg becomes from one to two inches shorter than the other; for the connection of the trochanter major with the head of the bone, by means of the cervix, being destroyed by the fracture, the trochanter is drawn up by the muscles as high as the ligament will permit, and consequently rests upon the edge of the acetabulum, and upon the ilium above it. The difference in the length of the limbs is best observed by desiring the patient to place himself in the recumbent posture on his back, when, by comparing the malleoli, it will be generally found that one leg is shorter than the other. The usual state of the limb is, that the heel on the injured side rests in the hollow between the malleolus internus and tendo Achillis of the other leg; but there is some variety in this respect; a fork is sometimes formed in the trochanter minor, which catches the neck of the bone, and prevents a greater ascent than half an inch *(see plate)*. Mr. Brodie informs me that he dissected a case in which the cervix was obliquely broken, and in which the upper part of the bone prevented the ascent of the lower. On the other hand, when the fracture has happened for a length of time, and the patient has borne upon the injured limb, the ligament becomes extended, and the leg is shortened four inches; of this Mr. Langstaff mentioned to me an instance in a man of the name of Campbell, aged

Difference in length.

eighty-two, in whom the heel was obliged to be elevated four inches to make the bearing of the limbs equal. I saw the fractured parts in this man, and the shoe he wore, which entirely verified Mr. L.'s statement. The retraction is at first easily removed by drawing down the shortened limb, when it will appear of the same length with the other; but immediately when this extension is abandoned, and the patient exerts himself, the muscles draw it into its former position; and this appearance may be repeatedly produced by extending the limb. This evidence of the nature of the accident continues until the muscles acquire a fixed contraction, which enables them to resist an extension which is not of a powerful kind.

Foot turned outward.

Another circumstance which marks the nature of this injury is, the eversion of the foot and knee; and this state depends upon the numerous and strong external rotatory muscles of the hip-joint, which proceed from the pelvis to be inserted into the thigh-bone, and to which very feeble antagonists are provided: the obturatores, the pyriformis, the gemini and quadratus, the pectinalis, and triceps, all assist in rolling the thigh-bone outwards; whilst a part of the glutæus medius and minimus, and the tensor vaginæ femoris, are the principal agents of rotation inwards. It has been denied that this eversion is caused by the muscles, and it has been attributed to the mere weight of the limb; but any one may satisfy himself that it arises chiefly from the muscles, by feeling the resistance which is made to any attempt at rotation of the thigh inwards. This difficulty is also in some measure attributable to the length of the cervix femoris, which remains attached to the trochanter major; because in

proportion to its length, by resting against the ilium, the trochanter is prevented from turning forwards.

Directly that the bed-clothes are removed, two circumstances strongly arrest the attention of the surgeon: namely, the diminished length of the injured limb, and the eversion of the foot and knee. In the dislocation upwards, the head and neck of the bone prevent the trochanter from being drawn backwards, whilst the broken and shortened neck of the thigh-bone, in fracture of this part, readily admits it; and hence the reason that the foot is inverted in luxation, and everted in fracture. It is, however, proper to state, that an exception to this rule does now and then exist, and that the limb is found inverted; but it is of extremely rare occurrence. Some hours must elapse before this eversion assumes its most decisive character, as the muscles require some time to assume a determined contraction; and this is the reason that the accident has been mistaken for dislocation on the dorsum ilii. The surgeon having been called soon after the accident has happened, before the muscles had acquired that state of contraction to which they are liable, is led to mistake the nature of the injury, because the foot is not so decidedly everted as it afterwards becomes; and for this reason patients, even in hospital practice, have been exposed to useless and painful extensions.

Degree of pain.

In fractures of the neck of the bone within the ligament, the patient, when perfectly at rest in the horizontal posture, suffers but little; but any attempt at rotation is attended with some pain, because the broken extremity of the bone then rubs against the inner surface of the capsular ligament, upon which it is drawn by the action of the muscles. The pain is felt in this accident in the

upper and inner part of the thigh, opposite to the insertion of the iliacus and psoas muscles into the trochanter minor, or sometimes just below this point.

Degree of motion.

The perfect extension of the thigh may be easily effected, but flexion is more difficult, and somewhat painful; and its degree depends upon the direction in which the limb is bent; for if the flexion be outwards, it is accomplished with but little comparative suffering; but if the thigh be directed towards the pubes, the act of bending the limb is with difficulty accomplished, and is attended with greater pain; for it is easier or more difficult, in proportion as the neck of the bone is shorter or longer.

Situation of the trochanter major.

In this accident the trochanter major is drawn up towards the ilium, but the broken neck of the bone attached to the trochanter is placed nearer the spine of the ilium than the trochanter itself, in which situation it afterwards remains; and this alteration of position makes the trochanter project less on the injured side, because it is no longer supported by the neck of the bone, as in its natural state, but rests in close apposition with the edge of the acetabulum, and is, consequently, much more concealed than usual, until the muscles waste from the duration of the injury, when it can be distinctly felt upon the dorsum ilii; but there will be a greater or less projection of the trochanter, proportioned to the length of the fractured cervix attached to it.

Appearance in the erect position.

If doubt exist of the nature of the accident, let the patient be directed to stand by his bed-side, supported by an assistant, and to bear his weight upon the sound limb; the surgeon then observes the shortened state of the injured leg; the toes rest upon the ground, but the heel does not reach it; the knee and

foot are everted; and the prominence of the hip is diminished. The least attempt to bear upon the injured limb is productive of pain, which seems to be occasioned by the tension of the psoas, iliacus, and obturator externus muscles, in the attempt, as well as by the pressure of the broken neck of the bone against the interior surface of the capsular ligament.

Crepitus.

A crepitus like that which accompanies other fractures might be expected to occur in this accident, but it is not discoverable when the patient rests on his back with the limb shortened; if, however, the leg be drawn down, so as to bring the limbs to the same length, and rotation be then performed, the crepitus will be observed, as the broken ends of the bone are thus brought into contact; but the rotation inwards most easily detects the fracture. When the patient is standing on the sound leg, with the fractured limb unsupported, by rotating it inwards, the crepitus will sometimes be perceived, as the weight of the limb brings the broken bones nearer in apposition.

More frequent in women.

Women are much more liable to this species of fracture than men: we rarely in our hospitals observe it in the latter, but our wards are seldom without an example of it in the aged female. The more horizontal position of the neck of the bone, and the comparative feebleness of the female constitution, are the probable reasons of this peculiarity.

To the circumstances I have already mentioned, as strongly characterizing this accident, must be added the period of life at which it usually occurs; for the fracture of the neck of the thigh-bone within the capsular ligament, seldom happens but at an advanced period of life, whilst the other fractures which I have

to describe happen at all periods: and hence has arisen the great confusion with respect to the nature of this injury; for we find that surgeons of the highest character have confounded fractures external to the capsular ligament with those which are within the articulation; and mention the latter as occurring at a period of life in which they scarcely ever happen.* It has been also said, that in early life these bones will readily unite; an assertion which I notice only to shew the confusion which has arisen on this subject.

Old age, however, is a very indefinite term; for in some it is as strongly marked at sixty, as in others at eighty years. That regular decay of nature which is called old age, is attended with changes which are easily detected in the dead body; and one of the principal of these is found in the bones, for they become thin in their shell, and spongy in their texture. The process of absorption and deposition varies at different periods of life; in youth the arteries, which are the builders of the body, deposit more than the absorbents remove, and hence is derived the great source of its growth. In the middle period of life the arteries and absorbents preserve an equilibrium of action, so that, with a due portion of exercise, the body remains stationary; whilst in old age the balance is destroyed, because the arteries act less than the absorbents, and hence the person becomes diminished in weight; but more from a diminution of the arterial than from an increase of the absorbent action. This is well seen in the natural changes

Changes in age in the bones.

* I allude particularly to Dessault.

of the bones, their increase in youth, their bulk, weight, and little comparative change during the adult period, and the lightness and softness they acquire in the more advanced stages of life; hence the bones of old persons may be cut with a pen-knife, which is incapable of making any impression on those of adults. Even the neck of the thigh-bone in old persons is sometimes undergoing an interstitial absorption, by which it becomes shortened, altered in its angle with the shaft of the bone, and so changed in its form as to give an idea, upon a superficial view, that it has been the subject of fracture, thus leading persons into the erroneous supposition, that the bone has been partially broken and re-united; but it requires very little knowledge of anatomy to distinguish in the skeleton, the bone of advanced age from that of the middle period of life.

Age at which it occurs.

The age at which fractures of the neck of the thigh-bone within the capsular ligament generally occur, is a most important consideration; and as it is one on which the practice of the surgeon very much hinges, I shall take the liberty of making the following statement.

I have now been thirty-nine years at St. Thomas's and Guy's Hospitals; and, for thirty years, have had more than my share, and much more than I merited, of the practice of London. We have eight hundred and fifty patients in our two hospitals; and I believe that in the two hospitals, eight cases of fractures of the upper part of the thigh-bone occur in each year; but in order to avoid exceeding the average number, I will consider them only as five per annum; thirty-nine multiplied by five, produce one hundred and ninety-five; add to these one case only in each year,

in my private practice of thirty years, they will collectively amount to two hundred and twenty-five cases; now, in that time, I have only known *two cases* of fracture of the neck of the thigh-bone within the capsular ligament *occur under fifty years of age;* one was in a patient aged thirty-eight, who had an aneurism of the iliac artery; and the other has been kindly shewn to me by that excellent anatomist, Mr. Herbert Mayo.

This fracture, then, rarely occurs under fifty years of age; and dislocation seldom at a more advanced period, although there are exceptions to this rule; for I have myself once seen the fracture at thirty-eight years of age, but it was very oblique; and a dislocation of the thigh at sixty-two; but between fifty and eighty years is the period at which the fracture most usually occurs; for from the different state of the bone, the same violence which would produce dislocation in the adult, occasions fracture in old age. But when dislocation does occur between sixty and seventy years, it is in persons whose constitutions are particularly strong, and in whom age has not produced those changes in the bones which I have already endeavoured to point out.

Slight cause producing this fracture.

That this state of bone in old age tends much to the production of fractures, is shewn by the slight causes which often occasion them. In London, the accident most frequently occurs when persons, walking on the edge of the elevated foot-path, slip upon the carriage pavement; though the descent be only a few inches, yet, being sudden and unexpected, and the force acting perpendicularly, with the advantage of a lever in the cervix, it produces a fracture of the neck of the thigh-bone; and as a fall is the consequence, the fracture is imputed, by ignorant persons, to the fall,

and not to its true cause. Other trivial accidents may occasion the misfortune. I was informed by a person who had sustained a fracture of this kind, that being at her counter, and suddenly turning to a drawer behind her, some projection in the floor caught her foot, and preventing its turning with the body, the neck of the thigh-bone became fractured. A fall upon the trochanter major will also produce it; but I have dwelt particularly on the *slight* causes by which it is occasioned, that the young surgeon may be upon his guard respecting it, as he might otherwise believe that an injury of such importance could scarcely be the result of a slight accident, and that excessive violence is necessary to break the neck of the thigh-bone; such an opinion is as liable to be injurious to his reputation, as the error of confounding this accident with dislocation.

Union of this fracture.

Much difference of opinion has existed upon the subject of the union of the fractured neck of the thigh-bone: it has been asserted that these fractures unite like those of other parts of the body; but the dissections which I made in early life, and the opportunities I have since had of confirming these observations, have convinced me, that fractures of the neck of the thigh-bone,—those of the patella,—olecranon,—and condyles of the os humeri,—and that of the coronoid process of the ulna, *generally* unite by ligament, and not by bone. This principle I have taught in my lectures for thirty years; and it is a most essential point, as it affects the reputation of the surgeon. I was called to a case of this fracture, in which the medical attendant had been promising, week after week, an union of the fracture, and the restoration of a sound and useful limb. After many weeks, the

patient became anxious for further advice: I did all in my power to lessen the erroneous impression which had been made, by telling the patient that she might ultimately walk, although with some lameness: and taking the surgeon into another room, asked him upon what grounds he was led to suppose there would be union, to which he replied, he was not aware but that the fracture of the neck of the thigh-bone would unite like those of other bones of the body; the case, however, proved unfortunate for his character, as this patient did not recover in the usual degree.

Young medical men find it so much easier a task to speculate than to observe, that they are too apt to be pleased with some sweeping conjecture, which saves them the trouble of observing the processes of nature; and they have afterwards, when they embark in their professional practice, not only every thing still to learn, but also to abandon those false impressions which hypothesis is sure to create. Nothing is known in our profession by guess; and I do not believe, that from the first dawn of medical science to the present moment, a single correct idea has ever emanated from conjecture: it is right, therefore, that those who are studying their profession, should be aware that there is no short road to knowledge; that observations on the diseased living, examinations of the dead, and experiments upon living animals, are the only sources of true knowledge; and that inductions from these are the sole basis of legitimate theory.

In all the examinations which I have made of transverse fractures of the cervix femoris entirely within the capsular ligament,

I have never met with one in which a bony union had taken place, or which did not admit of a motion of one bone upon the other. To deny the possibility of this union, and to maintain that no exception to the general rule can take place, would be presumptuous, especially when we consider the varieties of direction in which a fracture may occur, and the degree of violence by which it may have been produced; as, for example, when the fracture is through the head of the bone,* and there is no separation of the fractured ends; or, when the bone is broken without its periosteum being torn; or, when it is broken obliquely, partly within and partly externally to the capsular ligament; but I wish to be understood to say, that if it ever does happen, it is of extremely rare occurrence, and that I have not yet met with a single decisive example of it.† As a proof that the general principle which I have stated is correct, I subjoin the following account of forty-three cases, from different collections, of non-union by bone, in fractures of the neck of the thigh-bone:—

---

* Much trouble has been taken to impress the minds of the public with the idea, that I have in my Work on Dislocations and Fractures denied the possibility of union of the fracture of the neck of the thigh-bone, and therefore I beg at once to be understood, that I believe the reason that fractures of the neck of the thigh-bone do not unite is, that the ligamentous sheath and periosteum of the neck of the bone is torn through, and that there is, in consequence of this circumstance, a want of nourishment of the head of the bone; but I can readily believe, that if a fracture should happen without the reflected ligament being torn, that as the nutrition would continue, the bone might unite; but the characters of the accident would differ; the nature of the injury could scarcely be discerned, and the patient's bone would unite with little attention on the part of the surgeon.

† In Mr. Cross's account of his visit to the French hospitals, some interesting matter upon this subject will be found.

In the collection at St. Thomas's	7	specimens.
In the College of Surgeons	1	ditto.
In St. Bartholomew's	6	ditto.
At Dublin	12	ditto.
In Mr. Langstaff's, of Basinghall-street	6	ditto.
In Mr. Bell's and Mr. Shaw's	6	ditto.
In Mr. Brookes's	2	ditto.
In Dr. Monro's	2	ditto.
Mr. Mayo's collection	1	ditto.
	43	

To these I have to add another, from an experiment upon a living animal; while, upon the opposite side of the question, only a single instance, upon which the mind can for a moment dwell, has yet been produced; and in this case the same appearances were found in both the thigh-bones, and even these resembled what I have several times observed in the dead body, arising from a softened state of the bones. I have given a plate of some of these appearances, and the preparations I shall at all times be happy to shew to any of my professional brethren who may wish to see them.

Cause of the want of union.

Having thus explained what is the common result of these cases in relation to their want of union, I shall now proceed to state the reasons which may be assigned for the absence of ossific union in the transverse fracture of the neck of the thigh-bone within the capsular ligament.

Want of proper apposition.

The first reason is the want of proper apposition of the bones:

for if their broken extremities in any part of the body be kept much asunder, ossific union is prevented.

In a boy, who had a compound fracture of the tibia, without the fibula being broken,* and who had the protruded end sawn off, the two extremities were prevented from coming in contact by the fibula, and union never occurred. My friend, Mr. Smith, an excellent surgeon, at Bristol, had a similar case under his care, in which a portion of the tibia having been sawn off, the fibula, remaining whole, prevented ossific union.†

This fact is easily seen by experiments on animals: I sawed seven-eighths of an inch of the radius from a rabbit, and the ends of the bones were not united to each other, but only to the ulna. I also sawed off the extremity of the os calcis, and suffered it to be drawn up by the action of the gastrocnemius muscle, and it united only by ligament. *(See plates.)*

---

* If the fibula be broken, large pieces of the tibia will separate, and yet ossific union will ensue.

† The particulars of the Case were as follow;—The boy was admitted into the Bristol Infirmary for disease of the tibia; and the diseased portion not exceeding more than from two to three inches in length, that part of the bone was removed by the saw. In a month the limb had acquired so much firmness, that the boy was permitted to walk about the ward, which he was able to perform tolerably well, and in six weeks no doubt was entertained that ossification had taken place in the uniting substance; at this time he sickened with the small-pox and died.—Upon examination, the edges of the extremities of the tibia were found absorbed and rounded, and on the inferior portion, a bony callus had formed, about three quarters of an inch in extent; no ossific matter was discoverable in the greater part of the space originally occupied by the diseased bone, but a tough though thin ligamentous band extended from the superior to the inferior portion of the tibia.—*See Medical Records and Researches.*

The following communication is from Mr. Benjamin Bell, of Edinburgh.*

CASE.

26, St. Andrew Square, Edinburgh ;
August 7th, 1823.

My dear Sir,

Excuse the freedom I take in communicating to you the outline of a case, the result of which I had an opportunity of observing a short time ago—as it is connected with the subject so admirably developed in your late valuable publication, it may, perhaps, prove interesting. In the progress of a tour through some parts of Cumberland last month, I had occasion to visit Whitehaven; Mr. Fox, an able and intelligent surgeon, of that place, was so kind as to shew me the case alluded to. He was also so good as to favour me with an account of its progress.

June, 1822.—William Coulthard, aged thirty-five, of a plethoric habit, a miner, while stemming a bore, preparatory to blasting a rock, the powder, in consequence of the friction, inflamed, and exploding, gave rise to the following accident:—One portion of the rock struck him in the perineum, and occasioned a compound fracture of the tuberosity of the left ischium, which was followed by profuse hæmorrhage. Another portion of the rock came in contact with the left leg, about four inches below the knee, and

---

* A highly respectable and intelligent individual; grandson of Mr. Benjamin Bell, who was a most useful man to the profession by his publications: and son of Mr. George Bell, also a most able surgeon, of Edinburgh.—Mr. Bell is likely to be a worthy successor to such a father.

shattered the tibia and fibula. Four large loose pieces of bone were extracted, by Mr. Fox, immediately after the accident. These portions, when united, formed about *six inches* of the entire cylinder of the tibia. The sides of the wound were then drawn together, and retained "in situ" by adhesive plasters. The limb was placed in a proper position, and secured by pads and wooden splints. In a short time the wound in the leg healed up; three months, however, after it had healed, an abscess formed, and another small portion of bone came away, probably a part of the fibula. The wound healed again without any untoward symptom.

The day on which I saw him (July 22nd, 1823), the leg in which the injury had occurred appeared to be about two inches shorter than the other. A large cicatrix occupied the fore and middle part of the shin; the patient could extend the leg and stamp on the floor with considerable force; the muscles were plump and firm; but the leg was to a certain extent flexible, and could be slightly bent by the hands in four different directions: backwards, forwards, to the right and to the left, on seizing it below the knee (and above the fracture), and at the ancle. He suffered no pain, and permitted the limb to be freely handled, but could not, at that time, bear the whole weight of the body upon it. It seemed to me as if the space between the two ends of the fractured bones had been filled up with a sort of ligamento-cartilaginous matter, resembling that found in cases of fracture of the neck of the femur external to the ligament, or in that occurring in illtreated cases of transverse fracture of the patella. Whether that conjecture be right or not, it is difficult to determine.

A number of small pieces of bone have been extracted from the

wound in the perineum, and a pretty large loose portion can be felt at present with the probe. In other respects the man's health is good, and he expresses an anxious desire to return to his work.

Your much obliged,
And sincerely grateful Pupil,
BENJAMIN BELL.

The neck of the thigh-bone when broken, is placed under similar circumstances; for, by the contraction of the muscles, it is no longer in apposition with the head of the bone, and is, therefore, prevented from uniting; but, if this were the only obstacle, it would be argued that the retraction of the thigh-bone might be prevented by bandaging and extension, the truth of which cannot be denied; but it is scarcely possible, even for a few hours, to preserve the limb in exact apposition, as the patient, on the slightest change of position, produces instant retraction, by bringing into action those powerful muscles which pass from the pelvis to the thigh-bone.

So in fractures of the patella, although we often do all in our power to prevent retraction of the muscles, yet it very rarely happens that we are able to support a complete approximation of the bones.

Absence of continued pressure.

The second circumstance which prevents a bony union in these fractures is, the want of pressure of one bone upon the other, even if the length of the limb were preserved; and this will operate in preventing an ossific union in cases where the capsular ligament is

not torn; and in all those which I have had an opportunity of examining, it has not been lacerated. The circumstance to which I allude, originates in the secretion of a quantity of fluid into the joint; from the increased determination of blood to the capsular ligament and synovial membrane; a superabundance of serous synovia,—that is, synovia much less mucilaginous than usual,—extends the ligament, and thus entirely prevents the contact of the bones, by pushing the upper end of the body of the thigh-bone from the acetabulum. After a time this fluid becomes absorbed, but not until the inflammatory process has ceased, and ligamentous matter has been effused into the joint from the interior of the synovial surface. The muscles, also, do not in this accident produce pressure between the broken extremities of bones, which so greatly conduces to the union of other fractures; for if two broken bones overlap each other, on that side on which they are pressed together, there is an abundant ossific deposit; but on the opposite side, where there is no pressure, scarcely any change is observed. So also we find that, if the ends of the bone be drawn from each other by the action of muscles, as sometimes happens in the fractures of the os femoris, tibia, os humeri, radius and ulna, union is not effected until the surgeon, by a strong leathern bandage tightly buckled around the limb, compels the bones to press upon each other, and thus support the necessary inflammation for the production of ossific union. When a fracture occurs amidst muscles, those which are inserted into the fractured part of the bone, have generally a tendency to keep the extremities of the bones together, with some few exceptions; but when a fracture occurs in the

neck of the thigh-bone, the muscles have only an influence upon one portion of the fractured bone; and this influence serves to draw one part from the other.

But the third and principal reason which may be assigned for the want of union of this fracture is, the almost entire absence of ossific action in the head of the thigh-bone when separated from its cervix; its life being supported by the ligamentum teres, which has only a few minute vessels, ramifying from it to the head of the bone. The structure of the neck of the thigh-bone, and of the parts surrounding it, is explained in the account of the anatomical plate connected with this part of my subject. But here it may be observed, that the neck and head of the thigh-bone are naturally supplied with blood by the periosteum of the cervix, and that when the bone is fractured, if, as most frequently happens, the periosteum be torn through, the means of ossific action are, in consequence of such fracture and laceration, necessarily destroyed in the head of the bone. Scarcely any change, therefore, takes place in the head or neck of the bone attached to it; no deposite of cartilage or bone, similar to that of the other fractured bones, is produced; but the deposite which does take place, as will be seen in the plates of fracture of the neck of the thigh-bone, consists of ligamentous matter, covering the surface of the cancellated structure with little patches like ivory on the head of the bone.*

Little action in the head of the bone.

The appearances which are found on the dissection of these

Dissection of this fracture.

* But if I attempt to prevent union in a fracture external to a joint, by moving the bone from time to time, I find that in proportion to that motion, is the quantity of callus produced, which is just the reverse in the accidents I am now describing.

injuries are as follow:—the head of the bone remains in the acetabulum attached by the ligamentum teres. There are, upon parts of the head of the bone, very small white spots like ivory. The cervix is sometimes broken directly transversely, at others with obliquity. The cancellated structure of the broken surface of the head of the bone and of the cervix, is hollowed by the occasional pressure of the neck attached to the trochanter, and consequent absorption; and this surface is sometimes partially coated with a ligamento-cartilaginous deposite. The cancelli are rendered firm and smooth by friction, as we see in other bones which rub upon each other when their articular cartilages are absorbed. Portions of bone are formed or broken off, and these are found either attached by means of ligament, or floating loosely in the joint, covered by a ligamentous matter; but these pieces do not act as extraneous bodies, so as to excite inflammation, and thus produce their discharge, any more than those loose portions of bone covered by cartilage, which are found so frequently in the knee, and sometimes in the hip and elbow joints. With respect to the neck of the bone which remains attached to the trochanter major, the most remarkable circumstance is, that it soon becomes in a great degree absorbed, leaving but a small portion of it remaining; its surface is yellow, and extremely smooth, if the bones have rubbed against each other. Some ossific deposition I have seen manifested around this small remaining part of the neck of the bone, and upon the trochanter major and thigh-bone below it, in some examples of this fracture. We do not, however, observe the same process of union as in other bones, but a ligamentous instead of an ossific union.

The capsular ligament enclosing the head and neck of the bone becomes much thicker than natural, but the synovial membrane undergoes the greatest change from inflammation, being very much thickened, not only upon the capsular ligament, but also upon the reflected portion of that ligament upon the neck of the bone, as far as the edge of the fracture. Ligament and synovial membrane.

Within the articulation is found a large quantity of serous synovia; by which term I mean to express, that the synovia is less mucilaginous, and contains more serum than usual, mixed with a small quantity of blood; this fluid, by gradually extending the ligament, separates for a time one portion of bone from the other; it is produced by the inflammatory process, and becomes absorbed when the irritation in the part subsides. I do not know the exact period at which this change takes place, but I have seen it in the recent state of the injury. Into this fluid is poured a quantity of ligamentous matter, by the adhesive inflammation excited in the synovial membrane, and flakes of it are found proceeding from its internal surface, uniting it to the edge of the head of the bone. Thus the cavity of the joint becomes distended, in part by an increased secretion of synovia, and in part by the solid effusion which the adhesive inflammation produces: the membrane reflected on the cervix femoris is sometimes separated from the fractured portions, so as to form a band from the fractured edge of the cervix to that of the head of the bone; bands also of ligamentous matter pass from the cancellated structure of the cervix to the head of the bone, serving to unite, by this flexible material, the one broken portion of bone with the other. Effusion into the joint. New ligament. Union by ligament.

The trochanter is drawn up, more or less, in different accidents;

and in those cases in which it is very much elevated, I have known a considerable ossific deposite take place upon the body of the thigh-bone, between the trochanter major and the trochanter minor. When the bone has been macerated, its head is much lighter and more spongy than in the healthy state, excepting on those parts most exposed to friction, where it is rendered smooth by the attrition, which gives it a polished surface.

These then are the usual appearances on dissection; but there are two preparations in the Royal College of Surgeons in London, which have been sent as specimens of union by bone of the cervix femoris; but as I may be thought prejudiced in favour of the opinion I have advanced, I shall give that of an excellent anatomist whose loss we have had lately to deplore. Mr. Wilson says, "*I have examined very attentively these two preparations, and cannot perceive one decisive proof in either, of the bones having been actually fractured.*"

This circumstance, of want of ossific union, is not peculiar to the neck of the femur, as will be seen in our account of fractures of the condyles of the os humeri, of the coronoid process of the ulna, and of bones generally, when seated within the capsular ligament.

It appears, then, as a general principle, from the account which I have given of the dissection of those whose bodies have been examined after having suffered from this fracture, that ossific union is not produced; that nature makes slight attempts for its production upon the neck of the bone, and upon the trochanter major, but scarcely any upon the head of the bone; and that if union be produced, it is by means of ligament.

Mr. Stanley, for whom I have great respect, both as an anatomist and a surgeon, has met with the appearance of fracture in the neck of each thigh-bone, in the same subject. I do not mean to deny the possibility of the necks of both thigh-bones in this subject having been fractured, because that point can only be determined by the history of the accident, and by a very careful and accurate examination of several sections of the bones; but I can shew that similar effects are produced by disease.

The neck of the thigh-bone in adult persons of middle age, has a close cancellated structure, with considerable thickness of the shell which covers it; but in old subjects, the cancellated structure of the shaft of the bone, which is formed of a coarse net-work, loaded with adipose matter, is often extended into the neck of the bone, and the shell which covers it becomes so thin, that when a section is made through the middle of the head and cervix, it is found diaphanous; of this I have several specimens. As the shell becomes thin, ossific matter is deposited on the upper side of the cervix, opposite the edge of the acetabulum, and often a similar portion at its lower part, and thus the strength of the bone is in some degree preserved: this state may be frequently seen in very old persons. Mr. Steel, of Berkhampstead, one of the most intelligent surgeons, and most respectable men I know, gave me the thigh-bone of a person thus altered, whose age was ninety-three.

When the absorption of the neck proceeds faster than the deposite on its surface, the bone breaks from the slightest causes, and this deposite wears so much the appearance of an united fracture, that it might easily be mistaken for it. Before the bone thus alters, we

sometimes meet with a remarkable buttress shooting up from the shaft of the bone into its head, giving it additional support to that which it receives from the deposite of bone upon its external surface. But another change is also produced from disease, of which the following is the history, and which directly applies to the subject before us :—

Old bed-ridden and fat persons (generally females), are often brought into our dissecting-room with some of their bones broken (and more frequently the thigh-bone than any other) in being removed from the grave. If the cervix femoris of such persons be examined, it will be found that the head of the bone is sunken down upon its shaft, and that the neck of the thigh-bone is shortened, so that its head is in contact with the shaft of the bone opposite to the trochanter minor; and at the part at which the ligament is inserted into the neck of the bone, the phosphate of lime is absorbed, and a ligamento-cartilaginous substance occupies its place; either extending entirely through the neck of the bone, or partially, so that one section exhibits signs of it, and in another it is wanting. The bone, in some cases, is so soft and fragile, both in its trochanter and head, that it will scarcely bear the slightest handling; and the motion of the thigh-bones in the acetabulum is almost entirely lost, so that the persons must have had little use in their lower extremities.

During the last winter we had two instances of this alteration in the neck of the bone, and it is an appearance which I have several times seen.

In examining the body of an old subject, very much loaded with fat, in the dissecting-room of St. Thomas's Hospital, I found

that the gentleman who had dissected one limb, had cut through the capsular ligament of the hip-joint, and tried to remove the head of the thigh-bone from the acetabulum; but the neck of the bone broke on the employment of a very slight force, and upon a further trial to remove it, the bone crumbled under his fingers. As the other limb was not yet dissected I requested Mr. South, one of our demonstrators, to remove, with care, the upper part of the other thigh-bone; but although he used great caution in doing it, he could not remove the bone without fracturing the upper part of its shaft; but he succeeded in removing the upper part of the bone, so that it might be preserved; and of this I have given plates.

We have here then a case in which the neck of the bone was absorbed, so that the head was brought in contact with the trochanter; in which, most decidedly, there had not been a fracture, although it had in some parts the appearance of one; and in which, the disease occurred in each hip-joint.

Another case of the same kind was examined by Mr. South, during the last winter, which, so far as relates to the softened state of the upper part of the thigh-bone, was similar to the former; the heads were spongy, the necks were shortened, so that there was scarcely any remaining; each trochanter was light in weight, spongy, and very large; and there was little if any motion in either of the hip-joints, so that both limbs appeared, at first sight, as if dislocated upon the pubes.

But the best specimen of this state of the bone is the following, which I preserve with the most assiduous care, and value in the highest possible degree:—I have had for twenty years in the

collection of St. Thomas's Hospital, the thigh-bone of an old person, in which the head of the bone had sunken towards its shaft. I have been in the habit of shewing this bone twice a year as a specimen how bones sometimes become soft from age and disease, and from the absorption of their phosphate of lime; and I have frequently cut with a penknife both its head and its condyles, to shew this softened state. On sawing through its cervix, the cartilage, deprived of its phosphate of lime, had dried away in several parts, and the appearance was such that a person, ignorant of the change, would have declared it to be a fracture; only, that in some sections the cartilage had taken different directions, and in some the bone was not yet entirely absorbed. We have also in the Museum of St. Thomas's Hospital, a skeleton in which both the thigh-bones, and each os humeri, are, in a subject extremely altered by rickets, divided by similar portions of cartilage, in which no ossific matter exists.

The plates which are appended will afford better ideas of these morbid changes than words can convey; and I hope Mr. Stanley, also, will give plates of his preparations; *both*, however, should be engraved, as, without both, the public cannot form a correct opinion.

I have been led to prosecute the inquiry by experiments upon animals. I found it difficult to succeed in breaking the bone in the direction I wished, and, after a great number of experiments, was successful only in the following instances; the preparations of these I have preserved, and they may be seen in the Museum at St. Thomas's Hospital. (*See plate.*)

Experiment I.

The neck of the thigh-bone was fractured in a rabbit, on October 28th, 1818; and on December 1st, 1818, as the wound had been some time healed, I dissected the animal.

Appearance on dissection.—The capsular ligament was much thickened; the head of the bone was entirely disunited from its neck, but adhered by a new ligamentous substance to the capsular ligament; the broken cervix, which was very much shortened, played on the head of the bone, and had smoothed it by attrition; the head of the thigh-bone had not undergone any ossific change.

Experiment II.

The neck of the thigh-bone was broken in a dog, November 18th, 1818, and the animal was killed on the 14th of December following.

Dissection.—The trochanter was much drawn up by the action of the muscles, so that the head and cervix femoris were not in apposition. The capsular ligament was much thickened, and contained a large quantity of synovia.

The joint was lined with adhesive matter of a ligamentous appearance, adhering to the head of the bone, which did not seem to be changed by any ossific process; but the thigh-bone around the capsular ligament, the trochanter major, and the bone a little below it, were enlarged.

We find, therefore, by these dissections, that what appears in the human subject after this accident, takes place also in other

animals; and that motion, want of apposition and pressure, with the little ossific action in the head of the bone, under these circumstances, produce a deficiency of bony union, as in man.

The two preparations which I have preserved, were the only examples in which the experiment was complete in relation to the transverse fracture; but I have two other interesting preparations derived from these experiments. I also made a great number of others, in which the fractures continued compound; in each of these the head of the bone either became absorbed, or was discharged by ulceration; and I never could succeed in uniting the head to the neck of the bone. I have since divided the neck of the thigh-bone in a dog, and the head of the bone was three-fourths absorbed. By way of contrast I have also divided the bone externally to the capsule, in five instances, and have preserved the bones; the wounds united by adhesion, and every bone has been healed by ossific union; the natural inference is, that fractures within the capsule, do not unite by bone, but that fractures external to it, readily do so. As to the notion that the bearing upon the limb, or its weight, may have influence to prevent union in these animals, I have only to observe, that the muscles become contracted, the limb drawn up, and the animal cannot bear upon it for several weeks.

My friend, Mr. Brodie, has furnished me with the following account of an experiment which he made upon the same subject, which fully confirms my observations.

Dear Sir,

The circumstances of the experiment which I mentioned, were briefly these:—The tibia of a guinea-pig was broken at the lower end. A month afterwards the animal was killed. On dissection, I found a fracture extending across the tibia, transversely, and so close to the ancle-joint, that it was situated at that part of the bone which is covered by the reflected layer of the synovial membrane. The synovial membrane itself, and the ligaments of the joint, appeared to have been very little injured, and the broken surfaces had remained in good apposition; nevertheless, there was not the smallest union of them, either by bone or ligament, and there had been no formation of callus round the fracture. The bone in the neighbourhood of the fracture had become compact and hard, in consequence of the ossification of the medullary membrane lining the cancelli.

I am, dear Sir, your's truly,

Saville Row, B. C. Brodie.

August 16*th*, 1823.

Professor Burns, of Glasgow, has had the great kindness to send me the following observations:—

"Permit me to offer my warmest thanks for the pleasure and edification I have received from the study of your late work.

I was early led to attend to the process adopted by nature in forming a new articulation in injuries to the hip-joint, by the dissection of a dog which I had when a boy, and which had the hip fractured. Many years afterwards I examined the parts, and found the fragment of the cervix belonging to the head absorbed, the head itself filling the acetabulum; the shaft of the bone expanded, and a new head formed for a new socket, and the whole enveloped in a dense capsule or covering.

"In a fracture of the os femoris external to the capsule, the gluteus medius and minimus seem to act as a cushion to stop the ascent of the end of the cervix, whilst the fragment attached to its head will, perhaps, afford some opposition; but in the fracture within the capsule, the end of the cervix is drawn more freely up under the gluteus medius, and lodged behind the inferior spinous process of the ilium.

"Is this the explanation of the greater shortening in the one fracture than in the other?

"Nothing can better explain the want of ossific union than the principle you have laid down."

JOHN BURNS.

Glasgow, 1823.

Having by experiment ascertained the circumstances I have mentioned, I was next anxious to learn if the head and neck of the thigh-bone would unite under a longitudinal fracture, in part within and in part external to the capsular ligament, in which apposition, contact, and pressure are maintained; and for this purpose I made the following experiment:—

Experiment III.

I divided the head, neck, and a portion of the trochanter major of the thigh-bone of a dog longitudinally, by placing a knife on the trochanter major, and striking it down towards the acetabulum through the head of the bone. The animal was killed twenty-nine days after, and the following appearances presented themselves :— Longitudinal fracture.

A portion of the trochanter major had been broken off, and was only united by cartilage. The head and neck of the bone, which had been longitudinally broken, were united; the neck by a larger quantity of ossific deposite than that which joined the separated portions of the head of the bone, and so irregularly as to make a beautiful preparation, and shew the circumstance most clearly. (*See plate.*) This bone may be seen in the collection at St. Thomas's Hospital.

Whether the union began in the fracture externally to the ligament, and proceeded inwards, or whether on the whole surface at once, it is impossible to ascertain; but the coalescence was firm, though, as I have stated, I thought more so at the neck than at the head of the bone. The union in this case is readily explained. Apposition was supported; the vessels of the head of the bone and cervix remained whole; and, therefore, this experiment shews at once why the longitudinal unites, and the transverse, in general, does not.

Thus, then, it appears, that in a longitudinal fracture of the head and neck of the bone *in part external to the ligament,* if the bones be applied to each other, pressed together, and in a state of rest, and the vessels remain, ossific union can be Uni… these bon…

produced; although the ossific deposition is extremely slight when compared with that of other bones.

Diagnosis. The fracture of the neck of the thigh-bone may be confounded with the dislocation of the os femoris upon the dorsum ilii; with that into the ischiatic notch; and with that upon the pubes; as in all these luxations the limb is shorter. From the two former it may be distinguished by the eversion of the foot, and by the mobility of the limb in fracture; and from the latter by the ball of the os femoris being felt in the groin in the dislocation on the pubes; otherwise the eversion of the foot in both cases might lead to their being confounded.

Treatment. With respect to the treatment of fractures of the neck of the thigh-bone within the capsular ligament, various are the means to which I have had recourse, and which I have known resorted to by others, for the purpose of producing union in this accident, but all without avail.

One mode has consisted in placing the fractured limb over a double inclined plane, by which a regular and constant extension is preserved, and which, by raising the planes at the knee, may be increased to any degree that the surgeon may require, or the patient can bear; at the same time, a bandage is applied around the pelvis and upper part of the thigh, to bring the neck of the bone, as much as possible in approximation with the head from which it has been separated; and this extension, with pressure, has been steadily preserved for three months. With respect to the patient's body, it has been placed at an angle of forty-five degrees.

A second method has consisted in placing a board at the foot

of the bed, upon which the foot of the sound limb is rested, so as to prevent the descent of the body in the bed; the other limb is then extended as much as possible, and a weight, appended to the foot, is suffered to hang through a hole in the board over the end of the bed, in order to support the extension with regularity and steadiness for several weeks.

In a third method, the patient has been placed in bed with both limbs extended to the utmost possible degree, and then the two feet have been bound together by a roller, passed from the foot on the injured side under the sound foot, so as to make one limb steadily preserve the extension of the other. Or this may be effected by an iron plate fixed to the shoe on the sound foot, with a screw passed through a hole in the plate, and having a band fixed to the other foot, which may be tightened by turning the screw, and the foot, by this means, be kept constantly extended.

A fourth mode employed for this purpose has been the application of Boyer's splint, with the intention of extending the limb from the pelvis: but this splint, though it answers well for fractures of the thigh under ordinary circumstances, has a tendency to prevent union in those fractures which occur at the upper part of the bone, by the pressure of its band upon the inner and upper portion of the thigh.

Mr. Hagedorn has recommended a machine for fractures of the neck of the thigh-bone, which is very ingenious in its construction. It consists of a long splint to extend from the hip to the foot, and which is to be firmly applied, by means of proper straps, to the sound limb; at the bottom of this is fixed a broad

foot-board, perforated with a sufficient number of openings to receive the bands, by means of which both feet are to be securely fixed to it; these bandages are attached to a kind of leather gaiter, made to lace tight round the ancle, and the upper part of the splint is kept close to the hip by means of a broad bandage carried round the pelvis. By this machine the extension of the limb is tolerably well effected, so long as the patient can be kept still; but a displacement of the bones will invariably be the consequence of every motion which the evacuation of the fæces will necessarily require. I am never so wedded to any opinion as to be prevented from trying, or from wishing others to employ, every means which appear plausible or ingenious; and, therefore, I think that this instrument ought to have a fair trial.

Mr. Earle is of opinion, that these cases may be cured by long continued attention in keeping the parts at perfect rest. I think a trial should be made of the bed recommended by Mr. Earle, and heartily wish him success in his laudable attempt to prevent the lameness and shortening of the limb in cases of fracture within the capsule; which has invariably been the result in those cases I have had an opportunity of witnessing.

But all the means which I have seen used have been found unavailing. I have been baffled at every attempt to cure, and have not yet witnessed one single example of union in this fracture. I know that some persons still believe in the possibility of this union, by surgical treatment, and that instances of success have been published; but I cannot give credence to such cases until I see that the authors were aware of the distinction between fractures within and external to the articulation.

The following anecdote was related to me by an intelligent surgeon, who had been attending an hospital on the Continent for some time. One of the surgeons belonging to it observed, "Some of the English surgeons do not believe that we unite fractures of the neck of the thigh-bone; now there is one you shall examine, as the patient is dying." A few days after, the patient died, and the joint was examined, when the bone was found still disunited. The surgeon of the hospital only made a significant shrug of disappointment.

The cases in which union might be produced are two: one, in which the periosteum, covering the neck of the thigh-bone, is not torn through, a circumstance which now and then happens; the other, in which the head of the bone is broken, so that the cervix still remains in the acetabulum: but in neither of these cases will the limb exhibit the shortened state which the fracture of the neck of the bone usually produces, and therefore the common characters of the accident will be wanting. Even in such cases, I would prefer a ligamentous union, to the confinement and danger of bony union, in regard to the health and life of the person, and, as I believe, to the subsequent use of the joint.

Baffled in our various attempts at curing these cases, and finding the patient's health suffering under the trials made to unite them, I should, if I sustained this accident in my own person, direct that a pillow should be placed under the limb throughout its length; that another should be rolled up under the knee, and that the limb should be thus extended for ten days or a fortnight, until the inflammation and pain had subsided. I should then daily rise and sit in a high chair, in order to prevent a degree of

flexion, which would be painful; and, walking with crutches, bear gently on the foot at first; then, gradually more and more, until the ligament became thickened, and the muscles increased in their power. A high-heeled shoe should be next employed, by which the halt would be much diminished. Our hospital patients, treated after this manner, are allowed in a few days to walk with crutches; after a time a stick is substituted for the crutches, and in a few months they are able to use the limb without any adventitious support.

The degree of recovery in these cases is as follows:—if the patient be very corpulent, the aid of crutches will be for a long time required; if less bulky, a stick only will be sufficient; and where the weight of the body is inconsiderable, the person is able to walk without either of these aids, but drops a little at each step on that side, unless a shoe be worn having a sole of equal thickness to the diminished length of the limb. In every case, however, in which there is the smallest doubt whether it be a fracture within, or external to, the ligament, it will be proper to treat the case as if it were the fracture which I shall hereafter describe, and which admits of ossific union.

It is gratifying to find opinions which have been for thirty years delivered in my lectures, confirmed by the observations of intelligent and observing persons; and, therefore, it was with pleasure that I read in the Dublin Hospital Reports, the account of the dissection of several cases of fracture of the cervix femoris, by my friend, Mr. Colles, of Dublin (a man excellently informed in his profession), who found in them similar want of ossific union, in the fracture within the ligament, to that which I have described.

A few contributions of a similar kind, from the ardent cultivators of morbid anatomy, would soon prevent persons from being tortured with trials, which have been frequently repeated, and found to be uniformly unavailing.

ADDITIONAL OBSERVATIONS ON FRACTURES OF THE NECK OF THE THIGH-BONE.

The following Letters, which were appended to the former editions of this work, I have embodied here; each of them being interesting in regard to the facts upon this subject. One from Mr. Stanley, Assistant-Surgeon of St. Bartholomew's Hospital, and Demonstrator of Anatomy at that hospital; one from Dr. Monro, Professor of Anatomy at Edinburgh; and the other from Mr. Colles, Professor of Anatomy and Surgery at Dublin.

Lincoln's Inn Fields, February 25th, 1823.

My dear Sir,

We have in the Museum of St. Bartholomew's, twelve specimens of fractures in the neck of the thigh-bone; six external to the capsule, and united, and six within the capsule. In three of the latter there is no union, and in the other three there is union by ligamentous matter.

I remain, dear Sir,

Your's most respectfully,

Edward Stanley.

This letter shews the difference of fractures within and fractures external to the ligaments, in regard to their union.

Edinburgh, February 17th, 1823.

My dear Sir Astley,

In answer to your query respecting fracture of the neck of the thigh-bone, I beg leave to inform you, that I have had an opportunity of examining two cases only after death, and in both of these, the broken ends of the neck of the bone were united by a substance somewhat like to ligament.

I have seen several persons who had, during their lives, a fracture of the neck of the bone, but in all of them a bony re-union had not taken place.

In the catalogue of the Museum which was bequeathed to the University by my father, mention is made of the fracture of the neck of the thigh-bone which had re-united by a bony union. Upon examining the preparation with attention, it appears to me, that there had been no fracture, but a disease in the trochanter major, and that a number of osseous speculæ have shot upwards within the capsular ligament, giving the appearance of an ill set fracture.

Should you wish to have a drawing of this preparation, I shall have great pleasure in sending it to you.

There is also a specimen in the Museum of a fracture of the thigh, about four lines beyond the insertion of the capsular ligament, at the root of the trochanter.

Your's, most truly,

Alexander Monro.

Stephen's Green, February 12th, 1823.

My dear Sir,

Since the receipt of your letter, I have carefully examined all the specimens of fractures of the neck of the thigh-bone contained in both Museums of our College of Surgeons. In that which is appropriated to the use of the School, I find seven instances of fracture within the ligament; each of these have been described in my paper on this subject, in the Dublin Hospital Reports. Since the publication of that Essay, the conservator of the College-Museum has collected five specimens of fracture within the ligament. In this Museum are also four instances of fracture external to the condyle ligament. In the School-Museum are two instances of fracture external to the ligament. Of this latter description of fracture, fewer than one half the number are united by bony union. Of the fractures within the ligament, not one has made a nearer approach to bony union than that described in the paper alluded to. I must say, that I have never yet seen an instance of bony union where the fracture had been within the ligament. We have very many specimens of a disease of the head and neck of the thigh-bone, which is of frequent occurrence amongst our labouring poor. On this subject I have some idea of writing a paper for the next volume of the Dublin Hospital Reports, and of endeavouring to shew, that in all probability, the supposed cases of fracture within the ligament united by bone, were merely instances of this disease.

If you have any wish for them, I shall have great pleasure in sending you sections of some of these cases, which I am certain

might be passed upon many surgeons for fracture of the neck of the bone.

I am, my dear Sir,
Your most sincere Friend,
A. Colles.

I have also seen three cases of this fracture in the dead body since the publication of the second edition of this work.

First:—A very old female was brought into the dissecting-room at St. Thomas's Hospital, whose right limb was everted, and was an inch and a half shorter than the left. Upon dissection, the sciatic nerve had the appearance of having been bruised; a small portion of bone was broken off at the insertion of the obturator externus muscle; a similar portion of bone was separated at the upper part of the insertion of the quadratus femoris. The capsular ligament was torn at the part at which it is covered by the iliacus internus muscle. The capsular ligament being further opened, was found to contain a small fragment of bone; and it was filled with adhesive ligamentous matter, poured out by inflammation, and adhering to the internal surface of the capsular ligament, to the remnants of the cervix femoris, and, slightly, to the head of the bone. The cervix femoris had been broken close to the head of the bone, and entirely within the capsular ligament. The head of the femur remained in the acetabulum unaltered, excepting that its surface was partially covered by ligament. The neck of the bone was so absorbed, that the portion of it which remained was smaller than the trochanter minor. Its cancellated structure was covered by the effused ligamentous matter. There

was not the slightest appearance of ossific union, or even of bony deposite, although this injury must, from the changes produced by inflammation, have happened from two to three months before death. When I had raised the thigh-bone one inch and a half, it was prevented from rising higher by the lower portion of the gluteus minimus, and by the capsular ligament.

Second:—Mr. Clarke gave me a preparation made from the body of a man, eighty-two years of age, tall and remarkably strong for the time of life, who died eight weeks and four days after having fractured the neck of the thigh-bone. Upon inspection, not the least attempt at ossific union was found. The ligamentous sheath of the cervix femoris was only partially torn.

Third:—Mr. Key, Surgeon to Guy's Hospital, gave me the head and neck of the thigh-bone, taken from a subject brought into the dissecting-room; in which case, the neck of the thigh-bone was absorbed. The head of the thigh-bone was entirely detached from the cervix. No ossific process existed in the cancelli of either the neck or head of the bone, but some ossific deposite appeared around the insertion of the ligamentum teres.

I have a patient in Guy's Hospital at this time, with a fracture of the neck of the thigh-bone, in whom the following circumstances are to be observed:—When placed in the recumbent posture, the limb is one inch and a half shorter than the other; but when he is standing, the injured limb is two inches and a half shorter than the sound limb: the cause of this contrariety is as follows:—When he is recumbent, and the spinous processes of the ilia are in the same line, the shortening is only from the retraction of the thigh-bone; but when he is standing, he throws

the axis of his body into the thigh of the sound limb, to enable him to support himself; and elevating the pelvis, raises the injured limb one inch more than when he is recumbent.

FRACTURES OF THE CERVIX FEMORIS EXTERNAL TO THE CAPSULAR LIGAMENT, AND INTO THE CANCELLI OF THE TROCHANTER MAJOR.

The symptoms of this accident in some respects resemble those of the fracture within the ligament, and they require much attention to distinguish them accurately; but the result is entirely different; so that a favourable opinion may be given as to the restoration of the bone by an ossific union.

Symptoms.

In this accident, the injured leg is shorter than the other by half to three quarters of an inch; the foot and toe on that side are everted, from the loss of support which the body of the thigh-bone sustains in consequence of the fracture; much pain is felt at the hip, and on the inner and upper part of the thigh; and the joint loses its usual roundness.

Diagnostic marks.

The distinguishing signs of this accident are,—First:—It sometimes occurs at the earlier periods of life; for it happens in the young, and in the adult *under fifty years of age*, although I have known it at a later period, when it often proves fatal; but if the above symptoms are seen at any age under fifty years, there will be generally found a fracture external to the capsular ligament, and capable of ossific union. Several of these cases which

Union of the bone.

have fallen under my notice have occurred under that period; and, therefore, a surgeon called to the bed-side of a patient who has an injury to the upper part of the thigh-bone, if he finds the age of the patient to be under fifty years, will, with very few exceptions, be warranted in pronouncing it either a fracture just external to the ligament, or one through the trochanter major. But I also mention that *both fractures occur in age*, and, therefore, no conclusion can be drawn between the two, in advanced age, but by the most careful examination.

From severe injuries.

Secondly:—These cases may be in some measure distinguished by the severity of the accident which produces them; for whilst the internal fracture happens from very slight causes, this, on the contrary, is produced either by severe blows, or falls upon the edge of some projecting body, as against the edge of the curb-stone, or from the pressure of laden carriages passing over the pelvis. My experience has taught me, that a very slight accident generally occasions the fracture within the capsule, and a violent blow, or fall, the other: the first is an accident upon which the fall often succeeds, the other is generally the consequence of that fall; many of those within the capsule which I have witnessed, were produced by the person's slipping from the curb-stone to the road-way,*—not that I mean to deny, that a fall will, and does occasionally, produce a fracture within the capsule, or that in a very old person, a fracture may occasionally happen in any

* Slipping from the curb-stone to the road-way produces a violence in the perpendicular direction; falling against the edge of the curb-stone often produces the fracture external to the capsule.

part of a bone, from a slight cause compared with that which produces it in the young.

Crepitus. Thirdly:—It may be generally known by the crepitus which attends it upon slight motion, for it is unnecessary to draw down the limb, to distinguish the grating of one bone upon the other, and this arises from the less retraction of the limb.

Fourthly:—Great ecchymosis often attends it.

Swelling. Fifthly:—Swelling and tenderness to the touch quickly succeed upon the upper part of the thigh, from the inflammation which this injury produces.

Severe pain. Sixthly:—This accident is generally marked by much greater severity of suffering than the fracture within the ligament, slight motion producing excruciating pain, which does not happen in an equal degree in the fracture within the ligament.

Seventhly:—There is a high degree of irritative fever, and many months elapse before the patient recovers any use of the limb.

Dissection. Upon dissection of these cases, the seat of the fracture is found to vary very much in different examples, being more or less complicated, but it is external to the capsular ligament; and the fracture is placed at the neck of the root of the thigh-bone, the trochanter is split, and the neck of the bone is received into its cleft. The trochanter major is often broken into several portions.

We have few opportunities of dissecting these cases in the young, because they recover from the accident, and, therefore, the examination of them has been most frequently made in aged persons, whom they often destroy. The following cases will explain the appearances on dissection.

Mr. Powell, surgeon, of Great Coram Street, presented me with a valuable preparation, taken from a patient of his who died fifteen months after the accident, and the following is the history of the case.

Fracture of the Neck of the Thigh-bone.

CASE I.

Mary Clements, aged eighty-three and a half years, when walking across her room, October 1st, 1820, supported by her stick, which from the debility consequent upon old age she was obliged to employ, unperceived by herself, placed her stick in a hole of the floor, by which, losing her balance, and tottering to recover herself from falling, which she would have done but for those near her, she found she had, as she supposed, dislocated her thigh-bone. When called to her, she was lying upon her bed, in much pain, with the thigh shortened, and the foot everted. Suspecting the nature of the accident, I directed extension to be made by the foot, which I found was readily brought to correspond with the opposite side; and upon rotating the limb I discovered a crepitus, which fully confirmed me in the opinion that some part of the neck of the femur was broken. With a view to the union of the bone, I first placed the limb in a straight position, making a permanent extension by fixing the pelvis and extending from the ancle; but as the mental faculties were nearly as much shaken as the corporeal, and she could not be induced to keep up the extension required, I was obliged after a few days to change my plan for that of two boards united

together at right angles, over which the thigh was placed, and was supported by pillows kept in their position by lateral pegs. In a very few days this position, in which she at first expressed herself comfortable, became so irksome, that she would no longer submit to it, and I was obliged again to abandon my wish to be decidedly useful to her. From this period she adopted any position that was most comfortable to herself, but generally as the easiest state, lay upon the same side as the accident, with the limb drawn up at nearly right angles with the body. The neighbourhood of the joint, in the early stage of the accident, was kept wet with an evaporating lotion; the regular action of the bowels was elicited by occasional aperients, and she generally took at bed time, for an old chronic cough, an anodyne pill. For some weeks I found that I could extend the limb when I wished, but afterwards I could not accomplish this, I supposed from the permanent contraction of the muscles of the pelvis; this I presumed was more especially the case, as the opposite thigh was bent at the same angle, and was equally immoveable. As she was become perfectly bed-ridden, to which state of imbecility she might be said to be rapidly approaching even before the accident, she had sloughing of the integuments of the parts upon which she lay, but did not suffer other inconvenience. Her general health appeared nearly as good as before the accident; and she ultimately sunk without any symptom of active disease, about fifteen months from the period at which the fracture took place.

Inspection.

The limb was drawn up at right angles with the body, or

nearly so. I removed the os innominatum with the thigh-bone, and presented them to Sir Astley Cooper, and the following is the account of the dissection.

Dissection.

The neck of the thigh-bone had been broken at its junction with the body of the bone, and had been forced into the cancellated structure between the trochanter major and trochanter minor, where it had been united with the cancelli. But the most curious circumstance in this dissection was, that in order to give the support which the body required for a limb in such a state, an addition had been made both to the trochanter major and the trochanter minor, by which means they rested against the edge of the acetabulum, and in every slight change of position, would give an opportunity for the weight of the body to be supported by these processes resting on the os innominatum. (*See plate.*)

JAMES POWELL.

My friend, Mr. Roux, sent me from Paris a fractured thigh-bone, in which the neck of the bone had been broken at the same part as in Mr. Powell's case, and had been united in a similar manner. But it frequently happens in this injury, that the fracture of the neck of the thigh-bone is complicated with an injury of the trochanter major and trochanter minor.

CASE II.

Mr. Wray, surgeon, in Fleet Street, was so kind as to present me with a fracture of this description, and the following are the particulars of the case :—

A man, aged sixty-four, was standing by his bed-side, when he suddenly fell to the ground, as it was supposed in a fit, and on the attempt to raise him, he was found unable to stand. Mr. Wray was called to him, and he found his right leg somewhat shorter than the other, and the limb everted. Motion of the limb gave him excessive pain; no crepitus could be perceived in the examination which he would permit Mr. Wray to make. The limb was placed in a straight position, and a constitutional treatment was pursued, but a high degree of irritative fever succeeded, and on the fourth day from the accident the man died. Upon examination of the body, great extravasation of blood was found both externally to the muscles and between them; suppuration had commenced near the trochanter major, and a fracture was found at the neck of the thigh-bone and into the trochanter, by which the neck had been received into the cancellated structure of the shaft of the bone.

Mr. Travers has a most valuable specimen of this fracture, which occurred in a patient of his at St. Thomas's Hospital, and of which he has had the kindness to give me the following account.

CASE III.

Richard Norton, aged sixty, fell upon the curb-stone of the foot-pavement, and struck the upper and outer part of his left

thigh with great violence. He was admitted into St. Thomas's Hospital, on the 24th of January, 1818. The tension was then considerable; the line of the tensor vaginæ femoris formed an arch; the limb was shortened; the foot inclined outwards; the motion of the limb was free in all directions; but it was painful, more especially when the knee was carried over the opposite thigh. The crepitus of the trochanter major was distinctly felt in these motions, and the swelling of the parts, with the extensive crepitus, gave an idea that the accident was a comminuted state of the trochanter, and that the base of the cervix femoris was broken; hence the shortening of the leg, and the eversion of the foot. After the use of evaporating lotions for some days, the tension subsided, so as to allow the application of the long outer splint and two thigh-splints well bedded. On March the 4th, the splints were removed, and union appeared to have taken place, for the limb had resumed its natural figure, but was a little shorter than the other. In the course of a month more he began to use his crutches. On April the 15th, he was placed under the physician for defect in his general health; and when he was upon the point of quitting the hospital, he was seized with spasms in his chest, of which he suddenly expired.

Upon examination, some old adhesions of the pleura, and water in the chest, and pericardium, were found. The fracture was through the trochanter, as had been supposed, extending some way down the bone, and it apparently had united, with very slight deformity; but on maceration, the head and neck of the bone became loose in the thigh-bone, and a fracture was found

there, which locked the head and cervix in a shell of bone formed around them.

B. Travers.

Mr. Travers having sent me the bone, the following are the appearances of this curious case. The head and cervix had been separated from the trochanter major and body of the bone. The upper part of the thigh-bone was obliquely split, so as to receive the cervix femoris into the cancelli. This fracture of the thigh-bone separated the posterior portion of the trochanter major from the body of the thigh-bone, and the trochanter minor was removed with it. An union had taken place between the fractured portions of the trochanter, at a slight distance from each other, and thus a hollow was left, into which the cervix femoris was received, and it had not yet become united by ossific deposit, as the man had not lived sufficiently long for firm consolidation under his reduced state; for upon maceration, the neck of the bone had free play in the cavity in which it had been received, and from which it could not be removed.

Mr. Oldnow, of Nottingham, who is a very intelligent surgeon, sent me two very excellent specimens of this fracture, in which the necks of the bones were broken at their junction with the trochanter major. The trochanter major itself had been also broken off, and the trochanter minor formed a distinct fracture. The bones had become re-united; the cervix femoris to the shaft of the bone, and the trochanter minor a little higher than its natural attachment. The trochanter major was in one specimen re-united to the body of the bone, but not in the other. Thus

the thigh-bone was at its upper part divided into four portions; the head and neck of the bone formed one portion; the trochanter major a second; the trochanter minor a third; and the body of the bone the fourth. The union was accompanied by very little shortening of the thigh. *(See plate.)*

Since the publication of the former edition of this work, I have inspected, with Mr. Key, a fracture of the neck of the thigh-bone. The moment I had examined the patient, I pronounced the case to be a fracture external to the capsule, and was led to believe so from some little diminution in the length of the limb; from the ecchymosis which attended it; from its distinct crepitus without any rotation; from the diminished motion of the upper part of the thigh; from the sunken state of the trochanter; and from excitement of great pain by the smallest motion. This man died in a fortnight after the accident.

When the body was placed upon the table for examination, *post mortem*, all the limbs were rigid from the fixed contraction of the muscles, and, consequently, the thigh was drawn up to its greatest possible extent; yet the limb was found to be not quite three quarters of an inch shorter than the other. The posterior part of the sheath of the vessels, and some branches of blood-vessels, were torn by the bone, which accounted for the ecchymosis. The neck of the bone was forced into the cancelli of the trochanter major.

Before writing this statement, I again inquired of Mr. Key, the degree of diminution in the length of the limb, and his answer was, "If you mention three quarters of an inch, you will state rather more than its degree of retraction, even when all the

muscles were contracted to their utmost rigidity." I shall be happy to shew the parts which I removed from the case, with all the surrounding muscles, to any person who wishes to see them, as they at once explain the nature of the accident, and the reason why the limb is so little shortened.

Although, then, this accident has some of the marks of fracture of the neck of the bone within the ligament, yet it unites by bone, and it will be seen that the union is similar to that of other bones external to the joints; cartilage is first deposited, and then the matter of bone, because in this case the parts can be brought into apposition, and the ends of the bones are confined together by the surrounding muscles; one portion is pressed against the other, and the neck of the bone sinks deeply into the cancellated structure of the trochanter; thus direct approximation and pressure are preserved when the fracture is at the junction of the cervix with the trochanter, and the nutrition of each extremity of the bone is well supported by the vessels which proceed to it from the surrounding parts.

Difference of opinion reconciled.

We now see the reason of the difference of opinion respecting the union of fracture of the neck of the thigh-bone. In the internal fracture the bones are not applied to each other, and the nutrition of the head of the bone being imperfect, in general no ossific change is produced; but in the external fracture the bones are held together by the surrounding parts, easily kept in apposition by external pressure, and there is not only ossific union, but very exuberant callus. Much time is required in these accidents to produce a complete ossific union; and the neck of the bone, received into the cancelli, moves for a long period in

its new situation; although it is so far locked in as to prevent its separation.

In the treatment of this injury, the principle is to keep the bones in approximation by pressing the trochanter towards the acetabulum; and the length of the limb is preserved by applying a roller around the foot of the injured leg, and by binding the feet and the ancles firmly together, so as to prevent their retraction, and thus cause the uninjured side to serve as the splint to that which is fractured, giving it a continued support. A broad leathern strap should also be buckled around the pelvis, including the trochanter major, to press the fractured portions of the bone firmly together, and the best position for the limb is, to keep it in a straight line with the body. Treatment.

The following plan I have also known successful:—The patient being placed on a mattress on his back, the thigh is to be brought over a double inclined plane composed of three boards, one below, which is to reach from the tuberosity of the ischium to the patient's heel, and the two others having a joint in the middle by which the knee may be raised or depressed; a few holes should be made in the board, admitting a peg, which prevents any change in the elevation of the limb but that which the surgeon directs; over these a pillow must be thrown, to place the patient in as easy a position as possible.* *(See plate.)*

When the limb has been thus extended, a long splint is placed upon the outer side of the thigh to reach above the trochanter

* The construction of this inclined plane is so little complicated, that it may be made at the instant of two common boards, one of which is to be sawn through nearly at the middle, and if hinges cannot be immediately procured, the boards may be nailed together thus  .

major, and to the upper part of this is fixed a strong leathern strap, which buckles around the pelvis, so as to press one portion of bone upon the other; and the lower part of the splint is fixed with a strap around the knee to prevent its position from being altered; the limb must be kept as steady as possible for many weeks, and the patient may be permitted to rise from his bed when the attempt does not give him much pain; he is still to retain the strap which I have mentioned round the pelvis; and by this treatment he will ultimately recover with an useful, though shortened limb.

Recovery.

FRACTURES THROUGH THE TROCHANTER MAJOR.

Oblique fractures sometimes happen through the trochanter major, and the cervix ossis femoris does not participate in the injury. This accident occurs at every period of life, and its symptoms are as follows:—the leg is very little, and sometimes not at all, shorter than the other, and the foot is benumbed; in some cases the patient is unable to turn in bed without assistance, and the attempt gives him great pain. The broken portion of the trochanter major is, in some cases, drawn forward towards the ilium; in others, it falls towards the tuberosity of the ischium; but is, in general, widely separated from that portion which remains connected with the neck of the bone. The foot is greatly everted; the patient cannot sit, and any attempt to do so produces excessive pain. Crepitus is with difficulty discovered if the trochanter is either much fallen, or much drawn forwards.

The distinguishing marks of this accident are, a fixed state of the upper part of the trochanter, whilst its lower part obeys the motion of the thigh-bone; eversion of the foot, and the very perceptible altered position of the trochanter major; attended with crepitus under very extended motion of the upper part of the limb, and with little diminution of its length.

But when the fracture happens below the insertion of the principal rotatory muscles, the lower portion of bone is much raised by the action of the gluteus maximus, and the limb becomes very much shortened and deformed at the place of union by exuberant callus.

This fracture unites very firmly, and more quickly than when the cervix is broken at the root of the trochanter, and the patient recovers with a very good use of the limb.

The first case of this kind I ever saw was in St. Thomas's Hospital, about the year 1786. It was supposed to be a fracture of the neck of the thigh-bone within the capsule, and the limb was extended over a pillow rolled under the knee, with splints on each side of the limb, by Mr. Cline's direction. An ossific union succeeded, with scarcely any deformity, excepting that the foot was somewhat everted, and the man walked extremely well. When he was to be discharged from the hospital, a fever attacked him, of which he died; and upon dissection, the fracture was found through the trochanter major, and the bone was united with very little deformity, so that his limb would have been equally useful as before.

The following case I attended with Mr. Harris, surgeon, at

Reading, who has been so kind as to communicate the circumstances in detail.

CASE.

On Friday, July 20th, 1821, I was sent for to Mr. B——, a gentleman, living about six miles from Reading, who, I understood from the servant, had met with an accident, and put out his hip. I found him placed on a board in his bed-room, and on inquiry learnt that his horse had fallen with him when putting him into a trot, and he was thrown, and fell on his left hip on the road. He immediately got on his legs, and walked a few steps, but soon found an inability to bring his left leg forward, and complained of pain in his left hip. He was placed in a cart, and supporting his left leg by taking the stirrup and placing his foot in it, holding it steady by the leather, he was conveyed home, a distance of about four miles. I reached him within two hours of the accident, and on examining the limb, I immediately perceived that there was not a dislocation.

I could not discover any crepitus in rotating the limb; it was of the same length as the other, and neither turned inwards or outwards; and he had the power of retaining it in any position in which you chose to place it. The integuments in the neighbourhood of the trochanter major were a good deal swollen; and he complained of pain, but could bear the limb moved in any direction, without much, or, indeed, any inconvenience, except when drawn across the other, and then great pain was felt in the situation of the trochanter minor. I then gave it as my opinion, that there was neither dislocation nor fracture, and I thought he would be well in a few days. I directed some leeches

to be applied over the trochanter major, and an evaporating lotion, and took about twelve ounces of blood from the arm; and as he was in the habit of taking the pil: hydrarg: I directed him to take a pill at bed-time, and some Cheltenham salts in the morning.

I should observe, that in making my examination, I discovered that Mr. B—— had formerly experienced a fracture of the patella of the right knee, which had united by a ligament of near two inches in length; and on inquiry I learnt, that it had been fractured three times—in 1795, 1796, and 1800. He is of tall stature, and rather thin; and at the time of the present accident was in the fifty-first year of his age.

On seeing Mr. B—— the next day, the 21st, I found he had had no sleep, and was totally unable to move the limb without assistance; his medicine had operated. On the 22nd there was no improvement in the powers of the limb; the part was still much swollen, although the leeches had drawn a considerable quantity of blood. As there was a disposition to inflammation from the bite of the leeches, I ordered a poultice of linseed meal and bread crumbs, which removed it in a day or two. Mr. B—— informed me, that Mr. Ring, of Reading, had called on him, and had examined the limb very minutely, and measured it and found it to correspond in length with the other; and then told him that he was happy to confirm Mr. Harris's opinion of the case.

On the 26th, Mr. B—— was attacked with an acute hepatitis, which very nearly proved fatal. From that time to the 28th, he was bled four times from the arm, to the extent of ninety-six ounces of blood, and took a saline purgative draught and calomel;

during this period the limb remained in much the same state. Dr. Taylor saw him about this time. The limb was moved daily, and I began to think it did not improve so much as it ought; as it appeared at first to be only a simple contusion, and the antiphlogistic treatment pursued for the cure of the hepatitis should also, we thought, have benefited the limb.

On August the 14th, whilst Mr. Ring was moving the leg, he thought he felt a crepitus, which he communicated to me, and I remarked that it was impossible. I did not move the limb on that day, but on the following I rotated it, and distinctly felt and heard the crepitus. Mr. B—— also heard it, and said, "Why, you do not mean to find a fracture now?" I expressed my fears that there was a fracture, but could not say where, but thought it was through the cervix of the femur; although every symptom, saving the crepitus, was wanting to such an accident. I communicated my opinion to Mrs. B——, and it was immediately arranged for Mr. Brodie to be sent for, who came the following day at noon (the 18th), and met Dr. Taylor, Mr. Ring, and myself. The particulars of the case were communicated to him, and he proceeded to examine the limb, moving it in every direction; but could not then discover a crepitus, or any symptom denoting a fracture, as the limb was still of the same length with the other, and neither turned inwards or outwards. Mr. Brodie was in the first instance doubtful as to there being a fracture. We told him that we both (that is, Mr. Ring and myself), had distinctly felt the crepitus, and that it was not discoverable but on certain motions of the limb. Mr. Brodie then examined the limb with the greatest attention, and in rotating it very extensively he

felt the crepitus. Yet when the patient was standing upright out of bed, supported, and with the right leg elevated from the ground, he bore very considerably on the injured limb, so much so as to produce from Mr. Brodie an exclamation of surprise; and he gave it as his opinion, that such was the obscurity of the case, that had he seen it a week before, he should decidedly have said that there was not a fracture, as in fact every symptom at that time was completely wanting, except the inability to move the limb; but now he believed a fracture existed in the cervix femoris, or in the superior part of the thigh-bone, where the cervix joins it.

The treatment recommended by Mr. Brodie was, a long splint placed on the outside of the limb, and a bandage from the toes to the hip, which he applied himself, and he ordered it to be worn for one month, and that the limb should be kept entirely free from motion.

At the expiration of a month Sir A. Cooper was sent for, who arrived at E—— on September the 11th. After the accident had been stated to him, he proceeded to examine the limb; he first observed the relative position of the two limbs (Mr. B—— still lying on his back, with the limb resting on the heel), and then passing his hand under the trochanter major, he raised it easily, it having now dropped from its natural position; and he agreed with Mr. Brodie and ourselves in declaring the fracture to be placed in the trochanter major, where it unites with the cervix femoris.

The treatment Sir A. Cooper recommended was, to keep the trochanter in its proper position; the patient to remain in the horizontal posture; and the most perfect quiet to be observed.

The plan adopted to accomplish these objects were the following:

A mattress was made of horse-hair about five inches thick, and very smooth, and this was covered with a sheet. A part of the mattress was made to draw out on the opposite side to the fracture, so that when the necessary evacuations took place, there still should be no motion of the body. Before drawing out the piece of mattress, a board of two feet long, and six inches wide, shaped like a wedge, was insinuated under the buttock of the right side, the two ends of the board resting on the mattress; thereby preventing the nates from sinking at all into the opening when the piece of mattress was removed, and the injured side still rested on the body of the mattress: the board was of course removed after the mattress was replaced. Upon the bedstead was first placed a thick smooth board, sufficiently large to cover the bottom of the bed, and on that was placed the mattress, thereby preventing any sinking by the weight of the body.

The bandage recommended by Sir A. C. was the following: a broad web, sufficient to go round the body over the hips, was fixed with two buckles and straps, and a piece was added to make it wider where it passed under the injured trochanter; this was lined with chamoise leather, and stuffed: a pad of the same leather, which was about six inches long, three broad, and three inches thick, and ending gradually in a point, was placed immediately under the trochanter major of the injured side, so that when the bandage was buckled, the pad passed into the hollow beneath the trochanter, and when the bandage was tightened, it forced the trochanter upwards and forwards into its natural position: then

another pad was made very thick, about eight inches square, in the shape of a wedge, and this was placed under the upper part of the thigh, after the bandage was fixed on. The patient was placed on his back, the limb resting on the heel; and to prevent the possibility of any motion of the foot and of the body, a wide board was fixed to the bed-posts at the foot of the bed, with two pieces of wood padded and fastened to it, into which the foot was received, and the least lateral motion prevented. A cushion was placed opposite the other foot, so that pressure could be made against the board, thereby preventing the body from slipping down in the bed.

Sir A. C. gave directions that Mr. B—— should not quit the horizontal posture; and ordered him occasional purges, and a generous diet. This treatment was adopted on September the 13th, and he passed a tolerable night, and did not complain of the bandage. Nothing particular occurred during the month, except that the patient suffered occasionally from bilious head ache and vomiting, which were removed by purging. The bandage was tightened every now and then, but not to any great degree till the expiration of three weeks, when Mr. B—— told me he was certain that he still felt the crepitus, when I urged the absolute necessity there was of tightening the bandage, and thus, by pressure, to produce a degree of inflammatory action in the bone.

I should judge that when Sir A. C. saw Mr. B——, the ends of the bone were as much as two inches apart, but that was most certainly not the case when Mr. Brodie examined the limb; the separation had taken place during the last month.

From this time the bandage was kept as tight as it could

possibly be borne (and it never shifted in the least from the position in which it was first placed), and no feeling of crepitus was afterwards complained of. The swelling of the thigh and leg was much increased, as if distended with coagulable lymph; it pitted on pressure, but it required some degree of force to produce that effect. Pain was still complained of in the direction of the trochanter minor; the bowels were torpid, and required opening medicines every other day.

Sir A. C. visited Mr. B—— a second time, October 16th; the bandage was not removed, nor was the position changed. He gave it as his opinion that union had begun, and directed the patient to continue in the same position, which he did, without any thing material occurring except bilious attacks, till December the 30th, when Sir A. C. visited him a fourth time: he had seen him in the interval between October the 16th and December the 30th, but nothing particular had occurred.

December the 30th, Sir A. C. removed the bandages for two hours; the bone remained in its natural position; and on examination we could feel a great thickening of the parts about the trochanter. He ordered him to stand at the side of the bed after the bandage had been removed, and he stood with support a few minutes, when he became faint, and was removed to his bed. Sir A. C. wished the bandage to be replaced; but to be re-applied once a day for an hour, and the limb to be rubbed from the foot upwards. The thigh became much softer during the two hours in which the bandage was removed; the boards which supported the foot were now also removed, as well as the bandages, and Mr. B—— was placed on crutches. From this time he rose every

day; and the limb continuing very much swollen, it was rubbed daily from two to four hours; still he could not bend the knee; but when standing on his crutches he had a most perfect use of the hip-joint. We endeavoured to regain the motion of the knee by friction with oily embrocations. On Friday, March 1st, Mr. B—— left E—— in his carriage for London.

SAMUEL HARRIS.

Since his arrival in London, Mr. B—— has, with great steadiness, employed friction and passive motion for the recovery of the use of the knee with the happiest effect, and the hip-joint is entirely restored to its natural powers.

A. C.

CASE.

Mr. Peggler, of Wanstead, aged forty-six, on the 13th of November, 1817, fell, while walking, on a glass bottle which he had in his pocket; and when he attempted to raise himself from the ground he found he was not able to stand. In a quarter of an hour he felt great pain, and could not bear the slightest weight of his body on the injured limb. Mr. Constable, of Woodford, was sent for, and he gave me the following account of the case. The foot, at first, did not appear to turn out; but when the patient was put into bed, and laid on his back, it became everted: the leg appeared somewhat shorter, but was with little difficulty pulled down to its natural length: the foot was benumbed, and continued so for twelve months. He was placed in bed, with a bolster under the hip to prevent displacement of the bone; and his knees and ancles were tied together.

In December following, about Christmas, I met Mr. Constable, whilst visiting a patient with a severe injury of the head, and he then requested me to see Mr. Peggler, whom I found incapable of turning in his bed without assistance, and the attempt gave him great pain; his injured leg was a little shorter than the other, and the trochanter was drawn forward towards the spine of the ilium, and could be felt considerably separated from that portion of the trochanter connected with the neck of the bone; the foot was turned outwards; he could not sit, and the least attempt to raise himself produced excruciating suffering. I brought him to the foot of the bed in an horizontal position, to make as accurate an examination as I could of the nature of the accident, and had no hesitation in pronouncing it a fracture through the trochanter. In less than a month he began to use his crutches, and continued their use for three months; he then laid aside one crutch, and employed a stick and crutch, and in a short time needed the support of a stick only; but it was twelve months before he recovered the entire use of his limb. The leg is still nearly an inch shorter than the other; the portion of the trochanter connected with the thigh-bone has united with the fore part of the trochanter joined to the neck of bone, and is, consequently, much nearer the spine of the ilium than usual; the foot is also slightly everted, but he walks extremely well; a week ago he walked ten miles from home, and returned the same day; and this day, July 28th, 1819, he has walked from Wanstead to my house, and intends to walk back, a distance of near twenty miles.

This history of Mr. Peggler's accident is so similar to the cases

of fracture through the trochanter major which I have had an opportunity of seeing, that a detail of the latter would only become an useless repetition; the only variations that I have witnessed having been in the distinctness of the crepitus accompanying them, which is less in proportion as the fracture approaches the capsular ligament. I have lately fractured through the trochanter major, five different thigh-bones in the living animal; they united, but with great distention, shortening, and exuberant callus.

To conclude.—As diminution of the length of the limb, and its eversion of the knee and foot, are signs which are common to fractures of the thigh-bone generally, it may be proper, before quitting the subject, to bring into one view the means of distinguishing the three species of fracture which I have described.

The fracture of the cervix within the capsule is known, with very rare exceptions, by the very advanced age of the patient,—by its greater frequency in female than in male subjects,—by the absence of swelling and ecchymosis,—by the elevation and advance of the trochanter,—by the greater mobility of the joint, allowing flexion and extension, although with some pain, and resistance from muscles,—by a crepitus perceptible only on drawing down the limb to the same length with the other, and then rotating it,—by the pain felt at the trochanter minor,—by little constitutional irritation attending the accident,—by the slight causes which produce it,—and by the little local swelling or change of appearance which ensues.

Fractures of the cervix into the cancelli of the trochanter are known by the effusion of blood amidst the muscles,—by great

swelling produced, and by ecchymosis, which appears soon after the accident,—by an unnaturally fixed state of the joint, so that flexion and extension cannot be performed,—by excessive pain being produced on the least motion of the hip-joint, and upper part of the thigh-bone,—by a crepitus being perceived under the least motion of the thigh-bone, without drawing it down to the length of the other,—and by the inflammation, swelling, and constitutional irritation produced, which are frequently destructive.

The fracture of the trochanter major may be easily known by the separation of the bone at the part, so that the finger may be placed between the fractured portions,—by the distinct crepitus felt in putting the fingers on the trochanter when the knee is advanced,—by the upper portion of the trochanter not obeying the motions of the lower, and of the shaft of the bone,—and when at the lower part of the trochanter, by great overlapping, distention, and exuberant callus.

I have thus stated what dissection and observation have taught me of the three fractures of the upper part of the thigh-bone, and shewn it to be a general principle, that fractures within the capsule do not unite by bone. I ought to add, that, in the Museum of Mr. Langstaff, there is a preparation of fracture within, and of one external to the ligament; the latter firmly united by bone, whilst the former has scarcely undergone any ossific change. I can have no wish but that these fractures within the capsule should unite by bone, if that result be desirable. I only state what dissection has taught me; and, with respect to contrivances to produce their union, I cannot extol them until there be some evidence of their value.

FRACTURE OF THE EPIPHYSIS OF THE TROCHANTER MAJOR.

Mr. C. Aston Key, Surgeon to Guy's Hospital, has had the kindness to send me the following account of a peculiar fracture of the trochanter major, in which this process was broken from the thigh-bone at the part at which it is naturally united by cartilage as an epiphysis in youth.

CASE.

The subject of the accident was a young girl about the age of sixteen, who, in crossing the street with a can in her hand, tripped, and in falling, struck her trochanter violently against the curb stone. She immediately rose, and without much pain or difficulty walked home. The accident occurred on Saturday, March 15th, 1822; and, in consequence of the increase of pain she experienced on the inner side of the thigh, she presented herself at Guy's for admission on the Thursday following. Her constitutional symptoms being evidently more violent than those which usually arise from fractured femur, she was placed under the care of the physician, Dr. Bright, at whose request I examined the limb. Her right leg, which was the one injured, was considerably everted, and appeared to be about half an inch longer than the sound limb. It admitted of passive motion in all directions, but in abduction gave her considerable pain. She had perfect command over all the muscles except the rotators inwards. The fact that she had walked both before and since her admission

into the hospital, gave rise to some doubts as to the existence of a fracture, and the closest examination of the trochanter and body of the femur could not detect the slightest crepitus or displacement of bone. I repeated the examination of the limb on the following day, but the result was equally unsatisfactory.

The fever under which she was labouring, together with general abdominal uneasiness, threatening her life, the limb underwent no further examination. She died on Monday, nine days after the accident.

Examination after death.

Wishing to ascertain (for I suspected some obscure fracture of the os femoris) the exact nature of the injury, previously to removing the soft parts I moved the limb in every direction, fixing the trochanter and head of the bone; but I could perceive no deviation from the usual state of parts, nor could I distinguish the slightest crepitus under all the variety of movements. I should observe, that there was no tumefaction of the thigh, and therefore the trochanter and head of the os femoris were as readily distinguished and exposed to examination as in the most healthy limb.

The capsule of the joint being laid bare, a cavity was discovered by the side of the pectineus, leading backwards and downwards, towards the trochanter minor, and containing some pus: it allowed the fingers to pass behind the bone to the greater trochanter. The head of the bone was then dislocated by cutting through the ligaments, and not till then was a fracture discovered at the root of the trochanter major. The upper half of the femur being removed from the body, I discovered the reason why the fracture had eluded our search.

The fracture had detached the trochanter from the body and neck of the bone, but without tearing through the tendons attached to the outer side of the process. The tendons are those of the two smaller glutæi, and the commencement of that of the vastus externus; had they been torn, the broken portion of bone would have been drawn upwards by the action of the two former muscles, and, in that case, the injury would readily have been recognized; but they so effectually prevented all motion of the fractured portion that, when dissected from the body, not the least motion could be produced except in one direction. It was found that this motion resembled that which would be produced by a hinge; the tendons acting the part of a broad hinge, and allowing the portion to be moved only upwards and downwards. It is evident that such motion could not have been produced by any direction given to the limb; hence it is also manifest that the fracture could not have been detected during the life of the patient. C. A. Key.

FRACTURES BELOW THE TROCHANTER.

The thigh-bone is sometimes broken just below the trochanter major and minor; it is a difficult accident to manage, and miserable distortion is the consequence if it be ill treated. The end of the broken bone is drawn forwards and upwards, so as to form nearly a right angle with the body, and the cause of this position is evidently the contraction of the iliacus internus

and psoas muscles, assisted by the pectinalis, and perhaps by the first head of the triceps. A better idea of the effect of this accident may be obtained by a view of the plate, in which the bone will be observed to be united, not only with extreme shortening, but with a hideous projection forwards. If pressure be made upon the projecting bone in the treatment of this case, it only adds to the patient's suffering, and to the degree of irritation of the limb, without preserving the bone in its proper situation. It will be seen that this union exceedingly overlaps, and that it is very feeble; shewing, what I have already mentioned, that a fracture thus circumstanced has the ossific deposition only on that side where the inflammation was preserved by the pressure of one bone on the other. This preparation may be seen in the Anatomical Museum, St. Thomas's Hospital. *(See plate.)*

To prevent this horrid distortion and imperfect union, two circumstances are to be strictly observed: the one is, to elevate the knee very much over the double inclined plane; and, the other, to place the patient in a sitting position, supporting him by pillows during the process of union. The degree of elevation of the body which is required will be about forty-five degrees, but it may be readily ascertained by observing the approximation of the fractured extremities of the bones; and this position is demanded to relax the psoas and iliacus muscles, and thus prevent the elevation of the upper part of the bone. In this manner, and thus only, can the great deformity I have described be prevented. When, by this posture, the extremities of the

bones are brought into proper apposition, and all projection of its upper portion is removed, either the splints may be applied which are commonly used in fracture of the thigh-bone, or, what is better, a strong leathern belt, lined with some soft material, should, by means of several straps, be buckled around the limb, and be confined by means of a strap around the pelvis.

DISLOCATIONS OF THE KNEE.

THE broad surfaces of bone by which the os femoris rests upon the tibia are calculated to prevent the ready dislocation of this joint, which would be otherwise very liable to happen from the superficial nature of the articulating cavities on the head of the tibia, and also from the great violence to which this joint is frequently exposed.

Structure of the knee.

The depressions upon the head of the tibia are increased by the addition of the semi-lunar cartilages which rest upon the bone; they receive the condyles of the os femoris, and are attached by ligaments to the edge of the tibia. The fore part of the joint

Bone.

is defended by the patella, which has two unequal articular surfaces to play upon the condyles of the os femoris. The head of the fibula forms no part of the knee-joint, but is attached to the tibia from one half to three-fourths of an inch below its head.

The junction of the os femoris, tibia, and patella, is produced

Ligaments.

by means of a capsular ligament, which proceeds from the os

femoris to the head of the tibia, and is attached to the edge of the patella, where it divides into two portions, forms wings to that bone, and takes the name of the alar ligament. On its outer side the capsular ligament is covered, and greatly strengthened, by tendinous expansions, which are derived from the vasti muscles, and which proceed to the head of the tibia. Internally the ligament has a secreting synovial surface, which is folded within the cavities at the extremities of the bones, and is reflected to the edge of the articular cartilages, and, it is believed, forms a covering to those cartilages. Beside the capsular, there are several peculiar ligaments. First: The ligamentum patellæ, which is extended from the lower point of the patella to the tubercle of the tibia. Secondly: The external lateral or femoro-fibular ligament, which passes from the os femoris to the head of the fibula, and which divides into two external lateral ligaments. Thirdly: The internal lateral or femoro-tibial ligament, being attached to the os fomoris and to the head of the tibia. Fourthly: The oblique or popliteal ligament, which proceeds from the external condyle of the os femoris obliquely, to be inserted into the head of the tibia. Fifthly: The crucial ligaments, which pass from the depression between the condyles of the os femoris behind; the one to a projection between the articular surfaces of the head of the tibia, and the other to a depression behind that projection, so that these ligaments cross each other from before backwards. The patella has a muscular connection with the os femoris by the insertion of the rectus, vasti, and cruralis. By the ligamentum patellæ it is united with the tibia, and laterally it is joined to the capsular and

alar ligaments. This ligamentous junction of the three bones is very firm, but it allows of free flexion and extension, with some degree of rotatory motion when the knee is bent; but although great strength is evident in the construction of this joint, still excessive violence and extreme relaxation will occasionally produce its dislocation.

DISLOCATION OF THE PATELLA.

Three directions.

The patella is liable to be dislocated in three directions, namely: outwards, inwards, and upwards. In its lateral dislocation, the bone is most frequently thrown on the external condyle of the

Symptoms.

os femoris, where it produces a great projection; and this circumstance, with an incapacity of bending the knee, is the strong

Cause.

evidence of the nature of the injury. The most frequent cause of the accident is, that a person in walking or running, falls with his knee turned inwards, and the foot outwards; and thus, by the action of the muscles to prevent the fall, the patella is drawn over

External.

the external condyle of the os femoris; and when the person attempts to rise he finds himself unable to bend his leg, and the muscles and ligaments of the patella are all forcibly on the stretch. This accident generally occurs in those who have some inclination of the knee inwards, which, under the action of the extensor muscles, gives a direction to the patella outwards.

Internal.

The internal dislocation is much less frequent, and it happens from falls upon a projecting body, by which the patella is struck

upon its outer side, or by the foot being, at the time of the fall, turned inwards. In either of these cases the ligament will be torn, unless there be some previous disease.

Mr. Harris, getting into a chaise, caught his foot in the carpet at the bottom of it, by which accident the knee was turned in and the leg outwards; the patella slipped upon the external condyle of the os femoris, but it returned very soon, by the effort of the muscles, into its natural situation. On examination, I found the internal portion of the capsular ligament torn, and a great accumulation of synovia in the joint.

Mode of reduction.

The mode of reduction in either case consists in pursuing the following plan: The patient is placed in a recumbent posture, and an assistant raises the leg by lifting it at the heel; the advantage of which is, that it relaxes the extensor muscles on the thigh in the greatest possible degree; the surgeon then presses down that edge of the patella which is most remote from the joint, be it one luxation or the other; and this pressure raises the inner edge of the bone over the condyle of the os femoris, and it is immediately drawn, by the action of the muscles, into its natural situation.

My friend, Mr. George Young, informed me, that he was called to a case of dislocation of the patella outwards, in which the reduction was very difficult. The patient was a female, who, by a fall in walking, had the patella drawn over the external condyle of the os femoris, where it remained. He employed pressure upon the edge of the patella, most perseveringly, without being able to succeed, but at last reduced it in the

following manner:—he placed the patient's ancle upon his shoulder, and thus most completely extended the limb and obtained a fixed point of resistance at the knee; then grasping the patella with the fingers of his right hand, he pressed the outer edge of the patella with the ball of his left thumb, and pushed it into its place.

When the reduction of this bone has been effected, an evaporating lotion of spirits of wine and water is to be applied; in two or three days the limb may be bandaged, and it is soon restored to its natural uses, although it is somewhat weaker than before.

I was informed by Mr. Welling, formerly surgeon at Hastings, that he was called to a case in which the patella was dislocated upon its edge. The nature of the accident was very obvious, as the edge of the bone forced up the integuments to a considerable height between the condyles on the fore part of the joint. Mr. Welling reduced the dislocation, but with considerable difficulty, by pressing the edges of the bone in opposite directions.

Dislocation from relaxation.

When the bone is dislocated from relaxation, the patella is drawn upon the external condyle of the os femoris by very slight accidents, or sudden action of the muscles. My neighbour, Mr. Hutchinson, a very intelligent surgeon, informs me he has very frequently seen this accident, and that the tendency to it has arisen, in a large proportion of cases, from the relaxation produced by excessive indulgence in onanism.

The reduction, in these cases, is effected in the manner which has been before described; and after the reduction, to prevent

any recurrence of the accident, and to support the weakened ligament, a laced knee-cap, with a strap and buckle above and below the patella, is to be worn.

I once saw the patella drawn over the external condyle of the os femoris from loss of action of the vastus internus, owing to a disease in the thigh-bone.

DISLOCATION OF THE PATELLA UPWARDS.

Upwards.

In this dislocation, the ligament of the patella is torn through by the action of the rectus femoris muscle, and the immediate effect of the injury is, to draw the patella upwards upon the fore part of the thigh-bone. The appearances which this accident presents are very decisive of the nature of the injury; for, beside the elevation of the patella, and its easy motion from side to side, a deep depression is felt above the tubercle of the tibia from the absence of the ligament; the patient immediately loses the power of bearing upon that limb, as the knee bends under each attempt, and he would fall if he persisted in throwing the weight of his body upon it. A considerable degree of inflammation follows this accident.

Ligament lacerated.

Symptoms.

Treatment.

In the treatment of this injury, local depletion and evaporating lotions are to be used during four or seven days from the accident, and then a roller is to be applied around the foot and upon the leg, to prevent its swelling; the leg is to be kept extended by a splint behind the knee, and a bandage, composed of a leathern strap, is to be buckled around the lower part of the thigh; to

this is to be attached another, which is to be carried on each side of the leg, and under the foot, and is to be buckled to the circular strap; thus the bone is gradually drawn down, so as to allow of an union of the ligament. In a month the knee may be slightly bent, and as much passive motion daily given as the patient is able to bear; by these means the ruptured ligament becomes united, and the patella retains its motion. During the time the bandage is worn, the patient is to preserve the sitting posture, in order to relax the rectus muscle and to prevent its action upon the patella. With very great attention the union becomes perfect; for so it happened in a case which I saw with Mr. Burrowes, in Bishopsgate-street. Mr. B. paid great attention to the case, and the patient recovered without any diminution of the natural powers of the part; the patella being gradually forced down until the ends of the ligament had approximated and coalesced.

Dislocation downwards.

With respect to dislocation of the patella *downwards*, at which some surgeons have hinted, I have seen no injury which deserved such a title, if I except a rupture of the tendon of the rectus, which I have twice witnessed, and which destroyed the attachment of that muscle to the patella. The appearance of this injury was a soft swelling above the patella, upon which, when the hand was placed, it sunk into the joint; the patella fell loose between the condyles of the os femoris and the head of the tibia, but it still retained very much its usual situation, and could not be said to be luxated, as it was not displaced from the joint. The treatment which this accident requires is, that the patient be obliged to preserve a sitting posture during

the cure; and that a cushion be applied upon the ligamentum patellæ, which is to be confined by a roller passed around the head of the tibia.

DISLOCATION OF THE TIBIA AT THE KNEE-JOINT.

These dislocations occur in four different directions; but two of them are incomplete, and lateral, while the others are perfect luxations, the tibia being thrown either backwards or forwards. In four directions.

The lateral dislocations are but rare. In the dislocation inwards the tibia is thrown from its situation, so that the condyle of the os femoris rests upon the external semilunar cartilage, and the tibia projects on the inner side of the joint, so as at once to disclose the nature of the injury. The first case of this kind which I ever witnessed was brought to St. Thomas's Hospital whilst I was an apprentice there, and I remember being struck with three circumstances in it: the first was, the great deformity of the knee from the projection of the tibia; the second, the ease with which the bone was reduced by direct extension; and the third, the little inflammation which followed upon what appeared to be so serious an injury; for the man was discharged from the hospital after a few weeks, having suffered little local or constitutional irritation. Internal.

The tibia is sometimes thrown upon the outer side of the knee-joint, the condyle of the os femoris being placed in the situation of the inner semilunar cartilage, or rather behind it, when the same deformity is produced as in the external dislocation. The External.

reduction of the limb is equally easy with the former, and the patient recovers with little diminution of the powers of the part. It seems to me that in both these dislocations the tibia is rather twisted upon the os femoris, so that the condyle of the os femoris, with respect to the tibia, is thrown somewhat backwards, as well as outwards or inwards.

CASE.

One of the aldermen of the City of London, riding down Highgate-hill during the night, and not being aware of a rail that was placed across a part of the road which was undergoing repair, the horse ran against the rail, and, turning quickly, threw his rider over it, whilst his leg was confined between the rail and the horse, so that his body was on one side of the rail, and his leg on the other: the result of this accident was, that he partially dislocated his tibia outwards, throwing the condyle of the os femoris inwards. Being immediately taken to a public-house, the tibia was easily replaced; and on his removal home, some hours afterwards, means were used to reduce the swelling and inflammation, which became considerable. When he attempted to bear upon the limb he found the capsular ligament very feeble, and he was obliged to have a knee-cap made of very strong leather, to support and connect the bones; by the aid of this bandage he gradually recovered, and was enabled to walk well, and to do duty on horseback as a light-horse volunteer, before twelve months had expired.

CASE.

I was consulted by Mr. Richards respecting Mr. Bovill, a gentleman from Barbadoes, who had dislocated his knee. I made a few notes on the case at the moment, which were as follows: The gentleman was thrown from a gig; the tibia was dislocated, and the fibula broken a little below its head. The head of the tibia projected much on the inner side of the condyle of the os femoris. My friends, Mr. Caddell and Mr. Richards, surgeons at Barbadoes, saw him a quarter of an hour after the accident; the leg was extended from the thigh-bone in a bent position of the limb; the extension was a long time continued, and force was employed by several persons for half an hour before the luxation was reduced. The limb became excessively swollen, and remained so for many weeks, the climate probably being unfavourable to his recovery; but at length the inflammation and its consequences were subdued by local depletion. When I saw him eighteen months had elapsed from the accident, and he could not then bend the joint at right angles with the thigh; there was also an unnatural lateral motion of the joint, from the injury which the ligaments had sustained. The fracture of the fibula had injured the peroneal nerve, as was evident from the numbness of which he complained in the outer part of the leg and foot.

Case of dislocation inwards.

The tibia is now and then dislocated in a direction forwards. In this accident, when the person is recumbent, the external marks of the injury are these: The tibia is elevated; the thigh-bone is depressed, and is thrown somewhat to the side as well as backwards; the os femoris makes such pressure on the popliteal

Dislocation forwards.

artery, as to prevent the pulsation of the anterior tibial artery on the foot; the patella and tibia are drawn by the rectus muscle forwards. Such were the appearances in a man of the name of Briggs, brought into Guy's Hospital in the year 1802, not only with this accident, but with a compound fracture of the tibia of the other leg, with dislocation of the head of the fibula. Mr. Lucas was obliged to amputate the compound fracture, and the man is now living at Walworth. The limb in this case was easily reduced by extending the thigh from above the knee, and by drawing the leg from the thigh, and inclining the tibia a little downwards. As soon as it was reduced, the popliteal artery ceased to be compressed, and the pulsation in the anterior tibial artery was restored.

Dislocation backwards.

The head of the tibia is sometimes dislocated backwards, behind the condyles of the os femoris, producing the following appearances: A shortened state of the limb, a projection of the condyles of the os femoris, and depression of the ligament of the patella, and the leg is bent forwards.

For the following case, I am indebted to my friend, Dr. Walshman, who has ever been a man of close observation in his profession, and always practised it with attention, judgment, and honour.

CASE.

Case by Dr. Walshman.

Mr. Luland, residing near the Elephant and Castle, at Newington Butts, a very robust and muscular man, on the 4th of January, 1794, dislocated his shoulder and knee at the same instant. The accident happened in the following manner: It was a severe frost, and the ground very slippery, and he being

in his cart, the horse fell. Mr. Luland was thrown under the front rail of the cart, and luxated the tibia backwards, whilst his shoulder fell on the saddle, and dislocated the os humeri into the axilla. The head of the tibia was completely dislocated backwards, reaching behind the condyles of the femur into the ham; the tendinous connection of the patella to the rectus muscle was ruptured; the external condyle of the os femoris was very protuberant; the leg was bent forward and was shortened, and there was a depression just above the patella. The patient felt most excruciating pain when the limb was moved, but there was not any considerable degree of suffering when it was at rest. The reduction was effected in the following manner: Two men extended upwards, one from the groin, and the other from the axilla, whilst two others extended the leg from a little above the ancle in the opposite direction; and they gradually increased the force of their extension till the bone was reduced. The patient was placed on his back, and Dr. Walshman directed the head of the bone to its natural situation. Dr. W. then applied a flannel roller on the knee, placed the patient in bed with his limb upon a pillow, and directed the part to be kept wet with an evaporating lotion. He remained in this state a fortnight, free from pain; the Dr. slightly moved the part every other day, as far as he could without giving pain. In about a month Mr. Luland began to walk on crutches. Ten weeks after the accident he was able to sit at his dinner-table, and in five months he had given up the use of his crutches, and appeared perfectly recovered, being able to use that limb as well as the other. He died of dropsy in February, 1819.

Dr. Walshman's treatment of this case was highly judicious He suffered the parts, as he observes in his letter, to remain at rest till the adhesive inflammation had united the lacerated ligament, and then, and not till then, began with passive motion.

PARTIAL LUXATION OF THE THIGH-BONE FROM THE SEMILUNAR CARTILAGES.

From relaxation.

Under extreme degrees of relaxation, or in cases in which there has been increased secretion into a joint, the ligaments become so much lengthened, as to allow the cartilages to glide upon the surface of the tibia, and particularly when pressure is made by the thigh-bone on the edge of the cartilage. That excellent practical surgeon, the late Mr. Hey, of Leeds, whose death is severely deplored in the district in which he practised, and lamented by those in the profession who have its improvement at heart, was the first who clearly described the symptoms and cause of these accidents, and suggested a mode of treatment which is ingenious, scientific, and generally successful. The injury most frequently occurs when a person in walking strikes his toe, with the foot everted, against any projection (as the fold of a carpet), after which he immediately feels pain in the knee, which cannot be completely extended. I have seen this accident also happen from a person having suddenly turned in his bed, when the clothes not suffering the foot readily to turn with the body, the thigh-bone

Mr. Hey's idea.

has slipped from its semilunar cartilage. I have also known it occur from a sudden twist of the knee inwards when the foot was turned out.

Explanation of the accident.

The explanation of this accident is as follows: The semilunar cartilages, which receive the condyles of the os femoris, are united to the tibia by ligaments, and when these ligaments become extremely relaxed and elongated, the cartilages are easily pushed from their situations by the condyles of the os femoris, which are then brought into contact with the head of the tibia; and when the limb is attempted to be extended, the edges of the semilunar cartilages prevent it. How then is the bone to be again brought upon the cartilages? Why, as Mr. Hey has advised, by bending the limb back as far as is possible, which enables the cartilage to slip into its natural situation; the pressure of the thigh-bone is removed in the bent position, and the leg being brought forwards, it can then be completely extended, because the condyles of the os femoris are again received on the semilunar cartilages. This plan is not however invariably successful, as the following case will shew. A lieutenant in the army suffered this accident repeatedly, and the limb was as often reduced by the above means; but at length in turning in bed, from the pressure of the bed clothes on his foot, the accident recurred. He came to town; but bending the limb had now no effect in enabling him to extend the joint, I therefore advised him to visit Mr. Hey, at Leeds; but I learnt that in this case the dislocation was never reduced.

Mode of reduction.

I made the following notes of the case of a gentleman who came to my house. Mr. Henry Dobley, aged thirty-seven, has

often dislocated his knee, turning the foot inwards and the thigh-bone outwards, by accidentally slipping in walking on uneven ground, or by sudden exertions of the limb; considerable pain was immediately produced, accompanied with a great deal of swelling. His mode of reducing it is as follows: He sits upon the ground, and then bending the thigh inwards and pulling the foot outwards, the subluxation of the os femoris being external, the natural position of the limb becomes restored. A knee-cap, laced tightly around the knee, is the usual preventive of the return of this accident; but it is not sufficient in Mr. Dobley without the addition of straps, and more especially of a very strong one of leather, just below the patella.

Different mode of reduction.

A young lady was brought to my house who was frequently the subject of this accident, but in her the cartilages had been several times easily replaced, and the return of the accident prevented by a bandage composed of a piece of linen with four rollers attached to it, which were tightly bound above and below the patella; this, she said, answered its intended purpose better than any other contrivance.

Particular bandage required

Great alteration takes place in the form and size of the knees, in some of these cases, from a chronic rheumatism occasionally attending them. I made the following notes of a case of this kind, on which I was consulted, and I have seen others similar to it.

CASE.

Lady D——, a year and a half ago, fell and twisted her thigh-bone inwards at the knee, producing great pain on the inner side of the joint. Her ladyship immediately restored the parts

to their situation by pressing the thigh outwards and the leg inwards, previously to which she could not move the joint. For a fortnight she was scarcely able to bend or straighten the knee, and the muscles felt to her to be in a state of cramp. She then began to stand upon the limb by the aid of crutches, but when she bore upon it considerably it suddenly bent back, with pain and subsequent swelling, and she felt the condyles at the same time slip from the semilunar cartilages upon the head of the tibia. Any sudden motion produced the same effect for fifteen months, and each of these accidents retarded her recovery for several weeks; the pain extended from the knee to the toe. For three months previous to her last accident, she walked on crutches, and even sometimes with only the aid of a stick; when, about two months since, in endeavouring to raise herself from a sofa, the left knee gave way as if the bone had slipped from its place, the thigh-bone being at the time twisted outwards; pain and swelling succeeded, and she has never been able to stand upright since. Her joints are all of them remarkably flexible, as the elbow may be easily bent backwards to form an angle with the os humeri. When a girl, she had frequently the sensation of putting the knees out of joint, but they soon got well. The knees are now swollen, and effusion of a considerable quantity of synovia has taken place into the joints. When she attempts to stand she cannot straighten her knees, but would fall forwards if unsupported. The principal object in the treatment is, to produce absorption of the fluid which is effused, and then to give due support to the ligaments. For the first of these she was desired to apply blisters, which were directed

to be kept discharging for a considerable time, and after they were healed, she was ordered to make pressure upon the joints by a strong bandage, which was to be occasionally removed to give an opportunity of employing friction. But she received material benefit from a constitutional treatment, consisting of pil. hydrargyri submuriatis comp., with decoctum sarsaparillæ compositum, and locally from the continued use of friction. I have had lately the pleasure of seeing her perfectly recovered.

In the dissection of these cases, the ligament is found extremely thickened; little pendulous ligamentous and cartilaginous bodies are seen suspended from it; a thick edge of cartilage projects from the articular cartilage, and a part of the latter is absorbed. When the bone is macerated, a great addition of ossific matter is found to have been made to the edges of the condyles of the os femoris.

DISLOCATION OF THE KNEE-JOINT.

Cases of dislocation of the knee-joint are so rare, that every instance of this accident is worthy of recital; and I feel greatly indebted to my friend, Mr. Toogood, surgeon at Bridgewater, for the following detail of one which occurred under his care.

CASE.

December 5th, 1806.

Francis Newton, a strong athletic man, thirty years old, fell from the fore part of a waggon, heavily laden with coals, and

entangling his foot in the frame-work of the shaft, was dragged for a very great distance before he was released. I saw him two hours after the accident. The left knee was very much swollen; the tibia, fibula, and patella were driven up in front of the thigh; and the os femoris occupied the upper part of the calf of the leg, the internal condyle being nearly through the skin. It was a complete dislocation, and the appearance of the limb so dreadful, that I despaired of being able to reduce it; but, to my surprise, it was more easily effected than I imagined. By placing two men to the thigh whilst I extended the leg, the man became directly relieved. The whole limb was placed in splints, and the strictest antiphlogistic treatment observed, with the most perfect quiet. The symptoms were very mild: and, by carefully watching him, he suffered very little inflammation or pain. At the expiration of a month I allowed him to get up, and on the 29th of January, he came into this town, a distance of four miles, in a cart, and walked from an inn to my house, with his leg but little swollen, and having some motion of the joint. He eventually recovered a very good use of his limb, and walks with so little inconvenience that he has followed his business as a waggoner ever since; and this day, November 30th, 1822, I have seen him walking by the side of his team with very little lameness.

COMPOUND DISLOCATION OF THE KNEE-JOINT.

Of this I have only seen one instance, and I conclude it, therefore, to be a rare occurrence; and there are scarcely any

accidents to which the body is liable which more imperiously demand immediate amputation than these.

CASE.

On Monday, August 26th, 1819, at eleven, p. m., I was sent for by Mr. Oliver, surgeon, at Brentford, to visit Mr. Pritt, who had fallen from the box of a mail-coach, and most severely injured his knee. I met, at the house to which he was carried, Mr. Oliver, and Mr. Hunter, of Richmond, surgeons, and immediately proceeded to examine the knee. A large opening was found in the integuments, through which the external condyle of the os femoris projected, so as to be on a level with the edges of the skin. The os femoris was thrown behind the tibia on the outer side of the head of the latter, and the external condyle of the thigh-bone was dislocated backwards and outwards; the thigh-bone was twisted outwards, and the internal condyle advanced upon the head of the tibia. I made attempts to reduce the condyle, but it could only be effected with extreme difficulty; and the bone, directly when the extension was removed, slipped into its former situation. The joint being freely opened by the accident, the bone dislocated, and when reduced easily slipping from its place, and the patient having an extremely irritable constitution, decided me at once to propose the amputation of the limb, which, being acceded to, was immediately performed. The symptoms of constitutional irritation which followed the operation became extremely severe, and he being delirious on the 31st, Mr. Oliver applied leeches to his temples, a blister under the occiput, and gave the saline medicine with the camphor,

and the pulv. ipec. comp. On the following day I was sent for to visit him, but being absent from London, my most able and excellent friend, Mr. Cline, visited him, and ordered him tinc. opii. gtt. v.—Pulv. castor. gr. x.—Mist. camphor. ℥iss. m.—Ft. haustus 4tâ quâque horâ sumendus. Soon after the second draught was administered he fell asleep, and after several hours repose awoke perfectly sensible. He gradually recovered, and left Brentford on the 25th of October, with a small wound still remaining on the stump.

Dissection.

I brought home the limb, and carefully dissected it. Under the skin there was great extravasation of blood in the cellular membrane surrounding the knee; the vastus internus muscle had a large aperture torn in it just above its insertion into the patella; the tibia projected forwards; and the patella was drawn to the outer side of the knee, being no longer in a line with the tubercle of the tibia. Looking at the joint posteriorly, both heads of the gastrocnemius externus muscle were lacerated; the capsular ligament was so completely torn, posteriorly, that both the condyles of the os femoris were seen projecting through the laceration in the gastrocnemius; neither the sciatic nerve, the popliteal artery and vein, the lateral, nor the crucial ligaments, were ruptured. *(See plate.)*

It is probable that all compound dislocations of the knee-joint will require a similar practice, unless the wound be so extremely small as to admit readily of its immediate closure and adhesion.

DISLOCATION OF THE KNEE FROM ULCERATION.

Ligament ulcerated.

In the progress of chronic diseases of the joints, inflammation beginning in the synovial membrane, and proceeding to ulcerate the articular cartilages and bone, at length affect the capsular ligament, and sometimes even the peculiar ligaments of the joints; the bones thus becoming unconnected, the muscles irritated by participating in the inflammation, draw the limb into distorted positions, and thus one bone becomes gradually displaced from the other. This state is most frequently seen in the hip-joint, from the oblique bearing of the thigh-bone on the pelvis. In the knee it is also not unusual that the thigh-bone shall be placed out of its natural line with the tibia, projecting either on the one side or the other.

Excessive distortion.

Now and then most remarkable distortions are produced by the irritative and spasmodic action of the muscles succeeding the ulcerative process of the ligaments, of one of which I have given a plate; Mr. Cline removed it by amputation in St. Thomas's Hospital. It had been the consequence of what is vulgarly called the white swelling of the knee-joint; the leg was placed forwards at right angles with the thigh, so that when walking on his crutches he had the most grotesque appearance, as the bottom of his foot first met the eye when he was advancing. Upon inspection of the patella it was found anchylosed to the os femoris, and the tibia was also joined by ossific union to the fore part of the condyles of the thigh-bone. *(See plate.)*

How prevented.

This state of parts may be prevented by opposing the action of

the muscles when their irritability first begins to produce distortion; by the application of splints; and by the exhibition of the pulvis ipecacuanhæ compositus, to diminish the irritability of the system. Thus I have seen, in cases of ulceration of the hip-joint, the irritative action of the flexor muscles diminished, and future distortion prevented, by drawing down the limb and keeping it in the extended position; but as this extension is most painful to the patient, however desirable it may be, it should be accomplished very gradually.

FRACTURES OF THE KNEE-JOINT.

I SHALL now, pursuing my former plan, describe the fractures to which the bones entering into the composition of this part are liable; and first the

FRACTURES OF THE PATELLA.

Transverse or longitudinal.

This bone is generally broken transversely, sometimes, though rarely, longitudinally: it is liable also to simple and compound fracture, but, fortunately, the latter is but of rare occurrence.

Symptoms.

When the patella is transversely broken, the upper part of the bone is drawn from the lower, its superior portion being elevated by the action of the rectus, vasti, and cruralis muscles, which are inserted into its upper part; whilst the lower portion is still retained in its natural situation by the ligament which passes from it to the tubercle of the tibia.

Degree of separation.

The degree of separation, thus produced, depends on the extent of laceration of the ligament; for, when the ligament

is but little torn, the separation will be half an inch, but under great extent of injury the bone is drawn five inches upwards, the capsular ligament and tendinous aponeurosis covering it being then greatly lacerated; and this, with one exception, is the greatest extent of separation which I have seen. The accident may be at once known by the depression between the two portions of bone; the fingers passing readily down to the condyles of the os femoris, into the joint as far as the integuments will permit; and the elevated portion of bone moving readily on the lower and fore part of the thigh. The power of extending the limb is lost immediately after the accident, and likewise that of supporting the weight of the body on that leg, if the person be standing; for the knee bends forwards from the loss of action in the extensor muscles. The pain of this accident is not very severe, and a simple fracture is not dangerous, for the constitution feels it but little. In a few hours after the accident, a copious extravasation of blood takes place upon the fore part of the joint, so that the appearance is livid from ecchymosis, but this is removed by absorption in a few days. Considerable inflammation and fever succeed, and there is a great degree of swelling in the fore part of the joint, both from the free secretion of synovia, and the effusion arising from inflammation. No crepitus is felt in this fracture, for the bones cannot be sufficiently approximated to evince this general discriminating mark of other fractures.

The separation of the bones is much increased by bending the knee, as this act removes the lower from the upper portion of

bone, pulling down the tibia, ligamentum patellæ, and the lower part of the bone from the upper.

Causes. This accident arises from two causes: first, from blows upon the bone produced by falls upon the knee, or received upon the patella in the erect position of the body; and, secondly, from the action of the extensor muscles upon the bone.

Blows or actions of the muscles.

Case. A gentleman walking in the country, and not used to jumping, leaped a ditch of considerable breadth; and when he reached the opposite bank, being in danger of falling, he ran forward several steps, and with difficulty recovered himself; in this attempt to save himself from a fall, he felt the patella snap. I was sent for to him, and found his patella broken, and the portions of bone considerably separated.

A lady, descending some stairs, placed her heel near the edge of one of the stairs, and was in danger of falling forwards, when, throwing her body somewhat backwards to prevent the fall and to straighten the knee, the patella became broken.

That a bone should thus break by the action of muscles appears at first sight incomprehensible, but this circumstance is easily explained. When the knee is bent, the patella is drawn down on the end of the condyles of the os femoris, so as to bring the upper edge of the bone forwards; and at that moment it is that the patella is broken, by the rectus muscle acting not in a line with the bone, but at right angles with it, or nearly so, and upon its upper edge more particularly.

Explanation.

Mode of union. With respect to the union of this bone, whether the separation be great or inconsiderable, it is generally effected by an

intervening ligamentous substance. The bone itself undergoes but little alteration; the lower portion, joined by ligament to the patella, has its broken cancellated structure still apparent, although a little smoothed. The upper portion of bone has its broken cancelli covered by a slight ossific deposit, so that there is more ossific action in the upper than in the lower portion of the bone, and certainly much less than in bones which do not form a part of the joints. The internal articular surface of the bone preserves its natural smoothness. Blood is immediately deposited in the place of the injured ligament, but this in a few days is absorbed. Inflammation arises and pours out adhesive matter, which extends from one edge of the lacerated ligament to the other, and even between the bones, to each of which it is firmly united. *(See plate.)* Vessels shoot from the edges of the ligament and render the new substance organized, producing a ligamentous structure similar to that from which the vessels shoot; this substance is not, however, always perfect, for I have seen apertures in it; but this will greatly depend upon the extent of the laceration of the ligament, and the too early use of the limb. In the dog and in the rabbit, or almost any other quadruped, it is possible by experiment to trace the mode of union of this bone.

Experiment I.

I drew the integuments much aside in a rabbit, and dividing them, placed a knife upon the patella and struck it lightly with a mallet; the bone was broken and directly drawn up by the action of the muscles. I let the integuments go, and the wound

was not opposite to the fracture. In forty-eight hours I killed the animal and examined the part: the bones were separated three quarters of an inch, and the intervening part filled with coagulated blood.

Experiment II.

I repeated the former experiment, and having killed the animal on the eighth day, found most of the blood absorbed, and adhesive matter occupying the space between the bones.

Experiment III.

The former experiment repeated. The animal examined on the fifteenth day. The adhesive matter had acquired a smooth and somewhat ligamentous character.

Experiment IV.

The same division of the bone being made, it was examined on the twenty-second day, when the new ligament was complete.

Experiment V.

The same repeated, and the examination made in five weeks. The part was injected, and vessels were found proceeding from the edge of the ligament into the adhesive matter, now become ligamentous. So that at the end of five weeks the vascularity is complete, and some vessels proceed into the new ligament from the bone, but chiefly from the lacerated ligament. Upon the dog these processes may be equally well observed, but they are not quite so rapidly produced in a large dog as in the rabbit.

The parts were dissected and preserved after these experiments, both in the dog and rabbit, and they are deposited in the collection of St. Thomas's Hospital, where they may be always seen.

Experiment VI.

In the rabbit, having divided the bone, I sewed the two portions by conveying a needle and thread through the tendinous covering of the bone, but the ligatures separated, and the bones still united by ligament.

Experiment VII.

I divided the bone, and cut the rectus muscle across above it, yet the patella united by ligament.

I could not, either in the dog or rabbit, succeed in producing a bony union in the transverse fracture. Yet in a patient of my kind friend, M. Chopart, at Paris, I once saw a case which appeared to me to be united by bone; and Mr. Fielding, of Hull, has lately published a similar case.

A ligamentous union of the transverse fracture of the patella is that which generally occurs; and if there be an exception it is very rare. But still the principle which is to guide the surgeon's conduct is, to make that ligament as short as possible. If the ligament be of great length there is a proportionate weakness; for as soon as the accident has happened, the rectus muscle retracts and draws up the superior portion of the patella; and in proportion to the retraction suffered to remain, is the degree of shortening of the muscle, and consequently the diminution of its power. Those,

Ligamentous union as short as possible.

therefore, in whom the bones have united after being widely separated, if they walk quickly, do it with a halt, and are very liable to fall, and to break the other patella. Let then the muscle be brought as nearly as it can be to its natural length; and although complete apposition of the bone be very rarely effected, yet the ligamentous union is rendered as short as circumstances will permit, and the patient will recover the power of the limb.

The notion which was formerly entertained of the danger of squeezing the callus into a projection in the inner side of the bone, so as to destroy the smoothness of its internal surface, is not at all tenable.

Treatment. When called to this accident, the surgeon places the patient in bed upon a mattress, extends the limb upon a well padded splint placed behind the thigh and leg, to which it is tied, and which should be hollowed. The patient's body should be raised as much as he can bear to the sitting posture, to relax the rectus muscle. An evaporating lotion is to be then applied upon the knee, consisting of liq. plumbi *s.* ecetat. dilut. ʒ. v. with spir. vini. ʒ. i.; and no bandage should be at first employed. The body should be slightly raised in bed to relax the rectus muscle, and the heel should be raised to bring up the lower portion of the patella. If in a day or two there be much tension or ecchymosis, leeches should be applied, and the lotion be continued; when, after a few days, the tension has subsided, then, and not till then, should bandages be employed. I have seen the greatest suffering and swelling produced by the early application of bandages in these cases, even so as to threaten sloughing of the skin when there had

been much contusion. The means which are most frequently employed in the treatment of this case are as follows: A roller is applied from the foot to the knee, to prevent the swelling of the leg, and the upper portion of bone is pressed downwards, as far as it can be without violence towards the lower, so as to lessen the retraction of the muscles, and produce the approximation of the portions of bone. Then rollers are applied above and below the joint, confining a piece of broad tape next the skin on each side, which crosses the rollers at right angles; these portions of tape are bent down and tied over the rollers so as to bring them near each other, and thus to keep down the upper portion of bone. Sometimes, instead of the tape on each side, a broad piece of linen is bent over the rollers on the fore part of the joint, and is there confined, so as to approximate the pieces of bone, and to bind down the upper portion of the patella, that its lower broken edge may not turn forwards.

But the mode I prefer is as follows: A leathern strap should be buckled around the thigh, above the broken and elevated portion of bone; and from this circular piece of leather another strap should be passed under the middle of the foot, the leg being extended, and the foot raised as much as possible. This strap is brought upon each side of the tibia and patella, and buckled to that which is fixed around the lower part of the thigh. The strap may be confined to the foot by a tape tied to it, and to the leg at any part in the same manner; this is the most convenient bandage for the fractured patella, and for the patella dislocated upwards by the laceration of its ligament. A roller is to be applied upon the leg.

In this position, and thus confined, the limb is to be kept for five weeks in the adult, and for six weeks at a more advanced age. Then a slight passive motion is to be begun, and this must be done gently and with so much circumspection that the ligament, if not firmly united, shall not give way, and suffer the bones to recede. If the union be found sufficiently firm to bear it, the passive motion is to be employed, from day to day, until the flexion of the limb be complete.

If passive motion were not used it appears that the action of the extensor muscles would never return; for those who are kept in bed, with the joint at rest, do not in many months acquire any power of bending and extending the limb; but when passive motion is to be used the patient is placed on a high seat, and directed to swing the leg, by which motion is given to the rectus; and if the mind be then directed to the contraction of that muscle, its powers will be gradually renewed. When the rectus muscle has been shortened, and the upper portion of bone is drawn from the lower, all the disposition to action in that muscle ceases; and it does not seem disposed to recover its voluntary action until it becomes again elongated, which effect takes place after the union of the ligament by bending the knee; and from this point of elongation the muscle begins to contract.

State of the muscle.

A young woman was brought into my house in her father's arms, and he said, "I am obliged to carry her, for she has lost the use of her legs, having broken both her knee-pans eight months ago, and she has never been able to use her limbs since." Passive motion was directed, and she was ordered to try to extend her legs after they had been bent by the surgeon. At first she

could effect but little: however, by repeated trials, she gradually recovered the use of her limbs. Mr. John Hunter, who raised surgery into a science, and who seems to have been the first who attended to the principles on which the practice of surgery ought to be regulated, always dwelt most ably upon this subject in his lectures. Patients, from the pain which passive motion produces, and the slow return of action in the muscles, are indisposed to suffer the one or to make trials of the other; but without them there can be no recovery.

Degree of approximation.

The degree of approximation of the bone is, as I have stated, a matter of great consequence. The bone is rarely brought into contact so as to be united in the transverse fracture by ossific union, but the less the distance between the bones the greater is the power which the muscle re-acquires; for in proportion as the muscle is shortened it is weakened; and in ascending there is difficulty in raising the limb, in descending in keeping it extended; the uniting ligament is liable to be torn, and the other patella to be broken by falls; therefore the surgeon should bring the bones as near together as he can, to render the ligamentous union as short as possible, and consequently to leave the muscle with as much of its original power as the nature of the accident will permit.

THE PERPENDICULAR FRACTURE OF THE PATELLA.

We have in the collection at St. Thomas's Hospital a patella, one fourth of which has been broken off; the edge is smooth, and no attempt at ossific union appears to have been made.

Ligamentous union.

A gentleman consulted me who had about one third of the patella separated from the other part of the bone; it had united by ligament, for there was free motion between the fractured piece of bone and that from which it had been removed. He recovered quickly from this injury, and it affected his power of walking very little.

During the winter of 1822, a body was dissected at St. Thomas's Hospital, in which both the patellæ had been broken longitudinally, and although they were in contact, they were both united by ligament. Mr. Silvester, one of our pupils, had the kindness to make a drawing of one of these, of which I have given a plate.

This circumstance surprised me, because I saw no reason why the patella should not be united by bone when broken perpendicularly, as I thought the muscles would have a tendency to bring the parts together. I made it, therefore, a subject of experiment.

Experiment I.

July 31st, 1818, I broke the patella of a dog by placing a knife upon it in the longitudinal direction, having first drawn the integuments aside; and on the 12th of September following I examined the part, when I found the two portions of bone considerably separated from each other, and united by ligament. The cause was as follows: When I had divided the bone, the knee became bent, the condyles of the os femoris pressed against the inner side of the patella, and thrust the parts asunder, and only a ligamentous union took place. *(See plate.)*

Union by ligament in experiments.

Experiment II.

August 2nd, 1818, I broke in the same manner the patella of a

rabbit, and examined the parts on September 3rd, when I found the two portions of bone widely separated, and united only by ligamentous matter. I now began to think it impossible for the patella to unite by bone, but determined to make another experiment to determine this point.

Experiment III.

I divided the patella longitudinally in a dog, but took care that the division should not extend into the tendon above or to the ligament below it, so that there should be no separation of the two portions. I examined it three weeks after, and found it united; no separation existing between the two portions.* (*See plate.*) Union by bone.

Experiment IV.

October, 1819. I divided the patella by a crucial fracture into four portions; the two upper portions neither united with each other nor with the bones below, but the two lower portions became united by bone.

It appears then that under longitudinal and transverse fracture, a ligamentous union is generally produced, and that it arises from the separation produced in the bone; but that if that cannot separate, and its parts remain in contact, ossific union may be produced.

In the summer of 1819, Mr. Marryat was thrown from his gig

* The bone was, under maceration, found united in part by bone, and in part by cartilage, not yet completely ossified. It is preserved, and may be seen at any time by those who are curious to examine it.

as he was passing along the Strand; by the fall he fractured his patella transversely, and the lower portion of the bone was also broken perpendicularly, so that it was divided into three pieces. The transverse fracture united, as usual, by ligament; but the perpendicular, by bone.

Mr. Parrott, of Tooting, who also attended the case, writes in these words:

"Dear Sir,—I have great pleasure in replying to your letter. The longitudinal fracture of the patella of Mr. M. has become very firmly consolidated, but there is a line or ridge to be traced upon the surface of the bone, which marks distinctly the place where it had been separated.

"John Parrott, Jun."

Tooting.

Treatment.

In the longitudinal or perpendicular fracture of the patella, the best treatment consists in extending the leg, and in using local depletion, and evaporating lotions; in a few days a roller should be applied around the limb, and then a laced knee-cap, with a strap to buckle around the knee above and below the patella, and a pad on each side to bring its parts as nearly as possible into contact.

COMPOUND FRACTURE OF THE PATELLA.

From violence or ulceration.

These fractures occur from injury, or from an ulcerative process under peculiar circumstances.

The cases which I have seen of this accident are as follows:

CASE I.

A man was admitted into Guy's Hospital, in the year 1796, under Mr. W. Cooper, surgeon of that hospital, with a compound fracture of this bone; violent inflammation followed; suppuration ensued, with the highest degree of constitutional irritation; and as no opportunity was given for amputation, from the great swelling of the thigh, this man died. The bone is in the Museum of St. Thomas's Hospital, disunited as at the first moment of the accident.

CASE II.

A man was admitted into St. Thomas's Hospital, under the care of Mr. Birch, with a fracture of the patella, and a small wound extending into the joint. The knee was fomented and poulticed; inflammation and suppuration followed; and this man in a few days died with the highest symptoms of constitutional irritation.

CASE III.

Mr. Hawker, surgeon, called me to visit a man who had just arrived in London; who, being at work in a warehouse up one pair of stairs, on hearing the signal for dinner, seeing the doors of the warehouse open, walked quickly out, and fell into the street. By this fall he had a compound fracture of the patella. The limb was attempted to be saved. The joint suppurated; the discharge became excessively great; and the symptoms of irritation ran so high, that I thought he would

not recover; but he became somewhat better, and I advised him to go into the country. I afterwards heard that he gradually recovered with an anchylosed joint.

CASE IV.

Mr. Redhead, residing at Kennington Cross, aged thirty-nine years, was thrown from his gig, on June 18th, 1819, against a cart-wheel. His knee came violently in contact with the wheel, which fractured his patella and opened the joint. Mr. Dixon, of Newington Butts, was sent for, and he found that the knee had bled freely from a wound on its outer side, from which the synovia freely escaped, and which readily admitted his finger to the shattered patella. The accident happened at ten o'clock in the morning: I was sent for by Mr. Dixon, and when I met him at four o'clock, I found a wound on the fore part of the knee, through which I readily passed my finger into the joint. The patella was not broken transversely, but, as I have expressed it, shattered; that is, broken into several pieces; and a small piece which was separated from the rest I removed. It was agreed between Mr. Dixon and myself, that an attempt should be made to save the limb, for the patient was of a spare habit, and, from his great composure, shewed that he was not of an irritable constitution. I passed a suture through the integuments, knowing the difficulty of keeping the wound closed on account of the continued escape of synovia, but taking the utmost care that the ligament should not be included in the suture. Adhesive plaster was also applied over the wound, and rollers lightly put on, which were kept constantly wet with spirits of wine and water. The leg was placed in

the extended position, and he was ordered not to move it in the slightest degree, and to live on fruit.

Saturday. He had passed a very good night, and was free from pain or fever.

Sunday night. He was restless, and was thought delirious.

Monday morning. He had a dose of ol. ricini, which relieved him from his feverish feelings.

Tuesday. He stated he had passed a good night, and he afterwards had no bad symptoms. As there was no swelling, no inflammation, and scarcely any pain, the suture was not removed until the 30th of June, when the adhesive plaster was renewed.

He recovered without any untoward accident. Mr. Dixon ordered him from bed in a month, and at the end of five weeks gave the joint slight passive motion. On the 7th of August, the patient walked across his room; and he entirely recovered the use of his limb.

If the laceration be extensive, or the contusion very considerable in these cases, amputation will be required; but if the wound be small, and the patient be not irritable, and no sloughing of the integuments or ligament be likely to occur from the nature of the accident, it will be best to try to save the limb; and the treatment of Mr. Redhead's case is that which I should pursue. The principal object is to produce adhesion immediately; and every means in our power must be used for that purpose. I know well that sutures are generally objectionable, and I never employ them if I can possibly succeed without them; but in moveable parts, in those which are unsupported, and in those through which a

secretion is liable to force its way, they are not only justifiable, but highly necessary. Fomentations and poultices must not be employed in these cases, as they prevent the adhesive process.

A compound fracture of the patella will be sometimes produced by an ulcer, as in the following case.

CASE.

Ulceration.

A woman was admitted into Guy's Hospital in 1816, with a simple and transverse fracture of the patella, which had long been united by a ligament of about three inches in extent. Ulcers were formed upon different parts of the body; and, unfortunately, one of these upon the integuments over the ligamental union of the patella. It became sloughy, and extended through the new ligament to the joint, which it laid open; violent constitutional irritation succeeded; a copious suppuration was produced; and no opportunity was given of amputating the limb, for the inflamed and swollen state of the thigh forbade it. This woman died.

OBLIQUE FRACTURES OF THE CONDYLES OF THE OS FEMORIS INTO THE JOINT.

These cases are of rare occurrence; but when they happen it is difficult to prevent deformity, and to restore to the patient a sound and useful limb. They are known by the great swelling of the joint with which they are accompanied, by the crepitus which is felt in moving the joint, and by the deformity with which

they are attended. The fracture is sometimes of the inner, and sometimes of the outer condyle, and the bone is split down into the joint. Of either condyle.

Whether the external or internal condyle be broken, the same treatment is required. The limb is to be placed upon a pillow in the straight position, and evaporating lotions and leeches are to be used to subdue the swelling and inflammation. When this object has been effected, a roller is to be applied around the knee, and a piece of stiff pasteboard, about sixteen inches long and sufficiently wide to extend entirely under the joint, and to pass on each side of it, so as to reach to the edge of the patella, is to be dipped in warm water, applied under the knee, and confined by a roller. When this is dry, it will have exactly adapted itself to the form of the joint, and this form it will afterwards retain, so as best to confine the bones. Splints of wood or tin may be used on each side of the joint, but they are apt to cause uneasy pressure. In five weeks passive motion of the limb may be gently begun, to prevent anchylosis. I prefer the straight position in these cases, because the tibia presses the extremity of the broken condyle into a line with that which is not injured. Treatment.

Examples of compound fractures of the condyles are very unfrequent: the following was under the care of Mr. Travers, in St. Thomas's Hospital, who was so kind as to send me the history of it. Compound fracture.

Michael Dixon was admitted into St. Thomas's Hospital, September 17th, 1816, for a fracture of the lower extremity of the femur, caused by a carriage-wheel in motion, with which his legs

became entangled. There was much displacement of the fractured bone, and a small wound opposite the external condyle. Upon examination it was evident that the fracture had extended nearly in the direction of the axis of the bone, and there was a transverse fracture of the shaft of the bone above the joint; the external condyle was moveable, and thrown out of its place during the accident, as if it had been drawn by the leg, which was twisted inwards. The limb was laid in a fracture-box, in a semi-flexed position on the heel; the constitutional disturbance was very slight.

Oct. 5. The external condyle is still moveable: the integuments over it are ulcerated, so as to denude the bone. The health remains good.

Nov. 5. The broken bone protrudes and appears to be dead; it is surrounded by fungous granulations, and there is but little discharge.

Nov. 18. The protruded bone having been gently twisted off by forceps, proved to be the external condyle, with its articular surface: there still protruded a small portion of bone, but this soon healed over. The limb was now placed in an extended position, as anchylosis was considered unavoidable.

Dec. 1. The boy has recovered almost the perfect use of his limb, and is enabled to bend and extend it without pain.

Dec. 6. The boy was discharged from the hospital. The wound was healed, and he can walk tolerably well with a stick.

On the February following he called at the hospital, walking without any support, and having free use of the joint.

In aged persons these accidents sometimes prove destructive to life, of which the following is an example; and, indeed, I have known a simple fracture of the condyles produce the same effect.

COMPOUND FRACTURE OF THE CONDYLES OF THE FEMUR.

CASE.

— Blukwick, aged seventy-six, on the 1st of January, 1822, slipped accidentally off the curb-stone, and received the whole weight of the body upon the knee. The patella appears to have acted as a wedge between the two condyles of the os femoris, which were separated by a fracture, running obliquely along the shaft of the bone, the end of which was forced through a wound in the integuments. The patella remained in its place, and was unbroken. The patient at the time of the accident was in a state of inebriation. Mr. Rowe, of Burton Crescent, to whom I am indebted for the particulars of the case, saw him about three hours after the accident: he had him conveyed to bed, and without much difficulty brought the fractured bones in apposition; they were retained in their situation by splints and bandages, and the limb was placed in the straight position. A lotion of the liquor plumbi was applied over the part, and an opiate was administered at night.

Compound fracture of condyles.

Case by Mr. Rowe.

The patient passed a tolerable quiet night, and in the morning was pretty free from pain. An aperient draught was administered,

which operated freely. On the evening of this day I was called in to him. I directed a leathern cap to be strapped over the fractured part, and the straight position of the limb to be preserved. The patient was ordered a regular diet, and saline draughts, with an occasional opiate.

This treatment was continued until the twenty-first day from the accident, and the patient remained free from any bad symptom. On the evening of that day, however, he was found much heated, with a very frequent pulse, dry tongue, and a tendency to delirium: these alarming symptoms, it appears, were increased by a glass of brandy and water taken contrary to the direction of his medical attendant. Mr. Rowe ordered him an aperient, but the danger was rapidly increasing: the patient was found next morning in a high degree of fever; pulse one hundred and thirty; countenance exhibiting great depression. These unfavourable symptoms went on increasing, and on the twenty-fourth he died.

The limb, on examination after death, exhibited great signs of inflammation; a considerable quantity of matter was found between the muscles of the thigh, part of which was discharged by the external wound.

Dissection.

Upon examining the thigh-bone it was found that its shaft was broken very obliquely, about seven inches above the knee-joint; and that the bone was split down into the joint, near to the centre, between the condyles, but inclining somewhat to the external condyle: this portion of the bone was loose and detached from the internal condyle: there was also a piece three inches in extent,

detached from the shaft of the bone, but which had fallen into the cancelli, where it remained lodged. *(See plate.)*

OBLIQUE FRACTURES OF THE OS FEMORIS, JUST ABOVE ITS CONDYLES.

Oblique fractures of the condyles.

This is a most formidable injury from its consequences on the future form and use of the limb; for it is liable to terminate most unfortunately, by producing deformity, and by preventing the flexion of the knee-joint.

It is only of late years that I have had an opportunity of investigating this case by dissection, and, consequently, of obtaining substantial knowledge of the exact nature of the injury. The appearances produced by it are, that the lower and broken extremity of the shaft of the bone projects, and forms a sharp point just above the patella, which pierces the rectus muscle, threatens to tear the skin, and sometimes does so: whilst the patella, tibia, and condyles of the os femoris sink into the ham, and are drawn upwards behind the broken extremity of the shaft of the os femoris.

The accident happens when a person falls from a considerable height upon his feet, or is thrown upon the condyles of the os femoris with the knee bent. In all the cases, the fracture was very oblique through the shaft of the bone; and hence the pointed appearance of the extremity of the fracture, and the difficulty of keeping the bones in apposition.

CASE.

Case. A body was brought into the dissecting-room at St. Thomas's Hospital, which fell to the lot of Mr. Patey, surgeon, of Dorset-street, Portman-square, to dissect, and he kindly permitted me to make a drawing from the limb. It appeared, upon view of the thigh, that the limb had been broken just above the knee-joint, and that the shaft of the bone projected as far as the skin, just above the patella: the union was firm, but the magnitude of the bone was exceedingly increased. When the integuments were removed, the end of the superior portion of the shaft of the bone was found to have pierced the rectus muscle, through which it still continued to project (*see plate*); and behind this projecting portion of bone the rectus muscle was situated, which passed to the patella. The patella, on the attempt to draw it up, was stopped by the projection of the fracture, so that its movement upwards was exceedingly limited. The condyles of the os femoris, and the lower portion of the bone, had been drawn by the action of the muscles behind the end of the fracture of the upper portion, and had united by a very firm callus to the body of the bone.

This union had necessarily produced a great diminution in the power of extending the limb; for the rectus muscle was really hooked down by the fractured extremity of the bone: but even if the bone had not pierced the muscle, still the elevation of the patella would have been prevented, by its being drawn against the fractured end of the thigh-bone in the contraction of the muscle. It appears, then, in the treatment of this case, that a most firm and continued extension must be supported to prevent

the retraction which will otherwise ensue; but it will be seen by the two following cases, that this defective union is, with great difficulty prevented; and that the complete flexion of the limb afterwards, was not in either instance accomplished.

COMPOUND FRACTURE JUST ABOVE THE CONDYLES OF THE OS FEMORIS.

CASE.

Mr. Kidd, who weighed fifteen stone, fell on the 9th of November, 1819, from the height of twenty-one feet upon his feet, and broke his thigh-bone just above the knee by the severity of the concussion. The fracture was situated immediately above the condyles, and the broken extremity of the shaft of the bone appeared through the integuments and rectus muscle, just above the patella. He was immediately carried home, and I saw him, with Mr. Phillips, surgeon to the King's household, a short time after the accident. We agreed that the projecting extremity of the thigh-bone should be immediately sawn off, and that the edges of the wound should be approximated so as to render the fracture simple; and this was immediately done. The limb was placed upon the double inclined plane. The wound healed without difficulty, and our first object was thus accomplished. On the 30th of November, splints were applied, in order to press the bones firmly together. On December 23rd, the leg was straightened, Case.

and the inclined plane was lowered, so as to bring the limb gradually into a straight position. On February the 2nd, he sat up in bed. On the 7th of February, the knee having been moved, the fractured bones appeared to separate, and on the 14th, it was clearly ascertained that the bone was not united. On the 16th, a leathern bandage with many straps was tightly buckled around the knee. Having previously tried the position upon his side, which only led to a greater separation of the bone, he was again placed upon his back. On the 3rd of May, the bone was found to be united, and on the 12th, the leathern bandage was removed, and the limb placed on a pillow. On the 10th of July, he moved from one side of the bed to the other with difficulty, and on the 16th, was placed on another bed, which was obliged to be adjusted to the exact level with the other, before his removal could be accomplished. On July the 19th, he was removed from London to Kensington on a litter. On the 8th of August, the thigh was fomented, in order to remove the excessive bulk it had acquired, and to diminish its hardness; but the fomentation was discontinued on the 14th, because it was found to increase the swelling. On the 15th, the leg was bathed with the liquor plumbi subacetatis dilutus, and spirits of wine: the skin having been ulcerated from the time that the bandage was buckled tight around the knee. On October the 24th, the leg was placed in a gout cradle. On the 16th, he was on a sofa for two hours, but on the 28th, was obliged to keep in bed, because irritation and swelling had been produced by moving on the two preceding days. On November the 3rd, he was wheeled into another room

on a chair. On January the 29th, 1822, he was, for the first time, on crutches; and on February the 24th, he first walked out of doors.

His present state, March 1822, is as follows: The bone above the knee is excessively enlarged; the patella is fixed below the broken extremity of the shaft of the bone, the point of which adheres to the skin.

Mr. Kidd possessed a very fine constitution, for his pulse after the accident never exceeded 63; and although the rectus muscle was penetrated by the bone, he never complained of any spasmodic contraction of the limb.

SIMPLE FRACTURE ABOVE THE CONDYLES OF THE OS FEMORIS.

For the following history I am indebted to Mr. Welbank, Jun., who attended the case with me.

CASE.

Mr. ——, of middle age, muscular and tall, was driving on the morning of July 20th, 1821, in the neighbourhood of Leicester-fields, and was thrown forward out of his gig, over the horse, which had fallen. It is probable that the external condyle of the right femur received the force and weight of his descent upon the pavement. He was brought from Leicester-fields to Chancery-lane in a coach, with his legs out of the door, no surgical

assistance having been yet procured. When first seen by his surgical attendant he was lying upon his back on the bed, with the right leg bent and lying across the middle of the left leg at an angle. There was an appearance resembling the lateral dislocation of the knee, from a deep hollow, visible on the external side of the joint, in the situation of the external condyles; above this hollow, close to the joint, and on its external or fibular side, an abrupt and sharp projection of bone was distinctly observable. Slight extension replaced the parts, and it now appeared that the thigh had, previously to the reduction, been bent inwards over the left, upon an oblique fracture, situated close to the patella. The patella itself was very obscurely felt through a circumscribed effusion in front of the joint. Just above the situation of its upper edge might still be traced the ridge of the fracture, a slight groove intervening: the appearance, indeed, at this and later periods of the accident might have been mistaken, on superficial examination, for the transverse fracture of the patella. Flexion produced great projection of the upper part of the femur, and extension readily restored the natural appearance, except in the swelling on the front of the patella. The crepitus was very indistinct, if at all observable.

Little more was done during the first week than steadying the joint in the extended position with short splints, and subduing the inflammation of the capsule which supervened. After this period, a long splint was applied from the trochanter major to the outside of the foot, and an opposing short splint from the middle of the femur to the middle of the inside of the leg, and firmly confined by tapes and buckles. The whole limb was supported upon an

inclined plane, and flexion cautiously obviated. To prevent motion of the pelvis the stools were removed in napkins. The posture was not, however, steadily maintained; and it was frequently found that the upper point of bone varied in its degree of projection, and at different times, more or less, encroached on the situation of the upper edge of the patella. To remedy this, slight permanent extension, with weights appended to the foot, was adopted with advantage; though I believe that the position was by no means rigorously maintained, for I have since understood that the patient, not unfrequently, even had his back washed. The ridge of the upper portion of the femur appeared, however, to project so slightly, that it was deemed better to ensure union, than to add to the frequency of disturbance, by being too solicitous of exact apposition.

About September the 7th, the bone was thought sufficiently united, but flexion was neither attempted by the surgeon, nor permitted to the patient. On September the 10th, the patient was removed to Eastbury, Hertfordshire, in a litter-carriage, as his health was suffering: the limb being steadied with splints, and the position resumed, during the journey. In removing from one bed to another, and in other alterations of posture, it was obvious that flexion produced a greater appearance of projection of the femur than had been anticipated. This might be referred to the drawing down, or rather sinking of the patella in flexion; and, indeed, it could to appearance be nearly remedied by elevating the leg upon the thigh, as in extension. Under these circumstances, however, rest in the extended posture was again adopted for a fortnight. About September 25th, a second examination decided the necessity

for further rest, as the increase of projection, on flexion of the knee, and a slight lateral motion, induced a belief of infirm union. It is worthy of mention, that the immediate vicinity of the joint, the mobility of the patella, and the general thickening, rendered all examinations of extreme difficulty and uncertainty. A circular belt was tightly girded upon the situation of the injury, with a view of compressing the fracture, and maintaining the parts in firm apposition. October 16th, the union was considered complete, and the patient allowed to get up. On November 1st, he resumed his professional duties as an advocate. For a considerable period he suffered pain and swelling of the limb, but has gradually and slowly improved.

May, 1822. At this date he can walk about his room without assistance either of crutch or stick. He has little power of flexion at the knee-joint. The joint is, however, apparently moveable to a certain extent beneath the patella, which bone is fixed beneath the projecting edge of the upper portion of the femur, which evidently overlaps and displaces it. There is visible shortening of the limb, and the *contour* of the thigh is somewhat bowed outwards.

J. Welbank, Jun.

Chancery Lane.

To obviate the evils which are produced by this formidable accident, I have had an apparatus constructed to preserve the thigh in a constant state of extension. *(See plate.)* The leg is to be first bent, to draw the rectus muscle over the broken extremity of the bone, and then the apparatus is to be applied,

and the limb to be preserved in a constant state of extension in the straight position.

FRACTURE OF THE HEAD OF THE TIBIA.

Oblique fractures of the tibia into the joint.

The head of the tibia is sometimes obliquely broken; and if it be fractured into the knee-joint, the treatment which it requires is similar to that which is necessary in the oblique fracture of the condyle of the os femoris; that is, first, to maintain the straight position of the limb, because the femur preserves the proper adaptation of the fractured tibia by serving as a splint to its upper portion, and keeping the articular surfaces in apposition. Secondly, a roller to press one part of the broken surface against the other. Thirdly, a splint of pasteboard to assist in the preservation of that pressure. And fourthly, early passive motion to prevent anchylosis.

Fracture just below the joint.

But if the fracture of the tibia be oblique, yet not into the joint, then it is best to place the limb upon the double inclined plane; for the cause of deformity being the elevation of the lower portion of the tibia, which is drawn up on the side of the knee-joint, as the fracture is in the inner or outer side of the tibia, the weight of the leg keeps the limb constantly extended as it hangs over the angle of the inclined plane, and thus the bone is brought into as accurate apposition as the nature of the fracture permits.

DISLOCATIONS OF THE HEAD OF THE FIBULA.

The fibula joins the tibia, three quarters of an inch below the articulation of the knee. Its head is inclosed in a capsular ligament, which unites it to the tibia, to which it is also joined through the greater part of its length by the interosseous ligament.

Union with the tibia.

This bone is liable to dislocation, both from violence and from relaxation. I have only seen one case of it from violence, and in that instance it was connected with the compound fracture of the tibia.

Produced by violence or relaxation.

—— Briggs, of whose dislocation of the tibia I have given an account, had, at the upper part of the other leg, a compound fracture of the tibia, and dislocation of the head of the fibula. An attempt was made to save the limb, but the constitutional irritation ran so high, that amputation was obliged to be performed; which was done by my colleague, Mr. Lucas, and the man was restored to health.

Dislocations of the head of the fibula from relaxation, are more frequent than those which occur from violence; the head of the bone, in these cases, is thrown backwards, and is easily brought into its natural connexion with the tibia, but it directly again slips from its position. This state produces a considerable degree of weakness and fatigue in walking, and the person suffers much from exercise. As in these cases there is a superabundant secretion of synovia, and a distention of ligament, repeated

blistering is required to promote absorption; and afterwards a strap is to be buckled around the upper part of the leg, to bind the bone firmly in its natural situation; a cushion may be added behind the head of the bone, to give it support, and at least prevent the increase of the malady.

DISLOCATIONS OF THE ANCLE-JOINT.

Structure of the joint.

THE bones which enter into the composition of the ancle-joint are the tibia, fibula, and astragalus. The tibia forms an articulating surface at its lower part, which rests upon the astragalus; and there is a projection on the inner side of the lower portion of this bone, which forms the malleolus internus, and this part is articulated with the side of the astragalus. The fibula projects beyond the tibia at the outer ancle, and forms there the malleolus externus, which has also an articulating surface for the astragalus. The astragalus, which is the superior tarsal bone, rises between the malleoli and the lower part of the tibia, and moves upon it principally in flexion and extension of the foot.

Bone.

Thus nature has strongly protected this part of the body, by the deep socket formed by the two bones of the leg, and by the ball of the astragalus which is received between them.

Capsular ligament.

A capsular ligament, secreting synovia on its internal surface, joins the tibia and fibula to the astragalus. A strong ligament unites the tibia to the fibula, but without any intervening articular

cavity, as the ligament proceeds directly from one surface of bone and is received into the other.

The peculiar ligaments joining the tibia and fibula to the tarsus, consist of a deltoid ligament, which proceeds from the tibia to the astragalus, os calcis, and os naviculare. The fibula is united at its lower end by three excessively strong ligaments; one anteriorly from the malleolus externus to the astragalus, one inferiorly to the os calcis, and the third to the astragalus posteriorly; and it is the strong union of this bone which leads to its being more frequently fractured than dislocated; and even when the tibia is luxated the fibula is fractured in two of the species of dislocation of the ancle, and generally in all; but when the tibia is thrown outwards I have known the fibula escape a fracture. Peculiar ligaments.

I have seen the tibia dislocated at the ancle in three different directions: inwards, forwards, and outwards; and a fourth species of dislocation is said sometimes to occur, viz., backwards: the foot has also been known to be thrown upwards between the tibia and fibula, by the giving way of the ligament which unites these bones; but this accident is only an aggravated state of the internal dislocation. Directions of dislocations.

SIMPLE DISLOCATION OF THE TIBIA INWARDS.

This is the most frequent of the dislocations of the ancle; the tibia in this accident has its internal malleolus thrown inwards, Dislocation inwards.

which so forcibly projects against the integuments as to threaten
Symptoms. their bursting. The foot is thrown outwards, and its inner edge rests upon the ground. It rotates easily on its axis. There is considerable depression above the outer ancle, much pain, some crepitus, often at three inches from the lower joints of the fibula upwards, facility of lateral motion of the foot, and considerable tumefaction.

Dissection. Upon dissection, the internal appearances are as follows: The end of the tibia rests upon the inner side of the astragalus, instead of resting on its upper articulatory surface; and if the accident has been caused by jumping from a considerable height, the lower end of the tibia, where it is connected to the fibula by ligament, is split off, and remains connected with the fibula, which is also broken from two to three inches above the joint, and the broken end of the fibula is carried down upon the astragalus, occupying the natural situation of the tibia; the malleolus externus of the fibula remains in its natural situation, with two inches of the fibula and the split portion of the tibia; the capsular ligament attached to the fibula at the malleolus externus, and the three strong fibular tarsal ligaments, remain uninjured.

This accident generally happens in jumping from a considerable height, or in running violently with the toe turned outwards, when the foot being suddenly checked in its motion while the body is carried forwards upon the foot, the ligaments on the inner side of the ancle give way; it may also be caused by a fall on that side, when the foot is fixed.

To distinguish a fracture of the fibula, the hand must grasp

the leg just above the ancle, and then the foot must be freely rotated; when, the motion of the foot being communicated to the fibula, pain will be felt, and a crepitus perceived.

For the reduction of this dislocation, which cannot be too soon accomplished, the patient is to be placed upon a mattress properly prepared, and is to rest on the side on which the injury has been sustained; the surgeon is then to bend the leg at right angles with the thigh, so as to relax the gastrocnemii muscles as much as possible; and an assistant grasping the foot, must gradually draw it in a line with the leg. The surgeon then fixes the thigh and presses the tibia downwards, thus forcing it upon the articulating surface of the astragalus. Great force is required if the limb be placed in the extended position, from the resistance of the gastrocnemii; and it is pleasing to observe, after most violent attempts by others, a well-informed surgeon gently bend the limb, and, under a comparatively slight extension, return the parts to their natural situation. Mode of reduction.

When the limb has been reduced it is still to remain upon its outer side in the bent position, with the foot well supported; a many-tailed bandage is to be placed over the part to prevent it from slipping, and this is to be kept wet with an evaporating lotion. Two splints are then to be applied; and each is to have a foot-piece, to give support to the foot, prevent its eversion, and preserve it at right angles with the leg. If much inflammation succeeds, leeches are to be applied to the parts, and the constitution will require relief by taking blood from the arm, and by attention to the bowels; but I shall say no more on this subject until I describe compound dislocation of this joint. A person who Treatment.

has sustained this accident may be removed from his bed in five or six weeks, long straps of plaster being passed around the joint to keep the parts together, and he may be suffered to walk on crutches; but from ten to twelve weeks will elapse before he has the perfect motion of the foot; and much friction and passive motion will be required after the eighth week to restore the natural motion of the joint.

SIMPLE DISLOCATION OF THE TIBIA FORWARDS.

Symptoms. In this accident the foot appears much shortened and fixed, the heel is proportionably lengthened and firmly fixed, and the toes are pointed downwards. The lower extremity of the tibia forms a hard projection upon the upper part of the middle of the tarsus, under the projected tendons, and a depression is situated before the

Dissection. tendon Achillis. Upon dissection the tibia is found to rest upon the upper surface of the os naviculare and os cuneiforme internum; quitting all the articulatory surface of the astragalus, excepting a small portion on its fore part, against which the tibia is applied. The fibula is broken, and its fractured end advances with the tibia, and is placed by its side: its malleolus externus remains in its natural situation, but the fibula is broken about three inches above it. The capsular ligament is torn through on its fore part. The deltoid ligament is only partially lacerated, and the three

Cause. ligaments of the fibula remain unbroken. This accident arises from a fall of the body backwards whilst the foot is confined, or

from that of a person jumping from a carriage in rapid motion with the toe pointed forwards.

The treatment consists in attending to the following rules: The patient should be placed in bed on his back; one assistant grasps the thigh at its lower part and draws it towards the body, another pulls the foot in a line a little before the axis of the leg, and the surgeon pushes the tibia back to bring it into its place. The same principles are held in view in this mode of reduction as in the former, with respect to the relaxation of the muscles. A many-tailed bandage, dipped in an evaporating lotion, must be lightly applied. The local and constitutional treatment is the same as in the dislocation inwards. Reduction. Treatment.

As to position, it is best to keep the patient with the heel resting on a pillow, and to have a splint, properly guarded, on each side of the leg, having foot-pieces to keep the foot well supported at right angles with the leg, so as to prevent the muscles again drawing it from its place. As in five weeks the fibula will be united, there will then be no danger in taking the patient from his bed, and gentle passive motion may be begun.

The application of a long splint on each side, with a foot-piece to each splint, and this padded in such a manner as to give the foot a direction inwards, outwards, or at right angles, according to the direction of the dislocation, answers better than any other mode of securing it. *(See plate.)* When this is applied, the foot cannot escape from the situation in which the surgeon has placed it.

M. Dupuytreer, of the Hotel Dieu, who is a very scientific as well as an excellent practical surgeon, has recommended a single

splint, well cushioned, along the outer or inner part of the leg, according to the direction of the dislocation, and fastened to the leg and foot by bandages. *(See a plate in Johnson's Medico-Chirurgical Review.)*

PARTIAL DISLOCATION OF THE TIBIA FORWARDS.

Symptoms.

This bone is sometimes partially luxated forwards, so as to rest half on the os naviculare, and half on the astragalus. The fibula in this accident is broken; the foot appears but little shortened, nor is there any considerable projection of the heel. The following are the signs of this accident: the foot is pointed downwards, and a difficulty is experienced in the attempt to put it flat on the ground; the heel is drawn up, and the foot is in a great degree immoveable.

Case.

The first case of this kind which I saw was in a very stout lady, who resided at Stoke Newington, and had by a fall, as she said, sprained her ancle. When I examined the limb I found the foot immoveably fixed, pointed downwards, and attended with great pain just above the ancle. I attempted to draw the foot forwards and bend it, but could not succeed. Some years afterwards I saw this lady at Bishop Stortford, walking upon crutches; her toe was pointed, and she was unable to bring any other part of the foot to the ground; the degree of distortion was less than that which occurs in the complete luxation of the bone forwards; but all tension having now been subdued the nature of the injury

was more evident, though I should not have known it decidedly, without an examination of a foot shewn to me by my friend and late apprentice, Mr. Tyrrell, who was so kind as to give me the parts which were taken from a subject dissected at Guy's Hospital. The articular surface of the lower part of the tibia was divided into two; the anterior part was seated upon the os naviculare, the posterior upon the astragalus; these two articulatory surfaces, formed at the lower extremity of the bone, had been rendered smooth by friction. The fibula was found fractured. *(See plate.)* The result of this dislocation clearly proves the necessity which exists in these accidents, however slight they may at first sight appear, of not resting satisfied until the foot be returned into its natural position, and restored to its motion; for, if neglected in the commencement, severe inflammation and tension will prevent even a forcible extension from being afterwards useful; and, if still longer neglected, the changes in the state of the muscles, and the union of the fractured fibula, will preclude the possibility of a reduction, even under the most violent attempts. The mode of reduction and aftertreatment will in no respect differ from that required in the perfect dislocation of the bone forwards, either in regard to the relaxation of the muscles, the bandages, or the local and constitutional treatment.

Dissection.

SIMPLE DISLOCATION OF THE TIBIA OUTWARDS.

This luxation is the most dangerous of the three; for it is produced by greater violence, is attended with more contusion of

the integuments, more laceration of ligament, and greater injury to the bone. The foot is thrown inwards, and its outer edge rests upon the ground. The malleolus externus projects the integuments of the ancle very much outwards, and forms so decided a prominence that the nature of the injury cannot be mistaken. The foot and toes are pointed downwards.

Symptoms.

Dissection.

In the dissection of this accident, it is found that the malleolus internus of the tibia is obliquely fractured, and separated from the shaft of the bone. The fractured portion sometimes consists only of the malleolus, at others the fracture passes obliquely through the articular surface of the tibia, which is thrown forwards and outwards upon the astragalus, before the malleolus externus. The astragalus is sometimes fractured, and the lower extremity of the fibula is broken into several splinters. The deltoid ligament remains unbroken, but the capsular ligament is torn on its outer part. The three fibular tarsal ligaments remain whole in most cases, but when the fibula is not broken they are ruptured. None of the tendons are lacerated, and internal hæmorrhages scarcely ever occur to any extent, as the large arteries generally escape injury. This accident happens either by the passage of a carriage-wheel over the leg, or by a distortion of the foot in jumping or falling.

Reduction.

The mode of reduction consists, in placing the patient upon his back, in bending the thigh at right angles with the body, and the leg at right angles with the thigh; the thigh is then grasped under the ham by one assistant, and the foot by another; and thus an extension is made in the axis of the leg, whilst the surgeon presses the tibia inwards towards the astragalus. The limb,

in the simple dislocation, is to be laid upon its outer side, resting upon splints, with foot-pieces; and a pad is to be placed upon the fibula, just above the outer ancle, and extending a few inches upwards, so as in some measure to raise that portion of the leg and support it; and to prevent the slipping of the tibia and fibula from the astragalus, as well as to lessen the pressure of the malleolus externus upon the integuments where they have sustained injury.

Treatment.

The local and general treatment will be the same as in the former cases, although more depletion is required, as greater inflammation succeeds; the greatest care is necessary to prevent the foot from being twisted inwards, or pointed downwards, as either position prevents the limb from being afterwards useful; and this precaution is effected by having two splints, with a foot-piece to each, padded and applied to the ancle on the outer side of the leg. Passive motion should be given to the joint in six weeks after the accident, when the patient may rise from his bed, and be allowed to walk upon crutches, unless impeded by great swelling of the ancle. In the generality of these cases, from ten to twelve weeks elapse before the cure is complete.

COMPOUND DISLOCATION OF THE ANCLE-JOINT.

These accidents take place in the same direction as the simple dislocations, and the bones and ligaments suffer in the same manner as in those dislocations. The difference, therefore, in these

Opening into the joint.

cases is, that the joint is laid open by a wound in the integuments and ligaments, opposite to the laceration of the skin, by which the synovia escapes, and through which the ends of the bone protrude; this opening in the integuments is generally occasioned by the bone, but sometimes by the pressure of some uneven surface on which the limb may have been thrown.

The bones being replaced by the means which are employed in the simple dislocation, the effects of this accident upon the parts composing the joint are as follows: The synovia, as I have stated, escapes by a large wound through the lacerated ligament,

Local effects.

and in a few hours inflammation begins; and when an additional quantity of blood is first determined to the part, an abundant secretion issues from this membrane, and is discharged through the wound; the ligaments participate in the inflammation, as well as the extremities of the bones which enter into the composition of the joint. The inflammation of the internal secreting surface of the ligament, in about five days, proceeds to suppuration; at first but little matter is discharged, but it continues increasing until it becomes very abundant, and the lacerated parts of the ligaments and periosteum also secrete matter. Under this process of suppuration, the cartilages become partially or wholly absorbed, but in general only partially; for the ulceration of the cartilage is a very slow process, attended with severe constitutional irritation, and often lays the foundation for exfoliation of the extremities of the bones. When the cartilages are absorbed, granulations arise from the surface of the bones and from the inner side of the ligament, and these inosculate and fill the cavity between the extremities of the bones. Sometimes we find after accidents to

joints, that the adhesive process occurs at one part, and that the cartilage is not absorbed; whilst granulations are formed at others, where the cartilage was removed by ulceration; and I have seen, after inflammation in joints, the cartilages remain, and their surfaces adhere.

Neither this inosculation of granulations, nor the process of adhesion, leads to permanent anchylosis; for if passive motion be begun as soon as the parts, from cessation of pain and inflammation, will permit, motion will be restored, not always entirely, but with very little diminution; and the other joints of the tarsus will acquire such an extent of motion as to render the deficiency in the mobility of the ancle-joint but little apparent. The aperture in the ligament is filled by granulations; and with respect to the extremities of the bone, when they are joined by ossific union, this junction is effected by the deposite of cartilage, and by a secretion of phosphate of lime, in the usual manner in which bones are formed and repaired.

Thus, then, the compound dislocation of the ancle leads to inflammation over a very extensive secreting surface; it produces an extended suppuration over the lining of the joint, which occasions much constitutional derangement; and, further, it becomes the source of an ulcerative process, more or less extensive according to the treatment pursued; by which the cartilage is partly or wholly removed, and by which an irritative fever is supported for a great length of time; and the ulceration sometimes extends over the extremities of the dislocated bones, and leads to a greatly augmented constitutional irritation, and protracted disease from exfoliation.

These local effects are accompanied by the common symptoms of constitutional excitement. In two or three days from the accident, or sometimes as early as twenty-four hours, the patient complains of pain in his back and in his head, shewing the influence of the accident on the brain and spinal marrow. The tongue is furred; white, if the irritation be slight; yellow, if greater; and brown, almost to blackness, if it be considerable; the stomach is disordered; there is loss of appetite, nausea, and sometimes vomiting; secretion ceases in the intestines and in the glands connected with them, as the liver, &c.; costiveness is therefore an attendant symptom. The skin has its secretion stopped; it becomes hot and dry; the kidneys also have their secretion diminished; the urine is high coloured, and small in quantity. The heart beats more quickly and the pulse becomes *hard*, which is the pulse of constitutional irritation from local inflammation, and in great degrees of this excitement, it becomes irregular and intermittent; the respiration is quicker, in sympathy with the quicker circulation; the nervous system becomes additionally affected, in high degrees of local irritation; restlessness, watchfulness, delirium, subsultus tendinum, and sometimes tetanus occur. These are the usual effects of local irritation upon the constitution, occurring in different degrees, according to the violence of the injury, the irritability of the system, and the powers of restoration.

Cause of the symptoms.

The causes of the violence of these symptoms are, the wound which is made into the joint, and the great efforts required for its repair: for when there is no wound, and the process of adhesion can unite the part, little local inflammation or constitutional

irritation can occur; and if this be the cause of the violence of the symptoms, the principle in the treatment of this accident is easily comprehended; it consists in closing the wound as completely as possible, to assist nature in the adhesive process by which the wound is to be closed, and to render suppuration and granulation less necessary for the union of the opened joint. Principle of cure.

The first question which arises upon this subject is the following: *Is amputation generally necessary in compound dislocations of the ancle?* My answer is, certainly not. Thirty years ago it was the practice to amputate limbs for this accident; and the operation was then thought absolutely necessary for the preservation of life, by some of our best surgeons; but so many limbs have been saved of late years, indeed, I may say, so great a majority of these cases exists, that such advice would now be considered not only injudicious, but cruel. It is far from being my intention to state that amputation is never required; I have only to observe, that in the greater number of these accidents the operation is unnecessary. Is amputation required?

But before I give the proofs of what I have advanced, I shall state the mode of treatment which is to be pursued in these cases.

When the surgeon examines the limb, he finds a wound of greater or less extent, according to the degree of the injury. The extremity of the tibia projects if the dislocation of the tibia be inwards; and the tibia and fibula are protruded, if the dislocation of the former be at the outer ancle. The ends of the bones are often covered with dirt from their having reached the ground. The foot is loosely hanging on the inner or outer side of the leg, according to the direction of the dislocation. Sometimes, though Treatment.

Artery divided. very rarely, a large artery will be divided; and it is surprising that the posterior tibial artery so generally escapes laceration; the anterior tibial being the only vessel I have known to be torn. The arrest of hæmorrhage is the first object; and for this purpose, if the anterior tibial artery be wounded, it must be secured by ligature. The extremity of the bone is to be washed with warm water, as the least extraneous matter admitted into the joint will produce and support a suppurative process; and the utmost care should be taken to remove every portion of it adhering to the end of the bone.

Loose pieces of bone. If the bone be shattered, the finger is to be passed into the joint, and the detached pieces are to be removed; but this is to be done in the most gentle manner possible, so as not to occasion unnecessary irritation. If the wound be so small as to admit the finger with difficulty, and if small pieces of bone can be felt, the integuments should be divided with a scalpel, to allow of such portions being removed without violence; the incision should be so made as to leave the joint with as much covering of integument

Integuments as possible. The integuments are sometimes nipped into the joint by the projecting bone; and then it cannot be reduced without making an incision, to allow the skin to be drawn from under the bone; and when the edges of the incised wound are afterwards brought together, no additional evil arises from the extension of the wound.

Reduction. The mode of reducing the bone is, in other respects, similar to that which I have already described when speaking of simple dislocation; by bending the leg upon the thigh, so as to relax the muscles before the extension is made. When the bone has been

reduced, a piece of lint is to be dipped in the patient's blood, and applied wet over the wound, upon which the blood coagulates, and forms the most natural, and, as far as I have seen, the best covering for the wound. A many-tailed bandage is then applied, the portions of which should not be sewn together, but passed under the leg, so that any one piece may be removed when it becomes stiff; and by fixing another to its end, the application may always be renewed without any disturbance to the limb: this bandage is to be kept constantly wet with spirits of wine and water. A hollow splint, with a foot-piece at right angles, is to be applied on the outer side of the leg, in the dislocation inwards, and the leg is to rest upon its outer side: but in the dislocation outwards, it is best to keep the limb upon the heel, with a splint and foot-piece both upon the outer and the inner side; and an aperture in the splint opposite to the wound.

In each dislocation the patient's knee is to be slightly bent, to relax the gastrocnemius muscle. The foot must be carefully prevented from being pointed; great care being taken to preserve it at right angles with the leg, otherwise the limb will be useless when the wound is healed. The patient is to be placed on a mattress, and a pillow is to reach from half way above the knee to beyond the foot, and another is to be rolled under the hip, to support the upper part of the thigh-bone.

Constitutional treatment.

Blood-letting must be adopted, or not, according to the powers of the constitution; as it is necessary to bear in mind that the patient has a great trial of his powers to undergo, and will require throughout the process of restoration, all the support which his strength can receive. Purgatives must also be used with the

Blood-letting.

Purging.

utmost caution, for there cannot be a worse practice, when a limb has been placed in a good position, and adhesion is proceeding, than to disturb the processes of nature by the frequent changes of position which purges produce; and I am quite sure, that in cases of compound fracture, I have seen patients destroyed by their frequent administration. That which is to be done by bleeding, and emptying the bowels, should be effected as soon as is possible after the accident, before the adhesive inflammation arises; after which the liquor ammoniæ acetatis, and tinctura opii, form the patient's best medicine, with a slight aperient at intervals.

Secondary treatment.

If the patient complain of considerable pain in the part, in four or five days, the bandage may be raised to examine the wound; and if there be much inflammation, a corner of the lint should be lifted from the wound, to give vent to any matter which may be formed; but this ought to be done with great circumspection, as there is a danger of disturbing the adhesive process, if that be proceeding without suppuration. By this local treatment, it will every now and then happen that the wound will be closed by adhesion, but if in a few days it be not, and if suppuration take place, the matter should have an opportunity of escaping; and the lint being removed, simple dressing should be applied. After a week or ten days, if there be suppuration with much surrounding inflammation, poultices should be applied upon the wound, leeches in its neighbourhood, and upon the limb at a distance, and the evaporating lotion should be still employed; but as soon as the inflammation is lessened, the poultices should be discontinued, as they encourage too much secretion, and relax the blood vessels of the part, so as to prevent the restorative process.

If the cure proceeds favourably, in a few weeks the wound is healed with little suppuration; if less favourably, a copious suppuration takes place, the wound is longer in healing, and exfoliation of portions of the extremity of the bone still further retards the cure. The motion of the joint is not always lost; it is sometimes in a great degree restored: but this depends upon the greater or less extent of suppuration or ulceration. Under the most favourable circumstances, three months generally elapse before the patient can walk with crutches; in many cases, however, a greater length of time is required: he bears upon the foot at different periods of time, according to the degree of injury sustained, as in compound fracture, when adhesion is not at first produced: in compound dislocations, of course, the patient is longer in recovering. Result.

I shall now proceed to state the cases which have induced me to say that amputation, as a general rule, is improper in these cases.

The circumstances which led me to doubt the soundness of the opinion which recommended an indiscriminate amputation of these injuries, were these:

CASE I.

I was, many years since, going into the country with a friend of mine, and we met with a surgeon in our journey who put this question: "What do you do in compound dislocations of the ancle-joint?" I do not recollect the reply, but he proceeded to say, "I have had a case of compound dislocation of the ancle-joint under my care, in which I told the patient he must lose his limb: not approving this advice, his friends sent for another

surgeon, who said he thought he could save it; the patient placed himself under his care, and the man is recovering."

About thirty years ago, I received from Mr. Lynn, of Woodbridge, now Dr. Lynn, of Bury St. Edmunds, the astragalus of a man broken into two pieces, which he had taken from a dislocated ancle-joint. His letter is as follows:

CASE II.

Dear Sir,

J. York, aged thirty-two years, being pursued by some bailiffs, jumped from the height of several feet to avoid them. The tibia and a part of the astragalus protruded at the inner ancle. I immediately returned the parts into their natural situation. Suppuration ensued; and in five weeks a portion of the astragalus separated, and another piece a week afterwards, which, when joined, formed the ball of that bone. In three months, the joint was filled with granulations; it soon afterwards healed, and the man recovered with a good use of the limb.

Your's, &c.

James Lynn.

I attended a compound dislocation of the ancle-joint, in the year 1797, with Mr. Battley, who then practised as a surgeon in St. Paul's Church-yard, and is now an eminent chemist and druggist in Fore Street. An account of this case I shall give in the words of Mr. Battley.

CASE III.

In the month of September, 1797, a gentleman, lodging in Duke-street, Smithfield, in a fit of insanity, threw himself from a two-pair of stairs window into the street, his feet first reaching the ground. He rose without help, knocked violently at the outer door of the house, and ascended the stairs without the least assistance; bolted the door after him, and got into bed. He refused to open the door, and it was obliged to be forced. A neighbouring surgeon was sent for, who, on viewing the case, proposed an immediate amputation, which was not acceded to by his friends; but Mr. Cooper and myself were requested to take charge of the case. On examination, there was found a compound dislocation of the ancle-joint. The tibia was thrown on the inner side of the foot; and when the finger was passed into the wound, the astragalus was discovered to be shattered into a number of pieces. The loose and unconnected portions of bone were removed, and the tibia was replaced; after which, lint, dipped in the oozing blood, was wrapped around the lacerated parts, and the limb was placed on its outer side, with the knee considerably bent. The parts were ordered to be kept cool by the frequent application of evaporating lotion.

Accompanied with insanity.

The patient remained as quiet as could be expected from a person in his state of mind, until the third or fourth day, when a considerable inflammation appeared in the joint, and greatly increased the previous irritable state of his constitution. Leeches, fomentations and poultices were applied to the limb, blood was taken from the arm, purgative medicines were given, and afterwards saline medicines with sudorifics. Extensive suppuration

ensued, and continued for six weeks or two months, when it began to lessen, and healthy granulations appeared on the whole wounded surfaces; about this time the state of his mind began to improve, and it continued to amend as his leg advanced in recovery. At the end of four or five months the suppurated parts had filled up, the joint healed, and his mind recovered its natural tone. At the end of nine months he returned to his employment, but the ancle joint was stiff. In two years he had so far recovered as to walk without the aid of a stick, and at the end of three or four years was able to pursue his avocations nearly as well as at any former period of his life.

Mental symptoms improve.

RICHARD BATTLEY.

COMPOUND DISLOCATION OF THE TIBIA INWARDS.

CASE IV.

I was sent for on August the 11th, 1814, by Mr. Richards, of Seale, in Kent, to visit Mr. Knowles, a farmer, residing at Tytham Farm, aged forty-eight, who, having been thrown from his chaise against the hinder wheel of a waggon, had dislocated the tibia inwards, and fractured both the tibia and fibula.

Mr. Richards, who was immediately called to the case, reduced the dislocation, and endeavoured to heal the wound by adhesion. When I saw Mr. Knowles, which was ten days after the accident, the wound wore a favourable aspect. The discharge was abundant, but not in a degree to excite alarm, and all I had to do was, to praise the judgment which had led to the preservation

of the limb, and to direct the continuance of the means which had been employed for that purpose.

Before I ventured to state the case to the public I wrote to Mr. Richards, who informed me that Mr. Knowles's wound was perfectly healed, and that he walks without the use of a stick.

COMPOUND DISLOCATION OF THE TIBIA OUTWARDS.

For the following details I am obliged to Mr. Rowley, apprentice to Mr. Chandler, Surgeon at St. Thomas's Hospital.

DEAR SIR, CASE V.

In answer to your inquiries, I beg leave to forward you the particulars of Elizabeth Chisnell's case, who was admitted into St. Thomas's Hospital, on Saturday, May 29th, 1819, with a compound dislocation of the left ancle-joint outwards, occasioned by her slipping from the foot-path into the road-way. The wound communicating with the joint was situated upon the outer part of the leg, and was about four inches in extent, through which the fibula projected two inches, but it was not fractured; the ligaments connecting the malleolus externus and the astragalus were lacerated. From the inclination of the sole of the foot inwards, the whole articulating surface of the joint was so displaced as to allow two fingers to pass readily across; and on examination, I found the extremity of the tibia fractured. The parts were easily

returned to their original situation by extending the foot, the leg having been first bent upon the thigh. During the reduction, the integuments became confined between the malleolus externus and the astragalus, so as to require an incision upwards by the side of the fibula, to accomplish the extrication; that being effected, its lips were brought together by four sutures, and straps of adhesive plaster. Splints were applied; and, to subdue the consequent inflammation, the common application was used.

Integuments confined between the bones.

June 1. The adhesive plaster and sutures were removed, because the wound and adjacent soft parts around the ancle were in a sloughing state. Poultices of linseed meal were ordered to be used daily.

June 5. The sloughs are separated; the sore is granulating; the discharge profuse. A collection of matter has formed upon the inside of the leg, which was discharged by puncture. The wound was ordered to be dressed, and a roller was gently applied. The constitution during this time was but little affected. Bark and porter were ordered by Mr. Chandler.

August 7. The wounds are almost healed. The girl sits up daily, and in a few days she will be allowed to walk.

During the progress of her cure, the constitutional disturbance has been trifling, indeed, not more than in some favourable cases of simple fracture: it may be also well to observe that her bowels were regular during the whole time, so as to preclude the necessity of any laxative medicine, nor did she take any other medicine than the bark.

I remain, &c. &c.

Southwark. R. Rowley, Surgeon.

COMPOUND DISLOCATION OF THE TIBIA INWARDS.

The following accident I was requested to visit, by Mr. Clarke, surgeon, Great Turnstile, Lincoln's Inn Fields, who has had the kindness to send me the particulars.

CASE VI.

Mr. George Caruthers, aged twenty-two years, had a compound dislocation of the ancle-joint inwards, with fracture of the tibia, on October the 6th, 1817. The accident was occasioned by the overturning of a stage-coach at Kilburn, from whence he was brought to his house at Lambeth. The end of the tibia projected through the integuments of the inner ancle, to the extent of from two by three inches, and the bone was tightly embraced by the skin. The tibia was fractured, only a small portion of it remaining attached to the joint; the bleeding was stated to have been copious, but it had subsided before Mr. Clarke saw him. The fibula was badly fractured.

For the reduction of the protruded parts it became necessary to make an incision in the integuments, to loosen them on the tibia; and when the bone was restored to its place, simple dressings were spread over the wound. A many-tailed bandage, wetted with an evaporating lotion, and splints, were applied, and the limb was placed in the slightly bent position upon a quilted pillow. Bleeding was employed, gentle purgatives given, and saline medicines. Symptoms of great constitutional excitement naturally arose

from so severe a local injury. Abscesses formed on the leg, and some exfoliations materially retarded the cicatrization of the wound, producing also considerable exhaustion of the patient's strength. Openings were made into the abscesses, adhesive straps were placed over the wounds, and lotions were applied on linen, under oiled silk, which preserved the parts constantly wet. Bark and wine were given with occasional aperients. Mr. Caruthers left town on October the 6th, 1818, having then a small opening on each side of the limb, and suffering occasional pain, but his general health had been good for some months previous. In January last, a considerable portion of bone came away, and the sore immediately healed and has so continued; he has been ever since free from pain, and is now in better health than before the accident. He employs himself in superintending a farm, around which he walks with one crutch and a stick, but if the ground be level, with a stick only; and the limb is becoming daily more and more useful.* THOMAS CLARKE.

Constitutional treatment.

To Mr. Somerville, of the Stafford Infirmary, I am indebted for the following letter:

CASES VII. and VIII.

DEAR SIR,

I take shame to myself for not having answered your obliging

---

* In June, 1822, I wrote to Mr. Caruthers to inquire how he proceeded, and his answer was, that he could walk three or four miles easily, and eight if required; and that he would not exchange his injured leg for a wooden one for the whole of Europe.

queries sooner, as to the cases of compound dislocation of the ancle which have fallen under my care; but the fact is, I wished to give you my answer in the most authentic form by sending you a transcript of the cases from the minute books of the Infirmary; but after having caused the most diligent search to be made for them, I have now the mortification to learn that they are no where to be found: you will allow me therefore to plead this circumstance as the real cause of my seeming inattention to your wish, and at the same time to offer it as an apology for the want of a more detailed account. I have a distinct recollection of two cases, though not of the manner in which the accidents were produced. The first occurred about fifteen years ago, the other a few years later: they where both dislocated inwards, and were both discharged cured; the one at the end of the fifth, the latter not till the seventh week. In the first case the wound, which was lacerated so as to form a flap, healed by the first intention; in the latter it was kept open by the discharge, which was at first purulent, afterwards limpid; but no untoward symptom supervened during the cure. The treatment in both cases was as follows:

After the reduction of the bone the patient was placed upon his side, with the limb in a bent position; no ligature was used, but the lips of the wound were nicely approximated, and retained *in situ* by straps of sticking plaster, of ample length, yet not sufficient to encircle the limb, lest they should, by causing undue pressure on the supervening tension, excite too much inflammation, and, in consequence, suppuration. To obviate, however, both tension and inflammation as much as possible, a plaster, spread moderately thick with Kirkland's defensative, was placed round

Use of adhesive straps.

Kirkland's defensative.

and in easy contact with the ancle, and over the whole a tailed bandage was loosely applied. A brisk purgative was given on the following morning, and low diet was ordered till all danger of inflammation was over. The adhesive plaster was removed on the second or third day, and was not renewed; but a pledget of melilot digestive was placed over the wound, and the defensative bandage applied as before. The subsequent treatment consisted merely in the daily renewal of the pledget, and the proper adjustment of the plaster and bandage, both of which were gradually drawn tighter round the limb, in proportion as the danger of inflammation became less, and this operation was performed with the view not only to give stability to the joint, but also to facilitate the progress of cicatrization.

The use of the plaster after the manner above mentioned, may, at first, appear to you a singular practice, but, by being spread very thick, it seldom requires a renewal during the period of cure; unless the discharge from the wound should be so great as to render a change necessary; but if it should not, it will appear obvious that there can be no necessity for disturbing or moving the limb from its original position, the retention of which I have ever considered, in cases both of compound dislocations and compound fractures, of the highest importance to facilitate the cure. The plaster is composed of two parts of emp. plumbi, and one each of oil, vinegar, and chalk finely powdered; and I have ever found it a most powerful repellent in all cases of violent local inflammation.

I am, dear Sir, very respectfully,

Your obliged and most obedient Servant,

Stafford, Aug. 31, 1819. HENRY SOMERVILLE.

COMPOUND DISLOCATION OF THE TIBIA OUTWARDS.

The following case I received from Mr. Scarr, surgeon, of Bishop's Stortford.

CASE IX.

Dear Sir,

John Plumb, the subject of the following statement, was in the thirty-eighth year of his age when his accident took place, which was about seven years ago. He was in the act of ascending a ladder with a sack of oats on his shoulders, and had mounted ten feet from the ground, when the ladder slipped from under him, and he was precipitated to the ground, lighting on his feet, but still sustaining the sack of oats on his shoulders. I was passing about two hundred yards from the place at the moment when the accident happened, and was, consequently, in immediate attendance. On the removal of his stocking, I found that the tibia and fibula had penetrated through the integuments at the outer ancle, and were lying on the outside of the foot; the articulatory surface of the astragalus had penetrated through the integuments of the inner ancle, shewing, on a view of the case, the foot nearly reversed, the bottom of the foot being placed where the side of the foot is naturally situated. The wounds through which the surfaces of the bone had penetrated being free, soon determined me in the line of conduct I should pursue, viz., to immediately reduce the joint to its natural situation with as little violence as

possible, and which was effected with much less difficulty than I expected; the wounds were brought close by adhesive straps, the limb placed on its outer side, and cloths applied constantly moistened with lotion of acetate of lead; the patient was then bled to about sixteen ounces; a saline diaphoretic mixture was given, and attention was paid to his bowels; in short, the antiphlogistic plan was persevered in with due regard to his constitutional powers: abscesses took place which were opened in the most favourable points, and after five and twenty weeks the man was convalescent; union of the articulatory surfaces took place, the wounds healed, and the patient became able to walk; he could not bear much on his foot to work till about twelve months after the accident, from which time he has constantly been labouring in his situation with Mr. Starkis, a gentleman of respectability of this town, and continues to do so at this time.

It is my intention to send this man up to you, that you may have a full confirmation of the accident from him, as well as from Mr. Cribb, my present assistant, who was present at the time of my being called to him, being at that time with his father, Mr. Cribb, surgeon, of this town, whom I consulted on the case at the time of the accident, as well as during its continuance. Trusting that the statement and result may prove satisfactory to your inquiry,

I am, dear Sir,

Your most obedient,

August 16*th*, 1819. R. T. Scarr.

P. S. I hope Mr. Cribb and the man will be with you the beginning of the next week.

This man was sent to town, and I had an opportunity of witnessing the happy result of Mr. Scarr's skill and attention.

A. C.

COMPOUND DISLOCATION OF THE TIBIA INWARDS.

For the following most interesting case I am indebted to a very excellent surgeon and ingenious man, Mr. Abbott, at Needham Market, Suffolk. It is an admirable proof of what may be accomplished in these cases by extraordinary skill and attention.

CASE X.

April 25, 1802, Mr. Robert Cutting, a butcher by trade, near seventy years of age, corpulent, very intemperate, and subject to gout from his youth, in a dispute, when in a state of intoxication, was thrown violently to the ground, and suffered a compound dislocation of the tibia at the ancle-joint; the end of it was forced through the integuments nearly four inches; the wound was large and semi-circular; in the struggle to stand erect, he rested his weight upon the end of the bone, which was covered with sand and dirt; the cavity of the articulating surface of the joint was filled with blood and sand, the fibula fractured a few inches above the joint, and the foot completely turned outwards; in this state he was placed in an open cart, full four miles from his residence, Somersham, in Suffolk, about seven miles from Ipswich. It was near five hours from the time the accident took place, before

surgical assistance arrived, in the middle of a cold night. I attended with a well informed pupil of mine, Mr. John Jefferson, who has now resided many years at Islington. A case so formidable, a large wound, the connecting ligaments lacerated, the surfaces of the articulating parts long exposed and much injured, led me to conclude, that it would be impossible to save the limb, in a constitution so disordered; however, no persuasion could prevail with a mind obstinate and inflexible; he would not submit to amputation. The surfaces were, as carefully and expeditiously as possible, made clean with warm water; the reduction was easily accomplished, the lacerated parts properly placed, and the edges of the wound nearly brought in apposition, without stitches or adhesive plasters; the limb was laid upon a proper sized thin board, excavated so as to take the form of the leg, with an opening to receive the outer ancle; this was well padded, the foot-part raised somewhat higher than the leg; plaits of lint, wetted with the tinctura benzoini composita, were placed over the wound, which, in a few hours, formed a hard sealed cap, of a circumference that effectually excluded the air; a folded flannel bandage was applied over the limb from the foot to the knee; and the leg was laid in a flexed position. V. S. ʒ xij. A saline purge was given every two hours until his bowels were relieved; milk broth only was allowed for his support.

Amputation refused.

Sixteen hours after the dressing his bowels had been properly evacuated, and he was tranquil. Heat moderate; a moisture was spread over the whole surface; pulse 86; and he had some hours of refreshing sleep.

April 27th. A little heat was raised; sleep interrupted; pulse

96; surface moist; darting uneasiness about the ancle and foot; no thirst; bowels kept cool, and the same support continued: common saline medicines were resorted to every three hours. Upon unfolding the flannel some swelling appeared to surround the ancle: a little gleety discharge had escaped from beneath the lower part of the dressing. The inflammation did not appear to be more than might be wished. Lint, wetted with the tincture, was applied so as to prevent the escape of any discharge; and to seal the covering more securely, six leeches were applied at a small distance from the inflamed part: the wounds bled freely, and afforded ease.

April 29. He passed a good night; heat lessened; free from thirst; limb easy without tension; and the inflammation about the ancle abated.

April 30th. A quiet, good night; and every symptom appeared favourable.

May 2nd. The pulse had regained the natural standard. Upon examining the ancle, a small quantity of pus escaped from the lower part of the dressing. Lint, wetted in the same manner, to glue the covering securely, was used. From this time my visits became less frequent. The tincture was used whenever the surface of the cap appeared to lose its hold. At the end of ten weeks he was taken from his bed daily, and laid upon a sofa. After the first stage of symptoms, healthy actions were established, and he became perfectly healthy. Between the third and fourth month the cap or dressing was taken from the ancle; the wound was completely cicatrised; a small abraded surface appeared over the

cicatrix, occasioned by incrusted matter. Simple dressings rendered the wound sound and well in a few days. During the time of the curative process the fætor was very trifling. The thickening upon the wound was not more than might have been expected: the form of the joint was natural, and bore the appearance of being perfect. At the end of five months he was allowed to go on crutches, to place the foot on the ground, and to use such weight or pressure as his feelings could admit. For many months an application of oil, obtained from the joints of animals, was made night and morning, for an hour each time, by friction; and to please himself, the patient plunged his foot and ancle in the paunch of an ox. With these means an imperfect motion in the joint was recovered, and within twelve months he could walk without a stick; he pursued his occupation, and lived to the age of eighty-three. The last ten years he was able to walk as well as ever he could. Mr. Jefferson will be able to confirm this statement.

Since the case of Cutting, I have uniformly, in a variety of compound fractures, followed the curative plan of treatment by the first intention. Mr. George Lynn, of Woodbridge, my son-in-law, a deserving character in his profession, and the late Launcelot Davie, of Bungay, were pupils of mine, and attended many cases with me of a very formidable nature, successfully treated by the same means. A compound fracture of the thigh, attended with considerable comminution of the bone, occasioned by a waggon, loaded with twenty-five combs of barley, passing

over it, was perfectly restored by the same treatment, within six months.

With the greatest esteem,
I have the honour to be,
Your very much obliged,
Needham Market, And faithful Servant,
Suffolk. ROBERT ABBOTT.

COMPOUND DISLOCATION OF THE TIBIA OUTWARDS.

To Mr. Ransome, surgeon at Manchester, I am indebted for the following case:

CASE XI.

DEAR FRIEND,

In reply to thy letter, requesting to know the result of my experience in cases of compound dislocation of the ancle-joint, I have great pleasure in stating the following case, which has recently occurred. I take the liberty of briefly describing it, as there were some circumstances connected with it which did not afford the most flattering prospect.

In the autumn of last year, a female, aged about forty-five years, of a strumous and leucophlegmatic habit, having a troublesome cough and occasional dyspnœa, fell from a high stool, and pitching upon the left foot, caused a compound dislocation of the ancle-joint; the foot was luxated inwards; the external malleolus was fractured; a lacerated wound extended half round the joint, Case in a strumous habit.

and exposed the protruding portion of the malleolus, laying the cavity of the joint so open as freely to admit the finger; and through it the synovial fluid escaped. I removed a portion of detached bone, reduced the dislocation, and brought the integuments together very slightly; the limb was laid upon the side, and kept constantly cool with the saturnine lotion combined with the liq. ammon. acet.; a small opiate, and a demulcent mixture were given at intervals. From the constitution of my patient, I must confess I feared the most serious consequences; but I was happily mistaken. Little inflammation followed, the wound healed without a copious suppuration, and she is now perfectly recovered, and walks to considerable distances. She was confined in a very small room, and in a part of the town not very famous for the purity and salubrity of its atmosphere.

Manchester, I am, &c. &c.
October 22, 1818. T. A. Ransome.

COMPOUND DISLOCATION OF THE TIBIA INWARDS, AND FRACTURE OF THE THIGH.

To Mr. Chandler, of Canterbury, Surgeon to the Kent and County Hospitals, I am obliged for the following communication.

CASE XII.

My Dear Sir, *Bengal Street, Canterbury.*

I take the earliest opportunity of complying with your request, to furnish you with the result of my observations on compound dislocation of the ancle-joint.

You will, perhaps, think it singular, that this division of Kent, which our hospital practice embraces, should be so destitute of cases giving rise to accidents of this nature, that only two have occurred, either in my private practice, or at our hospital, or to my coadjutor, Mr. Fitch, during the last fifteen years; and as these are the only instances, I fear it would be deemed presumptuous in me to form an opinion upon the method to be adopted, and the probable termination of the generality of accidents of this nature. The favourable result, however, of these two cases, admitted under my care in the Kent and County Hospitals, was so firmly impressed on my memory, as to confirm unequivocally the precepts you early inculcated, to save the limb if possible in compound dislocations of the ancle-joint. In accomplishing so desirable a point, the advantages obtained in a country hospital, will, I apprehend, bear a great proportion in the scale of success, compared with the circumstances of a patient placed in a crowded infirmary of a large manufacturing town, or in the metropolis; the constitution will, in general, be less impaired by excess, poverty, and other evils; whilst purity of air in large ventilated wards will materially contribute towards recovery, even if the injury to the joint be extensive; we consequently can be permitted to take greater latitude with our curative means upon an injured joint, relying on the powers of nature, without being under the immediate necessity of anticipating the issue resulting from unfavourable habits, and in situations inimical to disease.

My notes furnish me only with the brief details of one case.

July, 1818. A bricklayer, aged thirty-six, of slender make, but of good constitution and of sober habits, fell from a height of

between thirty and forty feet upon loose materials for building, and alighting upon his feet, received a very severe shock, attended with comatose symptoms, a fracture of the right thigh, a considerable contusion and laceration of the left ancle-joint, accompanied with a dislocation of the bones inwards, the tibia resting upon the inner side of the astragalus; a portion of the lower extremity of that bone was fractured, and the fibula was broken about three inches above the malleolus externus, and the surrounding ligaments of the joint were lacerated; little difficulty was found in reducing the dislocation, and in replacing the fractured bones; but in consequence of the violent injury done to the joint, a question arose on the propriety of amputation. As the man had enjoyed uninterrupted health, and was of the constitution and habit least liable to the attack of inflammatory affection, I ventured to give him a chance of saving the limb. An union by the first intention of the external wound, as far as practicable, was attempted, and the limb was laid in the most convenient, yet relaxed and easy posture. Evaporating lotions were applied, and the strictest antiphlogistic system enjoined.

Considerable inflammatory symptoms ensued, with a copious discharge of synovial fluid; the limb and joint were much swollen, and it became necessary to vary the treatment by applying warm spirituous and opiate fomentations and poultices, which appeared more genial to the patient's feeling, and were therefore continued.

Disposition to gangrene. A disposition of the contused parts to gangrene appearing,

Use of muriatic acid. muriatic acid was added to the cataplasm, and the medicines were changed according to the effect produced on the constitution by symptomatic irritation accruing from the discharge. The

disposition to gangrene ceased soon after the application of the muriatic acid: from this medicine I have often derived, in similar circumstances, great advantage. After the first fortnight, my hopes of saving the limb were confirmed by the abatement of pain and swelling, and by the mitigation of the constitutional symptoms, the colour of the discharge improving, with less synovia, and granulations arising round the wound. The patient continued gradually to improve till about the tenth week, when the wound was nearly healed. This man was discharged in fourteen weeks quite well, although with rather an unsightly and partially stiff joint.

The other case, of which I have notes, was also a compound dislocation of the ancle-joint, but without the degree of injury sustained in the former; this patient was also discharged cured.

I have now to apologize for trespassing upon your time, in the attempt to give you the details of cases that might have been interesting if not so curiously drawn up; but as my notes were only penned to furnish me with hints for the future, from the distance of time, the minutes have escaped my memory, and I doubt that they are too inaccurate and too inconclusive to afford you any information; but the occasion serves me as a pretext for assuring you how much

I remain,
My dear Sir,
Your very faithful and obliged Servant,
W. Chandler.

Royal Navy Hospital, Plymouth,
August 11, 1819.

My dear Sir,

In answer to your letter inquiring of me whether I had had any cases of compound dislocation of the ancle-joint, with their treatment and their result, I beg leave to acquaint you, that several of the above nature have fallen under my care and observation, during the eight years I served as assistant-surgeon, and the sixteen years I have been the first surgeon of this hospital; during nearly the whole of which period the country was engaged in active naval warfare, and, consequently, this hospital was in the constant receipt of important surgical cases; and I have also witnessed a few more from other causes. The result of my observations have been, that in cases of compound dislocation of the ancle-joint there is not only a chance of saving the limb, but of that limb being at a future time useful. The dislocated bones should be replaced in their situation with as little violence and injury as possible to the surrounding parts; and should any difficulty arise in returning the bones, from the smallness of the wound, I freely enlarge it with a scalpel. After they are replaced, I lay the limb perfectly extended on very soft cushions of lint arranged on three pillows, the centre one reaching the length of the leg, the upper one crossing under the ham and inferior part of the thigh, and the lower one crossing under the heel, having previously placed on these pillows a fine sheet, folded so often that when its edges are turned in, it may protect the limb from the pressure of the splints; under this sheet are laid several slips of calico, about eighteen inches long and three broad. When the

limb is thus comfortably placed, taking care to fill up every hollow with lint, I draw the edges of the lacerated integuments as near together as they can be brought by the gentlest means, retaining them with small slips of adhesive plaster, and covering this with pledgets of soft lint; this done, I direct the foot to be kept very steady, whilst I ultimately place the slips of calico, already described, over the whole length of the extremity, draw up the edges of the sheet, and apply on each side of the leg, outside of all, a very broad splint of common deal, of such length as to reach at least three inches below the foot, and as far above the knee-joint; these splints are well covered with lint, and then so secured as to afford support (but no pressure) to the whole of the leg and foot, the breadth of the splint materially contributing to the latter purpose, and allowing the tape to pass around the limb without injury. The foot ought also to be prevented from dropping or altering in the least its position, by passing a broad tape through a hole in the lower ends of the splints, which tape is to be tied, securing between it the sole of the foot, which will effectually keep it up, and securing it further by a stirrup bandage; when every thing is thus accomplished, the foot and leg are directed to be kept constantly wet with cold water, taking care not to sponge it immediately over the wound. The subsequent treatment of the patient must depend upon the symptoms which arise. This is the plan I pursue in those cases where there is a probability of saving the limb. I have seen more than one case, where, after great perseverance and risk, the limb has been saved, but when the wounds were all healed, has been found of little or no use; as an example, a man who had had a compound dislocation of the ancle

in the West Indies, from whence he was sent to England as an invalid, became my patient in this hospital, and when received, a period of thirteen months from the accident, had the whole of the lower head of the tibia (although in its proper situation) exposed, black, and carious, which at the end of a year and a half came away, more than three inches in length; and at the expiration of three years and a half from the injury, he quitted the hospital, with the wound healed, but with a shortened, deformed, and anchylosed leg, liable to break out on the slightest injury. The great question to be decided, however, in these accidents is, in what cases the surgeon is justified in attempting to save the limb, and in what cases immediate amputation is necessary. From all I have seen, I should not hesitate to advise the immediate removal of the limb, where the lower heads of the tibia and fibula are very much shattered; where, together with the compound dislocation of these bones, some of the tarsal bones are displaced and injured; where any large vessels are divided and cannot be secured, without extensive enlargement of the wound and disturbance of the soft parts; where the common integuments, with the neighbouring tendons and muscles, are considerably torn; where the protruded tibia cannot by any means be reduced; where the constitution of the patient is enfeebled at the time of the accident, and not likely to endure pain, discharge, or long confinement.

I have a fine specimen of injury done to the tibia, fibula, and tarsal bones, from a compound dislocation, requiring amputation ten months after the accident, which occurred in the Mediterranean; it is very much at your service to see or copy, but I must beg of you to have the goodness to return it, as it forms

part of a collection of bones which I have been forming for the last twenty years. *(See plate.)*

I am, &c. &c.

STEPHEN L. HAMMICK.

I beg Mr. Hammick to accept my thanks for his excellent letter.

The following case shews that under the most unfavourable circumstances, these injuries are not destructive of life, in persons of good constitutions.

CASE XIII.

Winchester, August 1st, 1819.

MY DEAR SIR,

In answer to your inquiries of my practice in compound dislocations of the ancle-joint, I can only say, that in almost every case that I have witnessed, the general injury has been so great as to require amputation. I recollect but one case in which amputation was not necessary; it was that of a patient at a distance, to whom I was called by a neighbouring practitioner about five weeks after the accident, " to reduce a dislocation of the ancle, as he had reduced the fracture of the fibula." I saw the patient, but the fractured fibula was so firmly united, that a reduction could not be attempted; the compound dislocation gradually got well, if you can call the greatest deformity I ever saw, well; however, no bad symptoms arose, and I am persuaded, that had the dislocation been at first reduced, the case would have terminated in a most satisfactory manner.

I had a case of compound fracture of the elbow-joint, in the person of Dr. Wool, now head master of Rugby, which did well, without leaving any perceptible degree of stiffness.

I remain, my dear Sir,

Your's very truly,

W. Wickham.

28, *Park Street, Bristol;*
October 20th, 1818.

My dear Sir,

During the twenty-two years I have been Surgeon to the Bristol Infirmary, and I believe during my apprenticeship there, making in all nearly thirty-years, it has been our invariable practice to endeavour to save the limb in cases of compound dislocation of the ancle, unless where the chance was annihilated by some concomitant injuries or circumstances; but as a general rule it was always adhered to, which it would not have been unless the great majority of cases had done well. We save the limb in private practice almost invariably, unless in very bad cases indeed.

I am, my dear Sir,

Your's, &c.

R. Smith.

COMPOUND DISLOCATION OF THE TIBIA INWARDS.

My friend, Mr. Fiske, surgeon at Saffron Walden, stated to me the following case:

CASE XIV.

A man, aged sixty, had ascended a ladder to a considerable height, when, accidentally slipping, he fell to the ground. Mr. Fiske being called to him, found the tibia dislocated inwards at the ancle-joint, and the end of the bone, covered by its cartilage, protruding through the integuments. He immediately replaced the bone, brought the integuments together by adhesive plaster, applied a bandage over the joint, and splints upon the limb, directing him to remain as quiet as possible. The wound healed without any untoward circumstance, and the man not only recovered, but has obtained an extremely useful limb.

COMPOUND DISLOCATION OF THE TIBIA FORWARDS, AND TWO CASES OF THE TIBIA OUTWARDS.

I have received the following cases of injury to the ancle from Mr. Maddocks.

CASE XV.

Dear Sir,

These cases are of recent date, and I have a perfect recollection of every important circumstance connected with them.

The first happened to a stout healthy young man, who, by a fall from a vicious horse, dislocated his ancle. The accident happened a few miles from Nottingham. He was immediately brought to his master's house, where I saw him, and found the end of the tibia protruding through a large lacerated and contused wound, on the fore part of the ancle. The fibula was broken about four inches above the joint, and its lower end was separated from its connection with the tibia, by a laceration of the ligament connecting it with that bone, but it did not protrude. Appearances in many respects were unfavourable, as there was much ligamentary and some tendinous laceration; but as the tibia was sound, and the fibula only transversely fractured, I was encouraged by the resources of a good constitution, and more particularly by the sanction of my friend, Mr. Wright, a practitioner of much experience, to attempt the preservation of the joint. The bones were reduced with little difficulty, and the limb was placed in a flexed position on its side on a broad hollow splint; the supervening symptoms were more favourable than could have been expected from the nature of the accident, though some portion of the integuments sloughed away, and two different suppurations took place in the joint, followed by two small exfoliations. The patient in three months recovered the use of the joint, and at this time experiences no inconvenience from the accident.

Two cases of external dislocation occurred in boys, both of whom were healthy, and the accidents were occasioned by falls from horses; the malleoli interni were in both instances broken off, and the tibia and fibula protruded two or three inches through the integuments. In one case, the projecting end of the fibula

was left, adhering by its ligament to the anterior part of the astragalus; in the other it was whole. I removed the loose portion of the fibula, the bones easily united, and the limbs were placed in an extended position, supported by long splints. In both cases the inflammation was high. In one, a large abscess formed about the middle of the leg, and a discharge of matter from the joint continued for some weeks, attended with a separation of sloughing ligamentous and membranous parts. The wound gradually healed, the discharge abated, and the boy recovered, with very little impediment to the free motion of the joint. The other boy would have been equally fortunate, but exfoliations took place on the end of the tibia, which, though small, retarded his recovery for several weeks, and left the joint less perfect in its motion than in the preceding case, but quite sufficient for the common occupations of life. You have here a plain statement of facts, without comment or embellishment. My mode of treatment has been uniformly to keep the limb *in the most quiescent state*, and to meet symptoms as they arise; and I cannot but attribute the success which attended the treatment of these cases in a great measure to that precaution.

Exfoliation of the tibia.

I am, dear Sir,

With great respect, your's

B. Maddocks.

DISLOCATION OF THE TIBIA AND FIBULA OUTWARDS.

CASE XVI.

Sir,

Not having the honour of being personally known to you, I trust that the wish you have expressed in your work on dislocations to be informed of the treatment and result of accidents of that nature, will plead my excuse for troubling you with the following case of compound dislocation of the ancle.

On the 22nd of October last, I was called upon to attend Thomas Saxty, a lad about thirteen years of age, whose left foot had got entangled in a strap of the machinery used in the clothing business. On examination, I found a very bad compound dislocation of the tibia and fibula outwards; the bones were protruding four or five inches through the integuments, which were dreadfully lacerated; the wound extended from the external malleolus in an oblique direction to the posterior part of the tibia, and within five inches of the head of that bone, which articulates with the femur. On putting my fingers into the cavity of the ancle-joint, I found the astragalus very loose, being torn from its connecting ligaments.

On the first view of so serious an accident, I thought it would be impossible, with safety to my patient, to save the limb; but as he had received so severe a shock, the countenance being pale, and the extremities cold, I determined to defer the amputation until the constitution should be recovered from the first

impression of the accident, and proceeded in reducing the limb to its proper situation, which I accomplished with but little difficulty; I applied lint to the wound, and covered the limb with a many-tailed bandage lightly bound on; still I had no idea but that amputation must take place, and the next morning I requested Mr. Carey, a very intelligent surgeon of this town, to assist me in the operation; owing to professional engagements, he could not accompany me to the boy before six in the evening, when, on examining the limb, there was considerable inflammation in the leg above the lacerated parts, and great tenderness in the thigh, which I then learnt had received some injury at the time of the accident. Under these circumstances, it was determined to delay the operation for the present. The limb was wrapped in a warm poultice of oatmeal and yeast, the boy placed on his left side with the limb in the bent position, and a draught with twenty drops of laudanum ordered to be taken immediately; he passed a restless night; on the following morning, October 24th, the inflammation of the leg above the injury was considerably increased, with very great tenderness on pressure; and the wound had a dry, dark, sphacelated appearance. I ordered my patient some wine and an opiate at bed-time; he passed a more comfortable night, and the next morning the appearance of the wound had improved; in the course of the 26th, a distinct line, marking the extent of mortification, could be traced.

It would be useless to record the daily progress of the case, as the detail would take up too much of your valuable time; suffice it to say, that in the course of three weeks the whole of the sphacelated parts had separated, leaving a most extensive wound.

The poultices were now laid aside, and simple dressings substituted; a many-tailed bandage was applied to give support to the limb, and a splint attached on each side the leg. The discharge about this time, a month after the accident, was very considerable; but the boy having a good constitution, I began to think there might be some chance of saving the limb, and I determined not to amputate unless the symptoms should imperiously demand that operation. About four inches of the inferior extremity of the fibula were exposed to view, and would evidently exfoliate.

On November the 26th, I placed the boy on his back, the limb resting on the heel: I was induced to make this alteration in his position because my patient had experienced considerable pain every time the limb was dressed, as it was obliged to be moved daily for that purpose.

The wound at this time did not go on so well as could be wished; it had an unhealthy appearance, with large, flabby, and shining granulations. I tried the effects of stimulants, such as a weak solution of nitrate of silver, a solution of vitriolated zinc, &c., but still without decided benefit.

On November the 30th, nearly six weeks from the time of the accident, that part of the fibula which forms the external malleolus exfoliated; and three days afterwards I succeeded in bringing away a broad portion of the articulating surface of the tibia. In a few days the discharge lessened, but there seemed no disposition in the wound to heal.

I had repeatedly witnessed the good effects of the adhesive plaster in ulcers of the leg, in the manner recommended by the

late Mr. Baynton; and, as in the present case, a stimulant was required, as well as support to the edges of the wound, I considered that this dressing, applied in the form of a many-tailed bandage from the ancle to within four inches of the knee (the extent of the wound), would in all probability amend its condition and appearances. I was not disappointed, for in the course of a few days after the application of the plaster the wound began to heal; and from that time to the present the rapidity of the cure has been beyond my most sanguine expectations.

The boy is now, fifteen weeks from the time when he received the injury, able to walk, with the assistance of crutches, to the factory, a distance of half a mile from his house. To-day I observed that he could put the foot flat on the ground, and walk across the room without the assistance of a stick.

For the last two months I have daily given passive motion to the ancle-joint, but I fear, from the great extent of injury, that he will never recover the perfect use of it, though it is not so completely anchylosed as to prevent all motion.

It appears wonderful that in such a very extensive laceration, no artery requiring a ligature should have been wounded.

I do not claim to myself the merit of having saved the boy's limb, as you will perceive by the preceding statement, that he is more indebted to a fortuitous circumstance. At the time when my friend, Mr. Carey, saw it, there was too much inflammation above the seat of the injury to warrant us in amputating.

I have sent you the portions of bone that have exfoliated, as I thought they would give you a clearer idea of the extent of the injury to the joint than could be afforded in writing.

I recollect about nine years ago, when I was with my father at Wantage, the occurrence of compound dislocation of the ancle inwards, in a woman about fifty years of age and of spare habit; it was attended with but little laceration, was easily reduced, and eventually the patient recovered, but with a complete anchylosis of the joint.

Should any circumstance occur during the further progress of the cure, which I should think worth communicating to you, I will take the liberty of again addressing you; or should I have omitted any thing in the preceding statement which you consider of consequence, I shall be very happy in giving you any further information in my power.

I remain,

Your obedient, humble Servant,

J. Ormond.

Trowbridge, Feb. 6th, 1822.

REMOVING THE ENDS OF THE BONES.

Sawing off the ends of the bones.

There is another mode of treatment in these accidents, which consists in sawing off the extremity of the tibia before the bone is returned into its natural situation; and the reasons which may be assigned for pursuing this practice are as follow:

Reasons.

Difficult reduction.

First. That there is in some cases much difficulty in the reduction of the tibia, and great violence must be employed to effect it.

Secondly. The extremity of the bone is often broken obliquely, so that when reduced it will not remain upon the astragalus, but when the point is removed by the saw, it rests without difficulty upon that bone. Oblique fracture.

Thirdly. The spasmodic contractions of the muscles are much diminished by shortening the bone, as it throws them all into a state of relaxation; whereas, if the bone be reduced by violence when the saw has not been used, the spasm of the limb will be sometimes very violent. Spasms.

Fourthly. The local irritation is much diminished by the greater ease with which adhesion is produced of the sawn extremity of the bone to the parts to which it is applied; for it is a mistake to suppose that the sawn end of the bone will not adhere; the contrary is seen in amputation in sawing off a bone in exostosis, and in the union by adhesion of compound fractures; and that adhesive matter can be thrown out upon cartilaginous surfaces is known to every person who has dissected a diseased joint; and it is thus that the end of the tibia adheres to the surface of the astragalus. Local irritation diminished.

Fifthly. When suppuration does occur it is much diminished, and a considerable part of the ulcerative process is prevented by the mechanical removal of the cartilage; for nearly half the articular surface of the joint no longer remains. Cæteris paribus, therefore the case recovers more rapidly. Suppuration and ulceration lessened.

Sixthly. The constitutional irritation is very much lessened by the diminution of the suppurative and ulcerative process, and by the ease with which the parts are restored. In the cases which I Less constitutional irritation.

have had an opportunity of seeing there was not more irritative fever than in the mildest cases of compound fracture.

Bone shattered.

Seventhly. It has been found that in cases in which the extremities of the bones forming the joint have been broken into small pieces, and in which these have been removed by the finger, the patient has suffered less, and has more quickly recovered, than when the bone has been returned whole.

No case of death.

Eighthly. I have known no case of death when the extremities of the bones have been sawn off, although I shall have occasion to mention some in which the cases terminated fatally when this was not done.

Objections.

Limb shorter

The objections which may be made to this mode of treatment are, that the limb becomes somewhat shorter by the removal of the cartilaginous extremity of the bone; but this I do not think an objection of any considerable weight, if the danger of the case be, as I believe, lessened by it; for the diminished length, which is very slight, is easily supplied by a shoe made a little thicker than usual.

Anchylosis.

The other objection is, that the joint becomes necessarily anchylosed. I doubt very much the reality of this objection, as in two instances I have seen the motion of the part remain; but even when the joint becomes anchylosed, a consequence to which it is liable in either mode of treatment, still the motion of the tarsal bones becomes so much increased as to compensate for that of the ancle, and the patient walks with much less halting than would be imagined, and has a very useful limb.

Each mode useful.

It is not my intention, however, to advocate either mode of

treatment to the exclusion of the other, but to state the reasons which may be justly assigned for the occasional adoption of either. It is only by a comparison of the different results of varied practice that a safe conclusion can be drawn; and from what I have had an opportunity of observing in my own practice, and of learning from that of my friends, I feel disposed to recommend to those whose minds are not settled upon the subject, not hastily to determine against either treatment in the different cases of this injury, as, from each mode, under varied circumstances, a strong and useful limb has been saved without any additional risk to the life of the patient.

Cases in which the one or the other should be employed

If the dislocation can be easily reduced without sawing off the end of the bone; if the bone be not so obliquely broken, but remain firmly placed upon the astragalus when reduced; if the end of the bone be not shattered, for then the small loose pieces of bone should be removed, and the surface of the bone be smoothed by the saw; if the patient be not excessively irritable, so as to occasion the muscles to be thrown into violent spasmodic actions in the attempt at reduction, which leads to subsequent displacement when the limb has been reduced; the bones should be at once returned into their places, and the parts should be united by the adhesive inflammation; but rather than amputate the limb, if the above circumstances were present, I should certainly saw off the ends of the bones.

Cases.

I shall now proceed to state the cases which I have myself had an opportunity of witnessing, and some which have been furnished by my friends, and shall leave the reader to judge of the propriety of the advice I have given.

COMPOUND DISLOCATION OF THE TIBIA OUTWARDS AT THE ANCLE-JOINT.

CASE I.

I was sent for to Guy's Hospital, to see Nathaniel Taylor, aged thirteen years, and was directed to bring my amputating instruments with me, being informed that the boy had so bad a dislocation of the ancle that the limb could not be saved.

As soon as I arrived at the hospital, I ordered the patient into the operating theatre; and making enquiries into the cause and nature of the accident, I found it to be as follows: The injury had been occasioned by a boat falling upon the leg. A large wound appeared at the outer ancle, through which the tibia and a fractured extremity of the fibula projected; one inch of the malleolus externus remained attached to the astragalus by its natural ligaments; the foot was turned inwards so as to be capable of being brought in contact with the inner side of the leg; and as the muscles were no longer on the stretch the foot was very loose and pendulous. I tried to reduce the limb, but found that the bone could only by great violence be brought on the astragalus, and that it immediately slipped from its place. The case was, therefore, as regarded the state of the parts, the most unfavourable possible, and those around me urged an immediate amputation; but seeing the character of health which the boy bore, I thought I should not be justified in probably dooming him to a life of mendicity, and I determined to try to preserve the limb. Finding that the lower end of the fibula,

although still connected by ligament, was very loose and moveable, I removed it with the scalpel; I then sawed off half an inch of the lower extremity of the tibia. When these operations had been accomplished with the greatest care, I reduced the bones, and they maintained their situation, as there was no force of muscular action upon them, on account of the shortening of the bones. Lint, dipped in the patient's blood, was then applied, with adhesive plaster over it; and the leg was put in splints, and placed on the heel. Scarcely any constitutional irritation occurred; the wound and ancle-joint secreted but little matter, and gradually healed. On the 17th day, an abscess shewed itself on the tibia, which was suffered to burst, as it had little affected his constitution. In two months he was allowed to sit up and use his crutches. In twelve weeks the wound was healed, and the boy was able to bear on his foot; and at the end of four months, he walked well. I experienced inconceivable pleasure in seeing this boy walk before the students, at my desire, from one end of the ward to the other, four months after the accident, with very little lameness. There seemed to be some motion at the ancle, but the tarsal bones soon acquired sufficient mobility to give to the foot so much play as to prevent the appearance of stiffness, which a partially anchylosed state of the ancle would otherwise have produced.

Removal of the end of the fibula.

Motion of the tarsal articulation.

COMPOUND DISLOCATION OF THE TIBIA INWARDS.

CASE II.

—— West, Esq., aged forty, on December 11th, 1818, jumped out of his one-horse chaise, alarmed by the horse kicking. He fell, and when he attempted to rise, found his left ancle dislocated, and the bone projecting through the skin. Mr. Mackinder, surgeon, brought him to the house of his father-in-law, in London, where Mr. Jones, of Mount Street, and myself attended him.

Integuments pressed between the bones.

Upon examination of the part, I found the tibia projecting at the inner ancle through the integuments, which were nipped under the projecting bone into the joint; the foot was loose and pendulous, and very much thrown outwards. Having prepared several pieces of linen to form a many-tailed bandage, and procured pillows and splints, the patient was placed on a bed on his left side, and an attempt was made to reduce the bone; but hearing from Mr. Jones, that Mr. W. was of a most irritable constitution, and finding that most powerful extension must be made, and that the integuments must be divided opposite to the joint, so as to lessen the probability of an easy adhesion to the wound, which was placed one inch and a half above the articulation, I sawed off the end of the tibia, and the bone most easily returned into its natural situation, in which it remained without difficulty. The edges of the wound were brought together by a fine thread, so as to be very closely adapted to each other, and lint dipped in blood was applied over the wound; the many-tailed bandage was used; the limb was placed on its outer side,

with the knee bent nearly at right angles with the thigh, and splints were applied. The leg was ordered to be kept constantly wet with the liq. plumbi, s. acetat, dilutus, ʒv. and spir. vini. ʒi.; a dose of opium was given to him, and ten ounces of blood were taken from his arm. In the evening, more opium was administered, and a dose of infusion of senna and sulphate of magnesia was ordered for the morning.

Dec. 12. As the limb felt hot, the upper splint was removed, its pressure being somewhat painful, and preventing free evaporation. Opium was ordered at night.

Dec. 13. The foot was vesicated. He had chillness succeeded by heat; slight tension of the leg, and some pain for three hours. His mind was much agitated by seeing his children.

Dec. 14. The limb was less inflamed, and he had scarcely any constitutional irritation.

Dec. 15. A slight discharge of serum mixed with red particles from the wound; some pain in the foot and leg, but no irritative fever.

Dec. 16. There was more discharge, and some air passed from the wound; a poultice was applied, and a generous diet allowed, as his stomach, naturally weak, had become very flatulent. Pulse 90.

Dec. 17. A fomentation and poultice applied.

Dec. 18. The discharge was becoming purulent; but as his stomach was deranged, he was visited by Dr. Pemberton, who ordered him hyoscyamus with the mixtura camphor. in the day, and opium at night. Derangement of the stomach.

From this time to the 7th of January, the discharge from the

limb was copious, but it then began to lessen; and when the leg was examined on the 12th of January, it had become firm; a small wound remained, on which the granulations were prominent. In the first week in Februrary, he was allowed to get upon his sofa, the limb being now firm, and only a small wound remaining, from which an exfoliation will occur, as the bone can be felt bare.

In August I saw him; the wound still remained open, and the portion of bone had not separated.

This gentleman, with the worst constitution in regard to the state of his stomach, did not suffer so much irritation, as a compound fracture usually produces.

COMPOUND DISLOCATION OF THE TIBIA INWARDS.

Mr. Charles Averill, dresser to Mr. Forster, Surgeon of Guy's Hospital, had the kindness to send me the following particulars of a case, the progress of which I often witnessed with pleasure.

CASE III.

John Williams, sailor, aged thirty-eight, a very robust man, was brought into Guy's Hospital, under the care of Mr. Forster, August 9th, 1819, at four o'clock in the morning, with a compound dislocation of the right ancle inwards, and considerable injury to the left, occasioned by his falling from a height of about twenty-six feet, in endeavouring to escape from the Borough Compter, in which he was imprisoned. On examining the injured

part, I found the tibia protruding three inches through a large transverse wound of four inches in extent, and resting on the inner side of the os calcis; the cartilaginous surface of the astragalus could be readily felt on passing my finger into the wound; the fibula was broken. I first sawed off the whole of the cartilaginous end of the tibia, when the bone was easily replaced; the edges of the wound were then brought as much in contact as possible; lint dipped in blood was applied, and over it straps of adhesive plaster; the foot and leg were wrapped in cloths wet with a lotion of acetate of lead, and the limb was laid on its side. He complained of great pain in the left leg, which was very much swollen all around the ancle; ten leeches were applied to it, and afterwards the liquor plumbi subacetatis dilutus, which relieved the pain; thirty drops of laudanum were given, and he remained easy. On the following day, sixteen ounces of blood were taken from him, and five grains of calomel were given. On the 12th, the dressings were removed; the wound looked well. On the 17th, suppuration had commenced, and the discharge having rather a fœtid smell, the nitric acid lotion was applied.* September 2nd, the matter gravitating to the outer side of the leg, an opening was made, by which it was discharged, and adhesive plaster applied to the original wound, which was healing fast; the discharge gradually diminished, and on the 21st of September, six weeks from the accident, both wounds were quite healed. He has

Use of nitric acid in sloughing wounds.

* The nitric acid lotion, during the sloughing process, is the best application with which I am acquainted. I order it in the proportion of fifty drops of the acid to a quart of distilled water, and apply it by linen covered with oiled silk.

not yet left his bed. There is motion at the ancle; the toe turns out but very little, and does not point downwards. He wears splints, and the strength of the limb is daily increasing. When the swelling of the left ancle diminished, a fracture of the external malleolus was also there discovered.

CHARLES AVERILL.

October 4th, 1819.

This man escaped from the hospital on the 24th of October, and two months afterwards was retaken, and is now in the Borough Compter. He has free motion of the right ancle, and suffers more from the injury to the left.

For the following letter I am indebted to Dr. Kerr, of Northampton, who, at the age of more than eighty, still continues to practice his profession with all the ardour of youth, and with a strength of intellect which has been seldom surpassed.

Northampton, July 28th, 1819.

MY DEAR SIR,

I have had the honour of your letter this morning respecting compound dislocation of the ancle; several such cases have fallen under my care, and it has been uniformly my practice to take off the lower extremity of the tibia, and to lay the limb in a state of semiflection upon splints; by this means a great deal of painful extension, and the consequent high degree of inflammation, are avoided. The splints I use are excavated wood, and much wider than those in common use, with thick moveable pads stuffed with

wool. I keep the parts constantly wetted with a solution of liquor ammoniæ acetatis, without removing the bandage. In my very early life, upwards of sixty years ago, I saw many attempts to reduce compound dislocation without removing any part of the tibia; but, to the best of my recollection, they all ended unfavourable, or, at least, in amputation. By the method which I have pursued, as above mentioned, I have generally succeeded in saving the foot, and in preserving a tolerable articulation.

I am, with much esteem, my dear Sir,

Your obedient, humble Servant,

WILLIAM KERR.

COMPOUND DISLOCATION OF THE TIBIA OUTWARDS.

To Dr. Rumsey, of Amersham, I am obliged for the following interesting communication.

CASE IV.

DEAR SIR, *Amersham.*

I have the pleasure of forwarding to you the case of a compound dislocation of the ancle, which came under my care many years ago, and which had a fortunate termination, as the patient lived many years after the accident.

On June the 21st, 1792, Mr. Tolson, aged forty years, was thrown from a curricle on Gerrard's-cross Common, eight miles from this place. The injury he received consisted in a compound

dislocation of the tibia and fibula at the outer ancle of the left leg, with a fracture of the astragalus (the superior half of which was attached to the dislocated bones of the leg), and likewise a simple fracture of the os femoris on the same side. He was conveyed to a friend's house on the common, where he had the advantage of an airy, healthy situation, with every kind of domestic attention. I saw him about two hours after the accident, and found the bones protruding at the ancle through a very large wound, with the foot turned inwards and upwards, and the integuments beneath the wound exceedingly confined by the dislocated bones which descended nearly to the bottom of the foot. A considerable hæmorrhage had taken place, but was stopped by the spontaneous contraction of the lacerated vessels.

Complicated with fracture of the femur.

From such a formidable accident, in so large a joint, there appeared very little probability of the patient's recovery without immediate amputation; I therefore requested that a consultation with some other surgeons might be expeditiously held on the case, and expresses for this purpose were accordingly sent to Mr. Pearson, surgeon in London, and to my brother, Mr. Henry Rumsey, surgeon at Chesham, in this county. While I was waiting for their arrival, the patient requested me to examine his thigh, when I plainly discovered an oblique fracture of the os femoris at its superior part. This additional evil appeared to me a great obstacle to an amputation. My brother, when he arrived, being of a similar opinion, I attempted to reduce the fractured dislocated joint into its proper situation. This I found very difficult without first separating that part of the astragalus which was pendulous to the tibia, having its capsular ligament lacerated

Amputation rejected.

half way around the joint. This portion of the astragalus consists of the broad smooth head by which it is articulated to the tibia; of almost the whole of the inner and outer sides of this head, by which it moves on the inner and outer malleoli; and of about the upper half of the posterior cavity on its under surface, by which it is united to the os calcis; so that the bone was divided nearly horizontally, and the part left behind consisted of the lower half of the last mentioned cavity, of the whole of the other or anterior cavity which connects it with the os calcis, and of the anterior portion or process by which it is articulated to the os naviculare: I therefore removed it without hesitation, being persuaded that if it had been practicable to reduce it into its original situation, so large and moveable a portion of bone would have been a source of pain and irritation, and have rendered the cure more difficult and uncertain. I then divided that portion of the integuments of the foot which was confined by the protruded end of the tibia, which enabled me with ease to reduce it and the fibula into their proper situation. I applied some dossils of lint dipped in tincture of opium to the wound, and covered the whole with a poultice of stale beer and oatmeal. We now reduced the fractured femur, and placed the limb in a bent position, expecting that our greatest success would be in procuring a complete anchylosis, the failure of which I concluded would leave an useless foot. The under splint was a firm excavated piece of deal, of the shape of the leg and foot, with a hole opposite the ancle. Mr. Pearson arrived in the evening, and approved of the preceding treatment, giving it as his opinion, that it would be safer to attempt the preservation of the limb than to amputate,

Removal of part of the astragalus.

under such complicated circumstances. The wound was concealed as much as possible from the external air, and the cataplasm renewed no oftener than the discharge rendered necessary.

Vomiting and delirium

June 22nd. The preceding night had been very painful, with delirium and vomiting; the pulse was full and frequent; I took away ten ounces of blood, and gave potassæ tartras and manna in doses sufficient to procure stools. A common saline draught, with antimonial wine and tincture of opium, was given every four hours, and a fuller dose of tincture of opium at bed-time.

23rd. The vomiting continued; the ancle and thigh had been less painful through the night; the saline draughts were continued, but without the antimony, on account of the vomiting; during this period, the antiphlogistic regimen was strictly adhered to.

24th. The night had been tolerable; the vomiting had ceased; the pulse was softer; the saline draughts were continued, with the opiate at bed-time; this evening the leg was very painful; he passed a pretty good night; a discharge from the wound now commenced, and the tension of the muscles of the thigh began to diminish.

26th and 27th. The same treatment was continued. The discharge increased, and the tension of the thigh still more abated.

28th. The ancle was much swelled and inflamed; I therefore exchanged the beer-grounds in the cataplasm for the liquor plumbi subacetatis dilutus. The patient had this day much pain in the bowels from flatulence; from which circumstance, and that of the discharge being very thin, it was judged expedient to vary his mode of living, and likewise his medicines.

29th. He was allowed a small portion of animal food, some table-beer, and some port wine; and he took the bark liberally, both in substance and in decoction. This change of treatment agreed with him perfectly well. At this time I found it necessary to alter the position of the limb, on account of the pressure on the wound, occasioned by its lying in the bent position, and by the pain caused in turning to dress it, which, from the copious discharge, there was now a necessity for doing night and morning. I therefore placed it on the heel, using the common deal flexible splint, of the length of the limb, and confined it in a box, whose sides and lower end let down; the space between the sides of the box and splint was filled with pieces of flannel. By these means, and the use of the eighteen-tailed bandage, the dressings were applied with very little disturbance to the leg, and thus the patient escaped much pain. The upper end of the box under the ham being raised, gave the muscles some degree of flexion, and, at the same time, was favourable to the discharge. The foot having a tendency to fall inward, and the end of the fibula to protrude through the wound, it required great attention to prevent the deformity which the neglect of these circumstances might have occasioned. The mode of prevention which I adopted, and which proved successful, consisted in employing a number of small deal wedges, about six inches long, two broad, and a quarter of an inch thick; as many of these as were found sufficient were placed opposite the inside of the foot, between it and the side of the box; others, in the same manner, were placed on the outer side of the calf of the leg; by which means the limb was kept steady; and

Change of diet and treatment.

by keeping the heel in an easy, and rather hollow position, none of the usual evils arising from pressure on the heel occurred.

30th. The bark agreed very well; the opiate was continued at bed-time; the discharge was great but more purulent; the pulse was become softer and less frequent; and the urine, which had hitherto been clear and very high coloured, was now turbid; the pain and inflammation being much diminished, the cataplasm was discontinued; the wound was dressed with dry lint, with a pledget of cerat. plumbi superacetatis over it, and a moderate compression was made by means of a bandage. From this period, the wound progressively mended; the discharge diminished; granulations formed; and the surrounding skin began to heal. The use of the bark and of the opiate was continued till the beginning of August. About the end of July, the progress of the cure was retarded by matter collected under the integuments, above the inner ancle, which on pressure came out at the wound. After in vain trying the effects of permanent pressure for the prevention of this deposit, I made an incision into the cavity and filled it with dry lint, to produce inflammation on its internal surface, which consolidated it, and the wound became perfectly cicatrised by the middle of September, without any exfoliation of bone larger than the head of a pin having taken place. The fracture of the femur went on very well, excepting that its obliquity, with the impossibility of producing a permanent extension on account of the leg, occasioned a degree of curvature which it otherwise would not have had. The limb gradually acquired strength, and the patient is able to walk very well with only the aid of a small stick, and even this

Collection of matter.

assistance he will probably not require long. There is no anchylosis to render the ancle immoveable; but a sufficient firmness has been produced in the surrounding parts by the long continued inflammation to assist in the formation of an artificial joint, which possesses a degree of motion nearly equal to that of the natural.

COMPOUND DISLOCATION OF THE TIBIA INWARDS.

For the following most interesting case I am indebted to Mr. Hicks, of Baldock.

CASE V.

Baldock, August 10, 1819.

My dear Sir,

In the absence of my son, I beg leave to forward you the following account of a case of compound dislocation of the ancle.

Case of John Curgan. Early in the morning of November 10, 1812, the Stamford coach, from the carelessness of the guard in neglecting to chain the wheel, ran with great velocity down the hill a mile below Baldock, and fell on its side a little before it reached the foot of the hill; in its fall, the side of the coach caught the coachman's right leg, and turned the foot upon the outside of the leg, by which the tibia became dislocated on the inner side; the tibia and fibula protruded through the integuments about four inches; the oblong end of the fibula was fractured, and several small portions of it remained within the

integuments; the end of the tibia had some small portions chipped off, it appearing as if it had been ground by the side of the coach; in this state he was brought to Baldock, with his foot dangling to his leg; the wound was very large, so much so, that the foot appeared almost separated from the leg; the ends of the bone were covered with dirt.

As there was not the least chance of success in returning the tibia and fibula within the integuments, in this state, and as the patient was anxious for the preservation of his leg, which I likewise was very desirous to save, I judged it prudent to saw off the ends of the tibia and fibula, the foot at the same time lying on a pillow below the leg; after removing the ends of the tibia and fibula, I searched for the fractured portions of the fibula left within the integuments, by introducing the fore finger of my right hand into the wound, and found its external malleolus fractured into several small pieces, but still adhering by its ligaments to the astragalus. Being fearful that these shivered portions might be deprived of the properties of life, and, that if so, they might produce much mischief, I resolved to dissect them out, by means of a bistoury, through the wound. Having thus removed every fragment of the fibula, and rendered the ends of the tibia and fibula perfectly smooth by means of a saw, not only removing their fractured ends, but making the separation as high up as they were stripped of their periosteum, about one inch and a half in length, measuring from the malleolus internus, I then returned the remaining part of the tibia and fibula that had perforated the integuments, placing it in a straight line with the leg; the lacerated integuments I brought into contact, and

Removal of the fragments of the fibula.

secured them by straps of adhesive plaster; the limb was then placed upon a soft pillow, supported by Mr. Pott's long splints placed on the outside of the pillow, and fastened with tapes; compresses of soft linen cloth were applied, and the leg was kept constantly wet with the diluted solution of the acetate of lead, and the following draught was given for the first few days, every four hours, and afterwards every six or eight, with a regimen strictly antiphlogistic.

R. Pulv. Ipecacuanhæ. c. gr. vj.
Magnes. Sulphat. ʒj.
Aquæ Puræ. ʒix.
—— Menthæ. ʒiij.
Spt. Ætheris Nitros. ʒss. M. Ft. Haust.

Through the whole of the cure the man went on remarkably well, and had little symptomatic fever; pulse constantly below the natural standard, between 60 and 70; skin soft and moist; the action of the intestines was regularly kept up by the draughts; the integuments united by the first intention, without the least secretion of pus. On the day seven weeks from the accident, the patient was removed from Baldock to his residence at Hewlington, and did not require chirurgical aid afterwards. In a few months afterwards he paid me a visit at Baldock, walked perfectly well, and the leg was very little shorter than the other. The last time I saw him was by chance in April 1815, at the Bell New Inn, about three miles below Baldock, where his coach stopped, and he descended and ascended his box with great agility.

I am, my dear Sir,
Your's most respectfully,
George Hicks.

COMPOUND DISLOCATION OF THE TIBIA OUTWARDS.

My friend and late dresser, Mr. Cooper, of Brentford, an ingenious surgeon and an excellent man, sent me the following valuable communication.

CASE VI.

Thomas Smith, aged thirty-six, by trade a painter, whilst at work on the 28th of October, 1818, fell with a ladder to the ground, when his leg getting between two of its steps, the foot was dislocated inwards. The fibula was broken five inches above the joint, the tibia was fractured from the ancle-joint longitudinally about three inches; this small piece of tibia, three inches in length, remained attached to the joint at the inner malleolus, while an inch and a half of the remaining portion of the tibia, with the extremity of the fibula, were thrust through an opening in the integument, at, and rather anterior to, the outer malleolus. I was passing at the time, and attempted by very moderate extension to reduce the dislocation; this not succeeding, and finding the integuments tucked under the protruding portion of bone, with a scalpel I dilated the wound anteriorly and posteriorly about half an inch, and then, by means of a metacarpal saw, removed rather more than an inch of the tibia, and a small portion of the fibula. This dislocation was now reduced without any difficulty. The wound was closed by two ligatures and a few straps of adhesive plaster.

Longitudinal fracture of the tibia.

The patient was placed on a mattress with the limb on the heel, enveloped in an eighteen-tailed bandage, which was applied just sufficiently tight to give moderate support, without producing or increasing tension; on either side was placed a splint, and the limb was kept constantly cool by means of an evaporating lotion.

Subsequent to the operation, and during the whole of the night, there was some hæmorrhagy from the articular arteries, but not sufficient to induce me to undo the limb in order to secure the bleeding vessels, and I did not open it till the 31st of October, the fourth day, when considerable adhesion had taken place, and the parts looked better than I could have expected; but on the eighth day there was a line of separation formed about five or six inches in circumference; the wound was now fomented, a linseed meal poultice was applied to it every six hours, and the evaporating lotion was still applied to the limb as far upwards as the knee. On the thirteenth or fourteenth day the slough came away, and healthy granulations were observable, both upon the integuments, and also upon the extremity of the tibia; when these granulations became exuberant, they were kept down by the nitrate of silver, and the wound was slightly dressed either with ungt. cetacei, or equal parts of ungt. resinæ and cerat. calaminæ. In five weeks, the wound was perfectly healed; the union of the fractured portions of the tibia went on so well, and the ossific deposite at the joint became so firm, that on Christmas day, being fifty-eight days from the time of the accident, I found the man sitting at his table dining with his family, and in three months he was in the street, on crutches.

This patient had repeatedly suffered much from colica pictonum; his digestive organs were unhealthy, and he was a man of nervous temperament, all which particulars I had to discover after the accident. As early as the third day he was very restless, on the fourth, his sensorium was much affected, and he was constantly vomiting; by the frequent administration, however, of the saline mixture in the act of effervescence, his stomach was quieted.

I ought to have observed that, on the night of the accident, he took an opiate, and on the following day I purged him; but from the state of his pulse, and from the degree of hæmorrhagy, I did not find it requisite to take blood from the arm. By the eighth day, his stomach being tranquil, we were enabled to assist the separation of the slough, by invigorating the powers of the system with bark and port wine; from half a pint to a pint of which, with eight ounces of the decoction cinchonæ and opium, the quantity being regulated by his state of irritability, enabled him to support the immense suppuration at the joint, which, from this time to the fourth week, discharged most copiously.

I may here mention, that I never observed, on the one hand, the stimulating effects of opium, and on the other, its sedative effects, so strikingly exemplified as in this man; for if he did not take quite enough to produce sleep, he was literally mad, tearing the bed-clothes, swearing, praying, singing, and making the oddest grimaces possible; but if he had a full dose, which, by the third week, had been increased to two drachms of laudanum, he slept soundly and awoke refreshed; and I believe from his extremely susceptible state, that, but for opium, which produced a directly sedative effect upon his nervous system, he would have sunk from

constitutional irritation. At the end of the second week, his stomach being in a fitter state for digestion, he was allowed a plentiful supply of animal food and good beer, with which, and wine, bark, and opium, continued for a week or two, he perfectly recovered.

I am, Sir, &c. &c.

GEORGE COOPER.

I saw this man on March the 1st, 1820, and I said, "Would you rather have your present or an artificial leg?"—"Sir," said he, "my injured leg is nearly as useful to me as the other; I can go up a ladder, and follow my business as a painter, nearly as well as ever." A. C.

COMPOUND DISLOCATION OF THE TIBIA INWARDS.

CASE VII.

Worcester, July 30, 1819.

DEAR SIR,

I have had no case of compound dislocation of the ancle-joint under my care since I have settled in practice; but my colleague, Mr. Sandford, gives me the following information, which I do myself the pleasure of transcribing.

A boy, fifteen years of age, was admitted into the Worcester Infirmary with compound dislocation of the ancle; the protruding portion of the tibia was sawn off, the anterior tibial artery was taken up, the limb was placed on its outer side, the wound dressed superficially, and the dressings retained with a many-tailed

bandage, kept wet with the liq. ammon. acet. Suppuration and granulation came on kindly. The boy wore tin splints for a length of time, and on his recovery had a slight motion of the ancle-joint.

I am, my dear Sir,

Your's very respectfully,

J. Carden.

COMPOUND DISLOCATION OF THE TIBIA OUTWARDS.

CASE VIII.

My dear Sir, *Gloucester, Sept.* 1, 1819.

Some domestic events have delayed my reply to your letter. I remember six cases of compound dislocation of the ancle-joint, four of which underwent immediate amputation. In the two other cases attempts were made to save the limbs, and in one with success. Most of these accidents were produced by machinery; and the injury to the joints and soft parts was so great as to destroy all hopes of saving the limb.

In the limb that was not saved, though the attempt was made, there had been too much mischief done, and, after a trial of seven months, amputation was performed.

I was called to a fine young woman, eighteen years of age, who had been consulting me not an hour before on the case of her father, and who having fallen from her horse, had suffered a compound luxation of the ancle-joint *externally*. The tibia and broken fibula protruded about an inch and a half through the wound on

the outside of the limb. I sent her to the hospital, and in consultation proposed that a sufficient quantity of the bones should be removed to admit of restoration, I advised this attempt to save the limb, from observing that the accident took place by a heavy fall with the sole of the foot to the ground, that it was unaccompanied by contusions or violence committed by a blow or wrench, and that the patient was a very healthy country girl. There had been considerable hæmorrhage.

The extremities of the bones were removed, the reduction accomplished, and the limb supported by a tailed bandage; splints were applied moderately tight, and the bandages were directed to be kept constantly soaked in a cold application. An opiate was given.

On the following day there had been considerable hæmorrhage, but the limb was not disturbed. Great suppuration took place about the joint, spread up the limb, and greatly exhausted the patient, but she recovered. These collections were never opened. I should have opened them early, and thus perhaps have prevented that extent of suppuration which so much reduced the patient.

Any further details I will give you with great pleasure if you require them, and I must hope that on all occasions you will make use of me; and now accept my apology for not answering your letter before.

Very faithfully your's,

R. Fletcher.

The following I received from my friend, Dr. Lynn:

CASE IX.

A man on board the Walmer Castle, East Indiaman, in the year 1808, whilst the ship was off the Cape of Good Hope, fell between decks, and a cask of water rolled upon his ancle, producing a compound dislocation of the end of the tibia inwards. I sawed off the projecting portion of the tibia, brought the parts as closely as possible together, applied evaporating lotions to the limb, and the man recovered without any dangerous symptoms.

JAMES LYNN, M.D.

ADDITIONAL CASES OF COMPOUND DISLOCATION OF THE ANCLE-JOINT.

Leicester, June 29th, 1823.

DEAR SIR,

Inclosed I send you the particulars of the case of compound dislocation of the ancle-joint, as extracted from the hospital books by Mr. Wilkinson, the house surgeon, to whom the dressing of the injury belonged.

Two other cases have occurred to me in private practice, which, although I have taken no particular notes, are valuable in fact, as shewing that the practice is good as adopted in the detailed case which I have sent you. The wounds in the two cases did not heal by the first intention, and the synovial fluid

was discharged for some time, yet they ultimately healed, and did well. One of the cases, as I have since had opportunities of knowing, has completely recovered the free use of the ancle.

Catherine Paddimore, aged seventy-two, was admitted into the hospital on the afternoon of September 4, 1821, from the country, with compound dislocation of the ancle-joint. She was in the act of picking up pears, when her husband fell from the tree, and lighted on her back, which occasioned the accident. On examination, after removing a considerable quantity of blood, the inferior extremity of the tibia of the right leg was protruding nearly three inches through a laceration of the integuments; the foot turned completely outward; the fibula was fractured in two places. The patient being placed in bed on her right side, and the wound being cleaned, the knee was flexed, and, with moderate extension, the dislocated tibia was reduced, and the fibula adjusted. The wound was approximated with adhesive straps; M. Dupuytren's splint and bandage, and an evaporating lotion were applied. The patient was retained on the right side, and the limb flexed: she was very much exhausted. Her bowels were soon acted on by the sulphate of magnesia.

September 5th. No sleep; tongue furred; pulse frequent and strong; bowels well opened; no great pain of the ancle, and trifling swelling. Fiat venesectio é brachio ad ʒxx. vespere. Pain and swelling of the ancle-joint a little increased; pulse frequent and soft. Admoveantur hirudines No. xvi. statim. She takes liq: ant: tart; small doses of the sulphate of magnesia, with a febrile julep, every three hours.

September 6th. Slept several hours; pulse frequent and soft; skin comfortable; bowels not open since yesterday; tongue furred; makes no complaint of the leg, which looks remarkably well. She repeated the sulphate of magnesia.

September 8th. No pain or swelling about the ancle-joint; bowels open.

September 9th. The wound was dressed; the adhesive process far exceeded expectation; no pain.

September 13th. Wound healing.

September 28th. Wound well.

October 4th. Allowed to sit up.

October 13th. Can walk with crutches.

She has now perfect use of the joint, and could walk very well last summer, without crutches.

Your's very truly,

JOHN NEEDHAM.

DISLOCATION OF THE ANCLE OUTWARDS.

William Thomas, aged eighteen, was admitted into Guy's Hospital, June 28th, 1823, with a compound dislocation of the ancle outwards, caused by a hogshead of tobacco falling upon his leg.

The foot was doubled inwards, and the malleolus externus broken, which being immediately removed, the limb was placed upon a splint on its inner side, with the knee bent, two sutures were applied to bring the edges of the wound together, and a

piece of lint placed over it; the leg was kept well wetted with the liq: plumb: acet: dil. The patient was ordered to take forty drops tinct: opii:, and not to be disturbed.

June 29th. Ordered calomel gr. v. and an aperient draught to be taken afterwards.

June 30th. The lint was removed from the wound, and a poultice ordered: no febrile symptoms appearing, this treatment was continued, without medicine, till July 14th.

July 15th. The opiate lotion was ordered instead of the poultice.

July 16th, 17th. The same treatment continued.

July 18th. He passed a restless night, and had a white tongue and quick pulse; with inflammation and swelling of the leg; complained of great pain. Ordered the saline draught every three hours.

July 25th. Matter formed along the tibia; an opening was made, and a large quantity evacuated; a poultice was applied over the opening, and the opiate lotion continued to the wound.

July 28th. It was now judged expedient to change his diet, and his medicines: he was allowed animal food with porter; and bark, with ammonia, was given every six hours.

August 6th. Matter had again formed; another opening was made, and the same treatment pursued; his diet and medicines were continued as before. After this period he rapidly recovered, and at the latter end of the month was able to rise from his bed. The wound always looked healthy.

DISLOCATION OF THE ANCLE FORWARDS.

New Bridge-street, Blackfriars;
March 4th, 1824.

My dear Sir,

I have much pleasure in sending you an account of the case I mentioned to you last night, together with a sketch by which I have endeavoured to shew the position of the limb at the time when I saw the patient.

CASE.

James Price, aged thirty-nine, a very robust young man, was coming to town on Monday, the 1st of March, in a light cart, drawn by one horse. In passing through Clapham the horse ran away, and falling, overturned the cart, and threw Price's legs under one of the shafts; in endeavouring to extricate himself, he received a severe injury to the right ancle. By the direction of Mr. Parratt he was immediately conveyed to St. Thomas's Hospital, where I saw him; and, on examination, found that the tibia had been dislocated forwards, and a little inwards, its inferior extremity resting on the fore part of the astragalus and os naviculare: the deltoid ligament must have been torn through, as the inner malleolus was not fractured. The heel projected very considerably, and the foot was turned outwards in a slight degree and downwards, the toes being pointed. The fibula was fractured about two inches above the external malleolus, at which part there was a considerable depression. The reduction was very easily

accomplished by flexing the leg on the thigh, which was firmly held by my dresser, Mr. Campbell, as I drew the foot downwards and forwards, and pressed the tibia backwards. The limb was placed in the flexed position, on the heel; since which time the patient has been perfectly tranquil, and the limb remains in its proper position.

Believe me, your's most sincerely,

FREDERICK TYRRELL,

Surgeon to St. Thomas's Hospital.

EXPERIMENT.

I was anxious to ascertain what steps nature pursued in order to restore a part in which the extremity of a bone, forming a joint, had been sawed off; and I therefore instituted the following experiment.

I made an incision upon the lower extremity of the tibia, at the inner ancle of a dog, and cutting the inner portion of the ligament of the ancle-joint, I produced a compound dislocation of the bone inwards. I then sawed off the whole cartilaginous extremity of the tibia, returned the bone upon the astragalus, closed the integuments by suture, and bandaged the limb to preserve the bone in this situation. Considerable inflammation and suppuration followed; and in a week the bandage was removed. When the wound had been for several weeks perfectly healed, I dissected the limb. The ligament of the joint was still defective at the part at which it had been cut. From the sawn surface of

the tibia there grew a ligamento-cartilaginous substance, which proceeded to the surface of the cartilage of the astragalus, to which it adhered. The cartilage of the astragalus appeared to be absorbed only in one small part; there was no cavity between the end of the tibia and the cartilaginous surface of the astragalus. A free motion existed between the tibia and astragalus, which was permitted by the length and flexibility of the ligamentous substance above described, so as to give the advantage of a joint where no synovial articulation or cavity was to be found. This experiment not only shews the manner in which the parts are restored, but also the advantage of passive motion: for if the part be frequently moved, the intervening substance becomes entirely ligamentous; but if it be left perfectly at rest for a length of time, ossific action proceeds from the extremity of the tibia into the ligamentous substance, and thus produces an ossific anchylosis.

CASES WHICH RENDER AMPUTATION NECESSARY.

Cases requiring amputation.

But still cases occur in which the operation of amputation will be rendered absolutely necessary, either to preserve the life of the patient, or to prevent his being doomed to the constant necessity of using crutches on account of the deformity and stiffness of the limb.

Does not always succeed.

It seems to me, however, to be by much too prevailing an opinion, that the amputation of the limb is a sure means of preserving life; for when this operation used to be more frequently

performed in our hospitals than it now is, for compound dislocation of the ancle and compound fracture of the leg, a considerable number of our patients died. Very lately a man at Tring had his foot torn off by a threshing machine, and the limb was obliged to be amputated at the usual place below the knee. The operation was performed by Mr. Firth, but the man died in the evening of the sixth day; and a case has occurred since the publication of the second edition of my Essays of equally fatal termination.

The circumstances which I have known to create this necessity are,

(1.) *The advanced Age of the Patient.*

Under great age the powers of the body become so much weakened, that the patient is unable to bear the constitutional excitement which the suppurative inflammation of the joint produces; and as amputation does not expose him to this process, it is better to have recourse to that operation. However, I ought to observe, that when in my lectures I have stated what I have now advanced, the pupils have flocked around me after lecture, and have told me of cases of recovery, even of very old persons; but in the practice of hospitals in this great metropolis, very aged persons sink under these accidents, if the limb be not amputated. Age.

(2.) *A very extensive, lacerated Wound will give rise to a necessity for this Operation.*

CASE I.

July 10th, 1806, Mr. Dudin, a gentleman residing in Horsley- Laceration.

down, Borough, jumped out of his one-horse chaise, and dislocated the tibia inwards at the ancle, through a large lacerated wound, and a portion of the malleolus internus was broken off and remained attached to the astragalus. The wound bled freely, and the foot was loose and pendulous; I therefore felt myself obliged to amputate the limb.

Mr. D., after this operation, proceeded in every respect favourably; recovering without any untoward symptom.

CASE II.

James Morrise, aged thirty-six, was admitted into St. Thomas's Hospital, on the 29th of January, 1824, under the care of Mr. Green, having sustained a dislocation of the ancle-joint, in consequence of having his leg caught in the coil of a rope, to which a great weight was appended.

The injury was accompanied with so much loss of integument, that immediate amputation was proposed, to which the man would not give his consent. Mr. Green sawed off the end of the bone and replaced the tibia upon the astragalus; but the end of the tibia, from deficiency of skin, still remained exposed. The constitutional and local irritation which followed, rendered it necessary to amputate the limb, which was done on March the 19th, being seven weeks and one day after the accident. With Mr. Green's permission I then dissected it, and the following is the result.

Dissection.

The cellular membrane was loaded with serum; all the muscles remained in a sound state, but the tendon of the tibialis anticus

was partially torn, as was that of the peroneus tertius; those of the tibialis posticus, and flexor longus digitorum pedis, adhered strongly to the posterior portion of the capsular ligament. An abscess extended between the tibialis posticus and gastrocnemius muscles from the ancle nearly to the place of amputation. The arteries and nerves were undivided, but the anterior tibial artery was greatly diminished by the altered position and pressure of the tibia. The deltoid ligament, the anterior part of the capsular, and the ligament of the tendon of the tibialis anticus, were torn through. The fibula was broken four inches from the ancle-joint; its lower fractured extremity overlapped the upper about an inch, and the latter was situated between the lower portion of the fibula and the tibia. The bones were not completely united, and the fibula was exfoliating at the upper end of the lower portion; a part of the fibula also remained detached, which had been broken off at the time of the accident. The lower end of the tibia was dead and exfoliating, and rested but partially upon the astragalus: its periosteum was much thickened above the exfoliating part. The outer posterior portion of the tibia next the fibula was broken off, and strongly adhered to the fibula. The surface of the astragalus was in parts deprived of its cartilage by ulceration.

The exposure and consequent exfoliation of the tibia, the exfoliation of the fibula, and the large abscess, led to the necessity for amputation.

(3.) *A difficulty in reducing the Bones has been considered as a reason for Amputation.*

Difficult reduction.

This circumstance, however, is rather a motive for removing the extremities of the bones by the saw than for performing the operation of amputation, after which the reduction of the tibia is easily effected, and an useful limb is preserved to the patient.

(4.) *The bones are sometimes extremely shattered.*

Bones shattered.

If the lower extremity of the tibia be broken into small pieces, the loose portions of bone ought to be removed, and the end of the tibia be smoothed by a saw; but if, in addition to this comminution, the lower extremity of the tibia be obliquely broken, and a large, loose portion of bone be felt with the fingers, then it will be proper to amputate; also, if the astragalus be broken, the portions of this bone should be removed, otherwise they will separate by ulceration, or occasion considerable local irritation. (See Dr. Lynn's and Dr. Rumsey's cases.) But if the end of the tibia and tarsal bones, as the astragalus and os calcis, are broken, then amputation will be required. The following case shews well the necessity of the operation in such a state of parts.

CASE.

I was requested to see a lady, aged thirty-four years, who, on August the 9th, 1819, had, in a fit of insanity, jumped out of a two pair of stairs window, and produced a compound dislocation of the tibia and fibula at the outer ancle. At the lady's residence I met Mr. Stephens, a surgeon residing in Hunter-street, Bruns-

wick-square, who had been called immediately after the accident. As she appeared almost insensible, and Mr. Stephens feared an injury to the brain, he took away twelve ounces of blood. When he examined the ancle, he found the malleolus externus of the fibula projecting through the wound, but unbroken, the tibia dislocated and broken, and the foot very much turned inwards. He extended the foot, and thought that the bones had exactly returned into their natural situation; adhesive plaster was applied upon the wound, and its edges nicely adjusted. She was placed on a mattress with the limb upon the heel, and with a splint on each side of the leg. For seven days she complained of little pain, and had but slight constitutional disturbance; on the day week from the accident, I was requested to see her, and finding little local or constitutional irritation, I recommended that the limb should not be disturbed, and the dressings were not removed.

On the 10th day from the accident, Mr. Stephens finding her in more pain examined the wound, and found that it had not adhered.

On the 12th day, a considerable discharge issued from the wound.

On the 16th day a slough had separated and exposed the bones, which appeared shattered and projecting. On this day I again saw her, and upon examining the ancle found the astragalus projecting, and a portion of it broken; and as the surrounding parts were dead I removed the projecting bone. Introducing my finger into the wound as soon as the astragalus had been separated, the tibia was found to be shattered, and the os calcis broken into many pieces. As her pulse was 100 and small, and her

strength was failing, I immediately recommended her to submit to the operation of amputation, to which she consented.

On the Monday following, the stump was dressed by Mr. Stephens, and the greater part was adhering.

Two of the ligatures separated on the 10th day, and the other came away on the 16th day.

September 29th. The stump was healed, excepting about the size of the section of a pea, and she had no complaint remaining excepting a sore upon her back, and pain in her left foot.

It is proper to mention that she hurt her spine and kidneys by the fall, so as to discharge urine tinged with blood for three weeks after the accident.

The other ancle also was most severely injured, and she suffered exceedingly from pain in it.

Upon examination of the amputated limb, the tibia was split up from the malleolus internus to the extent of three inches; the fibula was unbroken; the astragalus was broken and detached; and the os calcis was fractured into several pieces.

I have lately had another case of the same kind in which I was obliged to amputate. *(See plate.)*

(5.) *The Dislocation of the Tibia at the outer Ancle,*

Dislocation outwards.

Produces much more injury and danger than that at the inner, and amputation will be more frequently required for it, because both the bones and soft parts suffer more than in the dislocation inwards.

(6.) *It sometimes happens that when the Bone is replaced it will not remain in its Situation, and all the Symptoms of the Injury become renewed.*

This circumstance arises when the tibia in the dislocation outwards is obliquely broken, and only a small portion of the articulating surface remaining on the dislocated extremity of the tibia, it will not rest on the tibia when it is reduced. Oblique fracture with dislocation.

Mr. Andrews, of Stanmore, and Mr. Foote, of Edgeware, consulted me on the following case.

CASE.

Mr. Andrews and Mr. Foote were sent for on August the 9th, 1817, to the Hyde, six miles from London, to visit Charles Tomlin, a higgler, forty-eight years of age, who, falling in a state of intoxication, the wheel of his cart passed over his left leg, and produced a protrusion of the bones through the integuments at the outer ancle. Mr. Andrews, reduced the dislocation in the evening of the accident. On the same night, Mr. Andrews and Mr. Foote having visited him again, found his pulse very quick, and spasms in the limb, which had again displaced the bone. They gave him a large dose of opium, and succeeded in reducing the bones.

On the 10th, he had a very quick pulse, accompanied with strong spasms in the limb, but not sufficiently severe to displace the bone.

On the 11th, I was requested by Mr. Andrews, and Mr. Foote, as I was going through the village, to stop and see this man; and

as soon as the bandages were removed, a violent spasm threw the bones from the astragalus, and all the efforts I could make would not replace them. Seeing, therefore, no hope of the man's recovering without the amputation of the limb, I immediately proposed it, and he readily gave his consent.

For three or four days he had a great deal of nervous irritation, which was most effectually relieved by occasional doses of opium and æther.

On the 18th the stump was inflamed, and in some parts sloughy; and on the 22nd it bled profusely.

On the 25th a poultice was applied; and from this time the appearance of the stump improved, and he proceeded without interruption in his recovery. In a month he returned to his home at Bushey, a distance of seven miles.

Upon examination of the limb, I found the cellular membrane around the ancle loaded with extravasated blood; the ligamentum annulare tarsi was torn. The muscles were all remaining whole, though some of them, as the peronei, were much put upon the stretch. The fibula was broken one inch above the lower extremity of the malleolus externus, which remained in its place, still united by its ligaments to the tarsus. The tibia was split down from two inches above the joint, leaving the greater part of the articulating surface still resting upon the astragalus; but the remaining portion of the articulating surface, with the shaft of the tibia and the fibula, passed through the wound at the outer ancle. If, therefore, the bone had been again returned to its situation, it could not have remained there, from the small portion of

articulating surface attached to it; and if the projecting portion had been removed by the saw, it would not have adapted itself to the portion of the tibia which remained attached to the astragalus.

(7.) *The division of a large Blood-Vessel might, with an extensive Wound of the Integuments, lead to a necessity for Amputation;*

Division of an artery.

But I should not, on that account, at once proceed to the operation. The case from Mr. Sandford, of Worcester, sent me by Mr. Carden, clearly shews that the division of the anterior tibial artery does not, if it be well secured, prevent the patient's recovery. I also once saw a compound fracture close to the ancle-joint, accompanied by a division of that artery; yet, although the patient was in the hospital, and being a brewer's servant possessed the worst constitution to struggle against severe injuries, this man recovered without amputation.

The posterior tibial artery is a vessel of more importance, and is accompanied by a large nerve, which would not be likely to escape injury when the artery was divided by the dislocated bone. Yet the magnitude of the anterior tibial artery, and its free anastomosis with the posterior, would not entirely preclude the hope of preserving the foot under an injury of the posterior tibial artery.

(8.) *Mortification of the Foot*

Gangrene.

Sometimes ensues, and becomes a sufficient reason for amputating the limb; but this must be generally done when limits appear to be set to the extension of the mortification. However, it may be observed, that in the mortification which ensues from the division

of a blood-vessel, where the brachial artery had been divided, and the elbow-joint dislocated, I have seen the arm removed above the injured part, whilst the limb was still dying towards the seat of the wounded artery, and the patient was restored to health. And I have also known a case of popliteal aneurism, in which the artery and the surrounding parts were so compressed by the swelling, that mortification began at the foot, and was extending to the knee; and, although no limit was yet set to the mortification, the limb was amputated, and the patient recovered. So that mortification, when it arises from injury to a blood-vessel, or other local injury in a healthy constitution, admits of a practice different from that which is pursued in mortification arising from constitutional causes.

Contusion.

Excessive Contusion may be another reason for Amputation; And, therefore, in those cases in which heavy laden carriages pass over joints, and bruise the integuments so as to occasion the formation of extensive slough, and produce at the same time, generally, the worst examples of compound dislocation, in regard to the state of the bones, I should immediately amputate; for such cases are very different from those which are caused by jumping from a considerable height, from a carriage rapidly in motion, or by a fall in walking or running.

Suppuration.

Extensive Suppuration will also be a reason for Amputation. I have known, after an attempt to save the limb, the patient have more extensive suppuration than his constitution could support, followed by an ulceration of the ligaments, by which the

joint became additionally exposed, and the bones were again displaced; hence there arose an absolute necessity to remove the limb for the preservation of his life.

(9.) *A necessity for Amputation may be also produced by Exfoliations of Portions of Bone,*

Exfoliation.

Which, locked in the surrounding parts of the bone, are incapable of becoming separated, and thus keep up a state of continued irritation. My friend, Mr. Hammick, had the kindness to send me a specimen of this kind, which he was obliged to amputate. The loose portion of bone was seated between the lower extremity of the tibia and fibula, and reached to the ancle-joint; both the bones had been broken, and had become reunited, and the uniting medium had inclosed and incarcerated the dead portion of bone. It is probable, from the appearance of the parts, that this portion of bone never would have been able to escape from the place in which it was locked. *(See plate.)*

(10.) *Excessive Deformity of the Foot*

Deformity.

Will also give rise to a necessity for amputation; and this deformity will take place in three directions. First, when the foot is suffered to turn outwards, whilst the leg is placed upon the heel, in the dislocation inwards. Secondly, when it is turned inwards; and thirdly, when the foot remains pointed. The first is best opposed by placing the leg upon its outer side, when that is compatible with the treatment of the wound; in the second case it is best to keep the foot on the heel; and in both cases, splints, having a foot-piece both on the inner and outer side of

the foot, must be applied: the third requires similar splints, and a tape, as a stirrup, placed under the foot, and fastened to the splint on the fore and middle part of the leg to keep the foot supported; and the splints should be so padded as to preserve it in its proper direction. *(See plate.)*

The following case from Mr. Norman, of Bath, shews the necessity for amputation, when great deformity is permitted to occur.

CASE.

I was sent for to Bradford, some years since, to amputate a leg directly after an accident of this kind. I found the lower extremity of the tibia, with the astragalus loosely attached to it, projecting at the inner ancle. The wound was not large, and the soft parts were little injured. I removed the astragalus, and reduced the tibia, leaving it to rest upon the os calcis. I did not again see my patient during the healing of the wound; I believe it got well without any severe symptoms, but the os calcis became drawn up against the posterior part of the tibia, to which it firmly united, and the foot became immoveable, with the toe pointed downwards. In this state he came to Bath two years afterwards, when I amputated the leg, and the patient did well.

Bath, August 2nd, 1819. GEORGE NORMAN.

(11.) *Amputation has been recommended in those Cases in which Tetanus occurs after this Injury.*

Tetanus. Of tetanus I have seen one case from compound dislocation of

the ancle, and have heard of another. That which I saw was in a Mr. Yare, stable-keeper, who had a compound dislocation of the tibia inwards, and in whom I reduced the bones, and placed the limb on its outer side. For a few days he proceeded without any alarming symptoms. The only circumstance in which his case differed from what I expected was in the slight inflammation which succeeded upon the joint, for the restorative process seemed to be scarcely established in him. When I paid him my morning visit, several days after the accident, he said, "Sir, I believe I have caught cold, for my neck is stiff;" and as he said this, with his lower jaw raised and his teeth closed, I begged him to shew me his tongue, to ascertain if his jaw was locked; and he tried to open his mouth, but was unable to do so. I then desired that Dr. Relph might see him, who did all that his mind could suggest to arrest the progress of the symptoms, but unsuccessfully, as the different muscles of volition became affected in the back, the extremities and the abdomen, until he was exhausted by irritation. To amputate under such circumstances would be most unjustifiable, as far as the experience of cases in this climate will enable me to form an opinion. I have not seen amputation performed for compound dislocation of the ancle, but I have seen it performed for compound fracture just above the joint, and it seemed to me to precipitate the fatal event. I have also known, in one case, the finger amputated for tetanus arising from injury to it, yet the patient died; and I have also heard of a third case in which it was practised, but still the issue was fatal. There is a species of *chronic tetanus*, which sometimes even succeeds wounds, and which will occasionally subside, and, apparently, the patient recovers,

although little be done by medicine, and nothing by surgery; in such cases it would not be justifiable to amputate. If any medicine be efficacious, submurias hydrargyri, with opium, is that under which I have seen the majority of these cases recover: and opium should also be applied to the wound.

(12.) *A very irritable State of Constitution*

Constitution irritable.

Will sometimes render all treatment unavailing to save the limb, and will now and then prove destructive, even if the operation be performed. There are some persons originally constituted with so irritable a system, that the slightest injuries will destroy them. There is a much greater number whose constitutions, originally good, have been so much injured by excess, by want of exercise, by over exertion of mind, by drinking freely of spirits and eating but little, that to them the slightest accidents prove fatal.

CASE.

One of the most curious examples of this kind which I have seen was in a man who worked at Barclay's Brewhouse, in the Borough. The circumstances were these:

On Saturday he was turning a cask, and a splinter of wood entered his thumb, which he immediately drew out.

On Sunday night he requested his wife to rise and make him a poultice; for his thumb, he said, was painful.

On Monday he sent for Mr. John Kent, surgeon in the Borough, who found his thumb inflamed and painful.

On Tuesday the inflammation had extended to the hand and fingers.

On Wednesday a swelling appeared at the wrist, above the ligamentum annulare carpi, and the man had a great deal of irritative fever, and was obliged to keep his bed.

On Thursday, after lecture, Mr. Kent came to me, requesting I would see this man, who had been delirious during the night; his arm being much convulsed, and his body becoming generally so. I went with Mr. Kent, and feeling the thumb, discovered a fluctuation in the theca. I put a lancet into the extremity of the thumb, and a considerable quantity of pus issued. Gratified with the expectation of his being relieved by the discharge of the matter, I was going out of the room to express this feeling to his friends, when I heard a rustling on the bed behind me; and upon Mr. Kent and myself turning back, we saw him under the influence of a convulsive fit, which raised him in his bed, and in which he fell back and expired.

Living as these persons generally do, principally upon porter and spirits, they have constitutions which render them the worst subjects for accidents.

The following case shews the violent symptoms and quick dissolution which will, from the same cause, occasionally ensue in compound dislocation of the ancle.

CASE.

On June the 10th, 1809, I was requested to go immediately to Gracechurch-street, to see a Mr. Fenner, who, in walking opposite to the City of London Tavern, had slipped from the foot-

way and produced a compound dislocation of the ancle. The tibia projected at the inner ancle; the fibula was broken; and the skin was tucked in under the extremity of the tibia.

First: I immediately procured a mattress for him, instead of a feather-bed.

Secondly: A many-tailed bandage; splints lined with wool; and pillows and tapes.

Thirdly: The skin was divided, and the bone reduced; but it was much opposed by violent spasm of the muscles.

Fourthly: The edges of the wound were closely adjusted.

Fifthly: The bandage and splints were applied; and the limb was placed upon pillows on its outer side, with the knee bent.

Sixthly: Bled to 14ʒ, and opium given; tinct. opii. gtt. xxx.

June 11th. His night had been restless; his tongue was white; his pulse beat 110 strokes in a minute; he had violent pains in the ancle, and had vomited. Ordered oleum ricini, as his bowels had not been relieved. Evening: he had almost constant spasms of the muscles of the leg; he had not slept, and had no appetite. The oleum ricini had produced four evacuations.

June 12th. His pulse was 120; his tongue more furred. He had violent and very frequent spasms. He had nausea, but had not vomited since the last report. He had had one evacuation. Blood was extravasated about the ancle; and a sanious serum was discharged from the wound. Ordered opium.

June 13th. Had slept three hours. There was some inflammation about the wound, and swelling of the leg, with spasms, but they were less violent than yesterday. A poultice was applied

to the ancle, and fomentations ordered. Pulse 120; his tongue was very much furred. Evening: in most violent pain; he was ordered submurias hydrargyri five grains, with two grains of opium, and the saline medicine with antimony.

June 14th. The spasms continued, but the pain had in a great degree ceased. He had had several evacuations, but had been delirious during the night. The limb was but little swollen; the foot appeared slightly inflamed, but there was no healthy discharge, nor any granulations beginning to form. The former treatment was ordered to be continued.

June 15th. He had passed a bad night, being delirious through a great part of it. He had a violent spasm in the limb this morning, which produced a slight hæmorrhage, which was stopped by pressure. His leg was swollen, and the wound appeared to be without action. His pulse was equally quick, and he took no nutriment.

June 16th. He had spasms in the thigh of the same side, and in the other leg, as much as in the injured limb; in other respects he remained the same.

June 17th. He was delirious during the previous night, and bleeding was again produced by the violence of the spasms. His pulse was considerably quicker than before.

June 18th. He died at four o'clock in the afternoon.

Persons who are much *loaded with adeps* are generally very irritable, and bear important accidents very ill; indeed they frequently perish, whatever plan of treatment be pursued: to this

statement, however, there are exceptions in those who, though corpulent, are still in the habit of taking much exercise, as they will retain some vigour of constitution; and in such persons the limb may be attempted to be saved, as in the case described by Mr. Abbott, surgeon at Needham Market; but in those who have become extremely fat, and who have been addicted to habits of indolence, there is but little chance of preserving life but by amputation.

Corpulent persons.

Having thus endeavoured to explain what has fallen under my own observation, and what I have been able to learn from others upon this difficult subject, I beg leave to express a hope, that any of my friends, who may have had cases under their care which would throw further light upon the subject, will have the kindness to communicate them to me, whether they make for or against the advice that I have given, as I have no further wish but that all the points respecting this severe accident may be fully elucidated and established; and shall only add, that the observations which I have made in favour of saving the limb in compound dislocations of the ancle-joint, will apply much more strongly in country practice than in that of the large hospitals in London.

Invitation to correspondence on the subject.

The Ancle is sometimes dislocated by Ulceration.

Sept. 23rd, 1823. With Mr. Dixon, surgeon of Kennington, I visited Mr. P., a patient of his, who had a dislocation of the ancle produced by ulceration. An ulcer existed at the inner ancle, which had discharged synovia. The ancle-joint was red and

greatly swollen, the foot drawn outwards by the action of muscles, and the internal malleolus thrown inwards upon the astragalus. The tibial arteries were greatly stretched; and the fibula, by its pressure on the malleolus externus, produced considerable and constant pain. Mr. P. is a very old man, and dying of the disease.

FRACTURES OF THE TIBIA AND FIBULA NEAR THE ANCLE-JOINT.

Fracture of the fibula.

THE *fibula* is frequently broken from two to three inches above the ancle-joint, and the patient instantly becomes conscious of the accident by feeling a snap a little above the outer ancle; by the pain which he suffers in his attempt to bear upon the foot; by his inability to place his foot flat upon the ground, resting it rather on the inner side to throw the bearing of the body upon the tibia; and by pain and a sensation of motion at the injured part when the foot is bent or extended. The surgeon discovers the nature of the accident by rotating the foot with one hand, and by grasping the lower part of the leg with the other; at each rotation a crepitus is generally felt. There is also frequently an inequality of the bone at the broken part, which assists in pointing out the nature of the injury.

Its cause.

The cause of this injury is a blow upon the inner side of the foot, or some violence which forces it outwards against the lower extremity of the fibula; and I have known it broken by distortion of the foot inwards. A fall laterally, whilst the foot is confined

in a deep cleft, produces this accident. I broke my right fibula by falling on my right side whilst my right foot was confined between two pieces of ice, and I could with difficulty support myself to a neighbouring house by bearing upon the inner side of my foot. I went home in a carriage, and every jolt of it gave me pain at the fractured part as I suspended my leg upon my hand. I knew that the bone was broken by the severe snap which I felt in the part at the moment of the accident.

Its treatment.

The treatment which this injury requires is, to apply a many-tailed bandage upon the limb, and to keep it wet with a lotion of spir. vini. ʒ aquæ ʒ v.; to apply a splint, with a foot-piece on each side, padded with cushions in such a manner as to preserve the great toe in a line with the patella, an invariable rule on these occasions; and to place the leg upon its side in the semiflexed position, so as to relax the muscles, and render the patient's position as easy as possible.

Lameness from neglect.

A want of attention to the treatment of this accident leads to permanent lameness. Dr. Blair, a naval physician in the American war, informed me that he found great difficulty in walking the streets of London on one side of the way, but upon the other he walked better than on flat ground; and when I remarked his lameness, and inquired into its cause, he informed me it had arisen from a fracture of the fibula, which happened many years ago; and to which not having applied splints, the foot became twisted, so that he walked better upon an inclined plane than upon flat ground.

FRACTURES OF THE TIBIA AT THE ANCLE-JOINT.

Fracture of the tibia.

The tibia is often broken into the ancle-joint, or through the bone a little above it; and these fractures pass either obliquely inwards, or obliquely outwards: the first in a line from the usual seat of fracture of the fibula, that is, from one to two inches above the external malleolus to the inner ancle: the second from one to two inches of the tibia above the ancle, downwards and outwards into the joint.

The first is distinguished by crepitus at the ancle when the foot is rotated, bent, or extended; and by a slight inclination of the foot outwards. If the fracture does not enter the joint, but obliquely crosses the tibia above it, the lower part of the tibia slightly projects over the malleolus internus.

Diagnosis.

Treatment.

The treatment in this case consists in using evaporating lotions; the many-tailed bandage; splints with a foot-piece to each, padded so as to incline the foot inwards, and to bring the toe into its natural line with the patella, which is easily effected with the splints to which I have alluded.

Oblique fractures.

The symptoms of the oblique fracture of the tibia downwards and outwards into the joint are, as in the former case, a crepitus upon rotation, flexion and extension; but the foot is slightly inclined inwards, and the malleolus externus projects more than it naturally would. The same bandages and splints are to be used as in the former case; and the position in both these accidents should be as follows:

Treatment.

The leg should be raised so as to bend and elevate the knee; and the limb should rest upon the gastrocnemius muscle, and

upon the heel. The splints will support the foot on each side, and the leg should be supported by a pillow, reaching from the knee to beyond the foot, secured by tapes around it. I have seen both these cases do well when the patient and his leg rested upon the outer side; but the advantage of placing the limb upon the heel is, that it gives the surgeon an opportunity of observing the least deviation in the line of the foot, relatively to the axis of the leg; and this is also an easier position to the patient.

Dislocation upwards from fracture.

The outer portion of the lower extremity of the tibia, at the part at which it joins the fibula, is sometimes fractured and split off from the shaft of the bone in jumping from a considerable height: the foot then rises between the tibia and fibula; a dislocation of the tibia inwards is produced, and the foot is elevated between the two malleoli. The treatment required in this case is the same as in the dislocation inwards.

Oblique compound fractures.

Oblique compound fractures into the ancle-joint generally do well if care be taken to produce adhesion of the wound, which is to be effected by applying lint, embued in blood, to the lacerated skin, and by leaving it there until it separates spontaneously. The same bandages and splints are required as in simple fractures, but the position must be varied according to the situation of the wound. Even if suppuration occurs the patient will generally recover, unless he be much advanced in years.

But if, with compound fracture into the joint, there be much comminution of bone, and hæmorrhagy from any large vessel, it will be proper to amputate immediately, more especially if the patient be obliged to obtain his bread by his labour; for after recovery, under great comminution, the limb will bear but slight exertion.

DISLOCATION OF THE TARSAL BONES.

SIMPLE DISLOCATION OF THE ASTRAGALUS.

Junction with other bones.

THE astragalus is connected above and on each side with the tibia and fibula by its trochlea; below it has articulatory surfaces for its junction with the os calcis, to which it is united by means of a capsular and strong interosseous band of ligament; and anteriorly to the os naviculare, by a capsular, broad, and internal lateral ligament. A simple dislocation of the astragalus sometimes, though rarely, occurs; a compound luxation is still more rare.

Simple dislocation.

A simple luxation of the astragalus is a most serious accident, being very difficult to reduce; and should the reduction not be effected, the patient is ever after doomed to a considerable degree of lameness.

CASE I.

Being sent for into the country to visit a patient, the surgeon,

Mr. James, of Croydon, whom I met there, requested me to see a gentleman who had a dislocation of the foot, which had happened several weeks before, but had not proceeded to his satisfaction. Upon examination, I found the astragalus dislocated outwards, and the tibia broken obliquely at the inner malleolus. Every attempt to reduce it was made which Mr. James, who is an extremely well-informed man, could adopt; five persons kept up a continued extension when the accident first happened, but without effect; the patient was then taken home, and several persons were employed in extending the foot, and it was thought, after a time, with some success; but the reduction could not, by all their efforts, be rendered complete, as the astragalus still remained projecting upon the upper and outer part of the foot. The extension could not be carried further; the integuments sloughed from that which had been already made: and the wound was a long time in healing. The limb now deviates much from its natural shape; the toes are turned inwards and pointed downwards; there is some little motion at the ancle, and only a slight degree of it between the projecting and raised astragalus, and the other bones of the tarsus.

This accident, then, is of a most serious nature; for the gentleman in question had placed himself under the care of a most intelligent and persevering surgeon, and yet the attempts which he made at reduction were not successful; merely from the nature of the accident, and not from any fault in the means which were pursued. In these cases the use of pullies will be required, and the action of the muscles should be lessened by tartarized antimony. *(See plate.)*

I attended the following case with my friends, Mr. West, surgeon of Hammersmith, and Mr. Ireland, surgeon in Hart-street, Bloomsbury. It is highly interesting and instructive; and shews most clearly the necessity that surgeons should be upon their guard in amputating limbs, and in performing operations, as the resources of nature are sufficient, under very formidable circumstances, to effect restoration.

CASE II.

On July the 24th, 1820, Mr. Downes had the misfortune to dislocate the astragalus by falling from his horse. The accident happened at Kinsal Green, about six miles from London; and Mr. West, surgeon at Hammersmith, who was called in to him, made an attempt to reduce the dislocation, which could not be effected. The patient was largely bled; the limb was placed in splints; Goulard's lotion was applied, and an anodyne given. The patient felt great pain, and a sense of pressure against the skin and ligaments, on the evening of the accident. A purge was directed to be given, and anodynes occasionally in saline draughts.

On the following day, the 25th, Mr. Ireland, who had visited Mr. Downes the evening before, called upon me, and requested me to accompany him to see the patient, and to meet Mr. West. When I examined the limb I found the astragalus dislocated forwards and inwards; and the fibula appeared to be broken a little above the joint. I made an attempt to reduce it, but found the bone immoveably fixed in its new situation, projecting so as to make the nature of the case perfectly clear, and bearing so strongly against the skin that a slight incision would have exposed

it. My first impression was, that I ought to dissect away the astragalus; but aware of the resources of nature in accommodating parts under luxations, and in restoring the limb to usefulness, I observed to Mr. West, and to Mr. Ireland, that I would not operate, and that perhaps the skin might give way, and the bone become exposed, when we should be justified in removing it. The previous treatment was continued.

On the 26th he had some irritative fever, when the saline medicine with antimony was given.

On the 28th there was considerable local irritation, and leeches were applied.

On the 29th the leeches were repeated and the lotion continued.

On August the 10th the skin began to be disposed to slough, opposite the projection of the astragalus at the inner ancle.

On the 14th, fomentations and a yeast poultice were directed to be applied, and bark and wine were given.

On the 16th the skin sloughed.

On the 20th there was a great discharge of pus, and the astragalus became exposed. The same means were continued; and the inflammation and discharge gradually lessening, the wound was dressed with lint and adhesive plaster.

The astragalus gradually became dislodged; the ligament sloughing or ulcerating. In September, the patient was able to be removed to London.

On October the 5th, 1820, I again saw him, and finding the astragalus very loose, removed it with forceps, dividing only some slight ligamentous adhesions. The bleeding was trifling, and was suppressed by the application of lint alone.

In December some slight exfoliations occurred, which produced pain and inflammation; but at the end of the month he began to walk.

After the astragalus was removed, soap plaster was applied; and Mr. Downes gradually recovered his strength, and was able to walk without the aid of a stick.

In October, 1821, he had slight motion at the ancle, which has been gradually increasing. *(See plate.)*

COMPOUND DISLOCATION OF THE ASTRAGALUS.

CASE I.

In the first case of this accident which I had an opportunity of witnessing, the astragalus was thrown inwards and forwards upon the os naviculare; and when I afterwards saw the limb upon the table of the dissecting room, it having been removed by amputation, I exclaimed, surely that limb might have been saved.

CASE II.

In the case of which an account was sent me by Dr. Lynn, of Bury St. Edmunds, it will be seen that the discharge of the astragalus, in a compound dislocation of the ancle-joint, did not prevent the patient's recovery; for he says, "In five weeks a portion of the astragalus separated, and another piece a week afterwards, which, when joined, formed the ball of that bone."

CASE III.

Mr. Trye, of Gloucester, had also under his care a case of compound luxation of the astragalus, in which he cut out the luxated bone, and the patient had a good recovery, with a tolerably useful foot.

The following case was under the care of Mr. Henry Cline, in St. Thomas's Hospital:

CASE IV.

Martin Bentley, aged thirty years, was admitted into St. Thomas's Hospital at twelve o'clock at noon, on June 21st, 1815. He had just before been overpowered by some stones which he was endeavouring to sling into a ship's hold, by which he was knocked down, and which fell upon him, occasioning a compound fracture of the tibia and fibula of the left leg, near the middle, with a dislocation of the astragalus of the other foot, from the other bones of the tarsus.

As there was much laceration of the skin and muscles, Mr. H. Cline thought it right to amputate the limb below the knee, which was done about three hours after his admission. He complained of much pain during the operation, with frequent jerking of the limb: the muscles were extremely rigid: five ligatures were applied, and the wound dressed as usual.

The other foot presented the following appearance: The protuberance of the os calcis had nearly disappeared; but this bone projected laterally, and on the outer side much beyond the outer malleolus; just under which, however, was a remarkable depression. Immediately below the inner malleolus was a

remarkable and unnatural projection. The whole foot seemed somewhat displaced outwards, the toes turning out. The astragalus must here have been dislocated from both the navicular bone and os calcis, and thrown inwards, so as to have its inferior articulatory surfaces for the os calcis resting on the inner edge of that bone.

After the amputation, the dislocation was reduced by fixing the knee, having the thigh bent at right angles with the body; then laying hold of the metatarsus and protuberance of the os calcis, and drawing the foot gently and directly from the leg. During this extension, Mr. H. Cline put his knee against the outside of the joint, and the foot being pressed against it, the os calcis and navicular bones slipped into the place, carrying with them the rest of the foot, and the deformity disappeared. He was then carried to bed, and an outside splint was applied, being well padded, and secured by tapes; and the leg, as far as could be, placed on the outer side. Goulard's wash was applied.

June 24. The lead wash was left off, and soap cerate put on the right leg.

June 25. The cerate has blistered his leg in several places, and he complains of more pain than yesterday at his ancle.

June 28. The stump, which is going on well, dressed to-day; one ligature came away. The pain in his ancle has subsided.

July 1. Complains of uneasiness about the epigastrium, and sickness; pulse 112 and hard; ʒvviij. blood taken from the arm.

July 2. All untoward symptoms have disappeared.

July 4. Two ligatures came away. A sore, which is the effect of the soap cerate, on the inner malleolus, is dressed with wax

and oil. He is now capable of raising his leg, which, however, is benumbed.

July 13. The ligatures not appearing disposed to come away, a piece of whale-bone was fixed on the side of the stump, to which they were attached, and so kept constantly tight. Was put on the hospital diet to-day; had previously been on milk diet.

July 19. One of the ligatures was removed with some difficulty by Mr. H. Cline; the other came away easily on the following day.

August 7. The man walked in the square for the first time since the accident.

August 26. He went out, and was capable of walking tolerably well.

I conversed with Mr. Henry Cline on the subject of these accidents; and Mr. Green, who saw the preceding case in the commencement, sent me the following letter respecting it:

Lincoln's Inn Fields, August 19, 1819.

My dear Sir,

In the notes of Martin Bentley's case, which I made at the time when he was under Mr. Henry Cline's care in St. Thomas's Hospital, I find it stated that the right astragalus was dislocated inwards; that is, that the os calcis, with the rest of the foot, was thrown outwards: and the description which I have there given of the appearance is, that the whole foot seemed to be somewhat displaced outwards; that the os calcis projected laterally much beyond the outer malleolus, whilst the protuberance of that bone

had nearly disappeared; and that, in consequence of the astragalus retaining its situation, there was a remarkable depression beneath the outer malleolus, between it and the displaced os calcis; and as remarkable a projection, produced by the astragalus, below the inner malleolus. This accident, which was accompanied with a compound fracture of the opposite leg, had been produced by the fall of several large stones. The reduction of the dislocation was effected without difficulty. First, by fixing the knee; then by making extension of the foot, gently and directly from the leg, by laying hold of the heel with one hand, and placing the other on the dorsum of the foot: and, lastly, by pressing the foot inwards, whilst a counter pressure was made with the knee upon the lower extremity of the tibia on the opposite side. The foot was afterwards placed on its outside, and secured upon a well padded splint.

In the case of compound luxation of the tarsal bones, likewise under the care of Mr. Henry Cline, it appears, according to my notes, that the astragalus was displaced outwards; that is, that the other tarsal bones were thrown inwards. I find that the appearances are described to have been, that the foot was turned considerably inwards; that the articular surface on the head of the astragalus, which is received into the cup of the navicular bone, was exposed through an extensive, but tolerably clean, cut through the integuments; and that the articulating surface of the os calcis, with the astragalus, might also be perceived on the outer side. The accident was said to have been occasioned by the fall of a heavy stone, which had struck his heel. Reduction of the dislocated parts was accomplished, first, by bending the leg so as

to relax the muscles, and then by extending the foot in the manner described in the former case, rotating it at the same time outwards.

The patient was a robust, but not corpulent, labouring man, between forty and fifty years of age. He stated that he had been in the habit of drinking, and that he was occasionally subject to gout.

You have already, I believe, been made acquainted with the particulars of the progress of the case, of which the most remarkable features appeared to be, that the primary constitutional irritation was violent, but of short duration; and that his recovery was retarded by extensive erysipelatous inflammation, which terminated in sloughing, and by the formation of matter at the part, accompanied by irritative fever and loss of strength; but that his recovery, although tedious, was complete.

Joseph Henry Green.

For the following case I am also indebted to Mr. Green, whom I am proud to call my colleague, and who is an admirable anatomist, an excellent surgeon, and an amiable man.

CASE V.

Thomas Toms, twenty-three years of age, was admitted into St. Thomas's Hospital on July the 14th, 1820. He had fallen, whilst engaged in his business, that of a bricklayer, from a three story scaffold; and his descent had been arrested by his foot catching between the spikes of an iron railing, from which he hung with his head nearly touching the ground. A wound was

found extending beneath the inner malleolus of the left leg ; and the head of the astragalus, which was torn from the articulatory surface of the os naviculare, protruded through the divided integuments. Part of the articulatory cartilage of the displaced bone had been separated, and the bone was girt by the edges of the wounded skin, which was puckered under it. The tendons of the tibialis anticus and of the flexor muscles were tightly stretched, and the foot was turned rather upwards and outwards. Further examination shewed that the posterior tibial artery was torn through, and that the accompanying nerve was partially lacerated.

An attempt was made to reduce the luxated astragalus by fixing the knee, after having bent the leg upon the thigh, and by making extension of the foot directly from the leg, laying hold of the heel with one hand, and placing the other on the dorsum of the foot. This, however, failed ; and as it appeared that the skin, which firmly embraced the bone beneath, prevented the replacement, it was divided, and the extension renewed, but with the same unsuccessful result. This difficulty seemed to arise from the small size of the wound in the capsule of the joint, and in consequence of the bone being tightly held by the tendons.

Fearing, then, that the reduction was impracticable, I was led to consider whether the amputation of the leg ought not to be proposed. But Sir Astley Cooper happening to be in the hospital, I requested him to see the case, and after a careful examination of the injured limb he suggested that the astragalus might be removed. I concurred, of course, in this proposal, as it afforded a probability of saving the limb, and I proceeded accordingly to perform the operation. I first applied a ligature on the posterior

tibial artery, which, however, had not bled, the orifice being so contracted that a pin could not have been introduced. I then cautiously used a scalpel, detached the ligaments by which the astragalus is connected with the bones of the leg and tarsus, and found no considerable difficulty in removing the bone. The parts were then readily brought into apposition, and the wound was closed with straps of adhesive plaster. The leg was placed on its outside, resting on a well padded splint, with a foot-piece; the foot was supported above the level of the knee, and the constant use of an evaporating lotion was ordered.

In the evening of the same day slight fever had come on, but the limb was tolerably easy; and the patient had an evacuation of the bowels.

The next day the febrile symptoms had increased. His pulse was fuller and quicker, the skin was hot and dry, the tongue furred, and thirst considerable; but he had slept two or three hours during the night, and the injured part was free from pain. I ordered some febrifuge medicine, and directed that his diet should be low, and that the apartment should be kept well ventilated.

On the third day the fever was slightly increased. He complained of pain at the ancle, which exhibited marks of inflammation, and he had had no stool. Sulphate of magnesia in the infusion of roses was ordered in repeated doses, until the bowels should be affected.

At my visit on the fourth day, I learnt that after having taken five doses of the purgative medicine, two copious evacuations had

been produced. The fever still continued, but his tongue was cleaner and moister. It was now found necessary to loosen the splint-tapes, as the leg had become considerably swollen. Some discharge of pus had taken place from the wound, and the pain complained of the day before had subsided.

On the fifth day I found that he had passed a good night, and the fever was less; but he complained of a sore throat, and had had a slight shivering.

On the sixth day I learnt that he had passed a sleepless night in consequence of pain in the foot and leg, and that his head had been somewhat affected. The pain in the limb had, however, subsided; and there was a copious discharge from the wound.

On the eighth day the fever seemed to be abated; the pulse was tranquil, and was not more than 86, and his bowels were open. The dressings were now removed, and the ligature on the artery came away. The wound had a healthy granulating appearance. He was allowed to take some animal food.

He continued mending till July the 26th. His sleep had been sound and refreshing; he was free from fever, and from pain at the injured part, and his appetite was improved. But on this day it was found necessary to alter the position of the leg, by lowering the foot, in order to favour the escape of matter which collected in a sinus, extending about a third of the leg upwards, behind the inner malleolus.

On July the 29th he began to complain of pain in the leg, and he had some symptoms of constitutional disturbance. These unpleasant effects were produced by the formation of an abscess,

which was opened on the 1st of August, and from which about six ounces of pus was discharged. He became after this tranquil and easy, and the discharge of matter gradually decreased.

On August the 10th I ventured to have him removed into another bed, but without disturbing the splints or pillows. The wound at the ancle was now filled with granulations, and had in part cicatrized.

On August the 25th his health had become again deranged. His skin was hot, his countenance flushed, and he complained of a good deal of pain at the outer ancle, where it rested on the splint. In order to prevent this inconvenience the leg was placed in a fracture box upon the heel, and a poultice was applied to the ancle. On the following day it was evident that matter had formed at the part, and an opening was therefore made, by which about four ounces of pus were discharged.

During the ensuing week a discharge again took place from the original wound. This flow of matter was copious, a considerable quantity being furnished from a sinus, extending to the calf of the leg, and it continued till September the 7th. During this period his leg became œdematous, his appetite declined, and he was subject to slight hectic fever.

Subsequently to that date he rapidly improved: the œdema of the leg subsided, the discharge lessened, and the wound assumed a healthy appearance. He continued to mend till September the 22nd, when we were again troubled with the formation of one small abscess on the inside of the leg, and of another just below the calf of the leg. These were opened, and the discharge of matter gradually subsided.

In the beginning of October the quantity of purulent discharge was trifling. He was now allowed to sit up, and straps of soap cerate only were applied, with a roller.

On October the 25th the discharge had entirely ceased. The parts about the joint were quite sound, and pressure produced no inconvenience. He was capable at this time of performing to a considerable degree the flexion of the foot on the leg, but could not extend it.

He began now to walk a little with the aid of crutches; and continuing to gain health and strength, he was discharged from the hospital on November the 2nd.

He has since resumed his business, and performs its duties without inconvenience. J. H. Green.

DISLOCATION OF THE OS CALCIS AND ASTRAGALUS.

The five anterior bones of the tarsus are sometimes dislocated from the os calcis and astragalus. There is a joint placed transversely between the os calcis and astragalus, and the os naviculare and os cuboides; and this joint is sometimes, but rarely, luxated by very heavy weights falling upon the foot, of which the following is an example:

Simple Dislocation.

CASE.

A man working at the Southwark Bridge had the misfortune to

have a stone of great weight glide gradually on his foot: he was almost immediately brought to Guy's Hospital, and the following were the appearances of the foot. The os calcis and the astragalus remained in their natural situations, but the fore part of the foot was turned inwards upon the bones. When examined by the students the appearance was so precisely like that of a *club foot*, that they could not at first believe that it was not a natural defect of that kind: but upon the assurance of the man that previously to the accident his foot was not distorted, an extension was made by fixing the leg and the heel; the fore part of the foot was then drawn outwards, and thus the reduction was effected. This person was discharged from the hospital in five weeks, having the complete use of his foot.

The following interesting case was under the care of Mr. Henry Cline; and for the particulars I am indebted to his apprentice, Mr. South.

Compound Dislocation.

CASE.

Thomas Gilmore, an Irish labourer, aged forty-five years, was admitted, under Mr. H. Cline, into St. Thomas's Hospital, about eleven o'clock of the morning of March 28th, 1815. Whilst walking at the New Custom House this morning, he received a blow on the heel from the falling of a stone (said to be half a ton weight), which made a wound on the fore part of the ancle-joint, and dislocated the astragalus.

The parts were in the following state: A wound extended from opposite the middle of the base of the tibia, round the upper part of the instep, to the external malleolus, which exposed the articulating surface of the astragalus with the navicular bone on the fore part, as well as that with the os calcis on the outside; from both of which bones the astragalus was displaced: its connection with the tibia and fibula, however, was undisturbed. The tuberosity of the os calcis projected outwards, but the rest of the foot turned in, so that the toes pointed much inwards, towards the opposite foot.

The reduction was effected by extending the foot, and rotating it outwards; the wound was brought together with straps of adhesive plaster; the leg was covered with soap plaster and put in a fracture box, on the heel; the parts were kept uncovered, and a slight hæmorrhage supervening, linen rags, dipped in cold water, were applied.

He was a robust man, had been in the habit of drinking, and says he has been subject to the gout.

March 29. Had not slept much, as on falling asleep spasm was produced; pulse about 80; skin cool; he has taken the sulphate of magnesia, which has produced two evacuations. The part is not tumefied, but has been painful.

March 30. Has passed a very restless night, having been delirious. Pulse 120; skin hot and dry; fauces parched. Does not now seem quite clear in intellect. This morning he has had more than one rigour. A dose of sulphate of magnesia, with infusion of senna, had procured three loose, but healthy stools.

The part has become more swollen and painful. Ordered fever mixture, with ten drops of antimonial wine, every six hours. In the afternoon he had three more stools.

March 31. Is still delirious, and did not sleep last night. Skin very hot and dry; mouth parched; pulse about 112. Has had two stools this morning, without medicine. The rigours still continue occasionally, and he is also affected with tremors. The inflammation is extending up the leg, and a bruise which he received on the same leg is now ulcerating, to which a dressing of wax and oil is applied.

April 1. Has been less delirious than on the two former nights. Pulse 122; tongue cleaner; no stools.

April 2. Has slept better than on the previous nights. Is not at all delirious. Pulse 96 and soft; skin moist, and he has perspired freely; no stools; urine in large quantity, but said to be high-coloured. The tremors have in a great measure left him, and he feels altogether comfortable, except that there is a considerable degree of pain in the injured part, which he ascribes to a rheumatic affection to which he has been subject. There is a slight erysipelatous inflammation of the leg, with some œdema.

April 3. Has passed a tolerably good night; is sensible; pulse 100; bowels costive; the ancle easy.

April 4. Pulse 96; skin moist; has had two stools. The erysipelatous inflammation has extended rather above the internal condyle of the os femoris, and small yellow vesicles have formed; this seems to have proceeded from the bruise on the calf of the leg, which has now gone into a state of superficial ulceration. Soap cerate was applied to this wound, and the spirit lotion on the limb,

as far as the inflammation extended. The wound on the ancle was dressed for the first time to-day; the ligaments appear to be sloughing; the strapping was left off, and wax and oil dressing was applied.

In the afternoon his pulse was 104; seems restless, and says his head feels rather light: had another stool towards evening.

April 5. Has been delirious all night; skin hot and dry; pulse 108, and weak; these symptoms indicate a fever of a different kind to the preceding, viz.: secondary, and sympathetic, with the erysipelas: the wound at the ancle is granulating, and secreting healthy pus; that on the leg is very painful, and has assumed a sloughy appearance: ordered decoction of bark every four hours, with opium, if diarrhœa is produced.

April 6. Is delirious; pulse 100 and weak; skin perspirable; has had two stools; the inflammation extends nearly to the groin; and at one part of the thigh, where the cradle has accidentally pressed the skin, it seems as if it would slough; takes a grain of opium twice a day.

April 7. Slept pretty well; wanders; pulse 110, but strong; skin not very hot; no stool; much pus is discharged from the wound at the ancle.

April 8. Has been restless during the night; pulse 96, with some power; skin moderately hot; is thirsty; delirious; tongue rather foul; bowels costive; his urine, of which he still voids a great quantity, scalds him; pus is forming in different parts of the limb; and the inflammation on the thigh seems now to be stationary.

April 10. Slept well; is not delirious; pulse 96, not weak;

skin not very hot; has appetite; the part is painful, but the inflammation on the thigh is considerably diminished, and the sloughs are circumscribed; pus healthy. A few days since he was ordered a pint of porter daily, which is now increased to two pints.

April 11. Says he occasionally wanders; pulse 100, rather weak; appetite tolerably good; skin moist; has had stools.

April 12. The inflammation is less; the opium which he takes procures him good nights; the wound at the ancle is much the same; the sloughing sore on the calf of the leg better; to-day he was moved into a clean bed, and the limb was placed on the outer side, as he wishes to lie on his side.

April 13. Is composed; pulse 98; skin cool; feels weak; has not much appetite, but likes his porter; the sloughs on the leg separate slowly.

April 14. The limb was returned to its old position on the heel, as he was less comfortable when it was placed on the side.

April 17. Pulse 92, and weak; has little or no appetite; the bark and opium were left off to-day, as they seem to affect his head; a poultice was applied to the wound on the calf of the leg, and strapping on that at the ancle; it being hoped, that by the support thus afforded, the discharge would be diminished.

April 22. As his appetite does not improve, and he gets no sleep, the bark and opium were resumed, and an additional pint of porter given, so that he now takes three pints a day. His pulse is not so weak; spirits good; at times he is in great pain; strapping is applied to all the wounds; the sloughs have not separated.

April 28. Continues much the same. One slough on the leg

has separated, that at the ancle not yet; the part is tolerably easy; the discharge not great.

May 15. All the sloughs have separated, and the wounds are gradually healing up, but he is very weak, and his appetite is bad.

May 20. Oil was ordered to be rubbed on such parts of the leg as would bear it, and then washed off, as it was thought this would promote circulation in the limb, which was œdematous; however, this was soon discontinued, as it occasioned inflammation. About this time his medicines were omitted.

May 29. An abscess, which had formed on the calf of the leg, was opened.

July 14. All the dressings were left off to-day: he is perfectly capable of lifting his leg, and has slight flexion and extension of the foot.

After this time he rapidly improved: and having left his bed, in a short time was walking about the square on crutches.

September 12. He went out, being able to walk tolerably well with a stick.

DISLOCATION OF THE OS CUNEIFORME INTERNUM.

I have twice seen this bone dislocated: once in a gentleman who called upon me some weeks after the accident, and a second time in a case which occurred in Guy's Hospital very lately. In both these instances the same appearances presented themselves. There was a great projection of the bone inwards, and some degree of elevation, from its being drawn up by the action of the tibialis

anticus muscle; and it no longer remained in a direct line with the metatarsal bone of the great toe. In neither case was the bone reduced. The subject of the first of these accidents walked with but little halting, and I believe would in time recover the use of the foot, so as not to appear lame. The cause of the accident was a fall from a considerable height, by which the ligament was ruptured which connects this bone with the os cuneiforme medium, and with the os naviculare.

The second case, which was in Guy's Hospital, my apprentice, Mr. Babington, informs me, happened by the fall of a horse, and the foot was caught between the horse and the curb-stone.

The treatment of this injury will consist in confining the bone in its place, by at first binding it with a roller dipped in spirits of wine and water, with which it must be constantly kept wet: and when the inflammation is subdued, a leathern strap is to be buckled around the foot, to keep the bone in its place till the ligament be united.

The metatarsal bones I have never known luxated: their union with each other, and their irregular connection with the tarsus, prevent it; and if it ever happens, it must be a very rare occurrence.

DISLOCATION OF THE TOES FROM THE METATARSAL BONES.

This is a very uncommon accident: but I had a man under my care at Guy's Hospital, who had such a degree of lameness as to

be unable to get his bread by his daily labour, owing to an injury sustained by falling from a considerable height, and alighting upon the extremities of his toes. Upon examination of the bottom of the foot, a considerable projection was found at the roots of all the smaller toes, each of the extremities of the metatarsal bones being placed under the first phalanges of the lesser toes. Several months had elapsed from the time of the accident: and at first, from the swelling of the foot, it had not been detected. No extension at the time when I saw him could answer any purpose, and the only mode of relief was to wear a piece of hollow cork at the bottom of the inner part of the shoe, to prevent the pressure of the metatarsal bones upon the nerves and blood vessels.

The toes are sometimes dislocated, but as the mode of their reduction will be the same as that of the fingers, I shall reserve the subject until the dislocations of the fingers are described.

DISLOCATIONS OF THE LOWER JAW.

Structure of the articulation.

An articular cavity is formed behind the root of the zygomatic process of the temporal bone, which receives the condyloid process of the lower jaw at the time when the mouth is shut; and a prominence which is placed before this cavity receives the lower jaw when the teeth are advanced upon the upper: both the cavity and the prominence are covered by articular cartilage. The condyloid process of the jaw rests in the cavity with an intervening cartilage whilst the mouth is shut, but it advances upon the root of the zygomatic process when the jaw is much opened, or the lower teeth are advanced. Between the condyloid process and the cartilaginous surfaces, an interarticular cartilage is placed, having a double concave surface, which allows of the free motion of the jaw, and of its advance upon the zygomatic articular tubercle; whilst the coronoid or anterior process of the jaw is received between the zygomatic arch and the surface of the temporal bone.

Interarticular cartilage.

Ligaments.

A capsular ligament unites the condyloid process to the temporal

cavity and to the prominence before it, and joins, in its passage from one bone to the other, the edge of the interarticular cartilage; whilst a strong internal lateral ligament passes from the margin of the articular cavity to the inner surface of the angle of the lower jaw.

Muscles. The jaw is drawn upwards and downwards, backwards and forwards, and transversely. Its elevation is produced by the temporal, the masseter, and the pterygoideus internus: its depression by the platysma myoides, digastricus, mylo hyoideus, genio hyoideus, and genio hyo glossus. The jaw is drawn backwards by the temporal muscle, by a part of the masseter: and when the os hyoides is fixed by the digastricus, the genio hyoideus, and genio hyo glossus, it is pulled forwards by a portion of the masseter, and by the combined action of the pterygoidei externi.

The lateral motions of the jaw are principally produced by the contractions of the external pterygoid muscles, which in alternate actions pull the jaw from side to side, and give it, with the other muscles, its grinding action, in which these muscles are assisted by the oblique motion forwards, given to the jaw by the pterygoideus internus.

Luxations. The lower jaw is subject to two species of dislocation, viz.: the *complete* and the *partial*. When the dislocation is complete, both the condyles of the jaw are advanced into the space between the zygomatic arch and the surface of the temporal bone; but when it is partial, one condyloid process only advances, and the other remains in the articular cavity of the temporal bone.

COMPLETE LUXATION OF THE JAW.

Complete luxation.

This is known to have happened by the open state of the mouth, and by the impossibility of closing it, either by the patient's efforts, or by pressure made upon the chin. The lower jaw may be still in some degree approximated to the upper by muscular efforts, but the lower teeth, if the mouth could be closed, would be in a line anterior to the upper. Some degree of depression of the jaw may also still be produced, but to an inconsiderable extent. Thus the appearance of the patient is that of a continued yawning. The cheeks are projected by the advance of the coronoid processes towards the buccinator muscle, and there is a depression just anterior to the meatus auditorius, from the absence of the condyloid process from its cavity. The saliva is not retained in the mouth, but dribbles over the chin; and a very considerable increase of this secretion follows, in consequence of the irritation of the parotid glands. The pain accompanying the accident is severe, but I have never seen any dangerous effect produced by it: on the contrary, the jaw becomes more nearly closed by time, and a considerable degree of motion of the jaw is recovered.

Symptoms.

Causes.

This accident may be caused by taking into the mouth too large a body, as I have known when two boys in play, struggling for an apple, one has forced it into his mouth, and dislocated his jaw. A blow upon the chin, when the mouth is widely opened, produces the same effect. Yawning very deeply is also a frequent cause of the accident.

A sudden spasmodic action of the muscles will produce this dislocation when the mouth is opened, and it has often happened in attempts to extract the teeth, where the mouth has been opened too widely. Mr. Fox, the dentist, whose death we have to deplore as a man of science, excellently well informed in his profession, and a most amiable man in private life, told me that he was called to a lady who had a tooth which required to be extracted, and that in the attempt to do so, a sudden spasm dislocated the jaw.

Reduction.

The jaw must be immediately restored to its situation, and the mode of reduction I shall explain by the following case.

CASE.

Reduction.

A madman, confined in one of the houses in Hoxton, during an attempt to give him some food, which the keeper was obliged to force him to receive, had his jaw dislocated. Mr. Weston, surgeon in Shoreditch, was sent for, who, finding the man very powerful and very unmanageable, preferred rather to send for some other surgeon, to consider with him the best mode of making the attempt at reduction. When I saw the man I thought that a surgeon must be as insane as the patient who would employ the usual means of reduction, and I therefore desired that the keepers would place the patient on a table upon his back, with a pillow under his head, and that he should be held by several persons. I ordered two table forks to be brought me, and wrapped a handkerchief around their points: placing myself behind the patient's head, I carried the handles of the forks into the mouth, on each

side, behind the molares teeth; then directed them to be held, and placing my hand under the chin, I forcibly drew it to the upper jaw, and the bone was easily and quickly reduced.

In the above-mentioned case the handles of the forks were not used as levers, by lifting them; they only rested upon the jaw, which was used as a lever upon them, depressing the processes as the jaw was elevated, and thus directing the bone backwards into its natural situation. But as wood is liable to injure the gums, it is better to substitute two corks, which are to be placed behind the molares teeth on each side of the mouth, and over these the chin is to be raised. They are equally effectual in reducing the bone, and are less likely to injure it, or to bruise the soft parts. It has been recommended in these cases, to use a piece of wood as a lever, by introducing it between the molares teeth, first on one side and then on the other, reducing one side first, and then using the same means to the other. Mr. Fox, in the case before alluded to, thus succeeded: he placed a piece of wood, a foot long, upon the molar tooth on one side, and raising it at the part at which he held it, depressed the point at the jaw on that side, and succeeded in reducing the jaw. He then did the same on the other side, and thus replaced the bone. But the corks, the recumbent posture, and the elevation of the chin, constitute the mode which I prefer.

Corks.

Levers.

In reducing this dislocation, the surgeon generally wraps a handkerchief round his thumbs, placing them at the roots of the coronoid processes, and depressing the jaw, he forces it backwards as well as downwards, when the bone suddenly slips into its

place: but this mode does not so easily succeed as the others, excepting in recent dislocations. When the jaw has been once dislocated, it is very liable to the same accident, and therefore a broad tape, with a hole cut in it to receive the chin, divided into four ends by splitting it on each side some way down, is to be tied over the summit of the head and occiput, to confine the jaw until the lacerated parts have healed, by which the tendency to subsequent luxation is diminished.

Liable to recur.

PARTIAL DISLOCATION OF THE JAW.

Partial dislocation.

In this case, the condyloid process advances under the zygomatic arch on one side only, producing an incapacity to close the mouth; but it is not so widely opened as in the complete dislocation. It is easy to distinguish this accident, as the chin is thrown to the side opposite to the luxation, and the incisores teeth are not only advanced upon the upper jaw, but are no longer in a line with the axis of the face. The cause of this accident is a blow on the side of the face when the mouth is opened, and in one case it occurred from vomiting in sea sickness. In this example, the lady, Miss Belfour, daughter of the late Admiral Belfour, of Portsmouth, reduced her jaw by an oyster-knife, which she turned half round upon the side of the jaw between the teeth, and so returned it to its place.

Symptoms.

In this injury, the lever of wood reduces the bone most easily,

but the cork may be used on one side, and the chin be elevated, as in those cases in which the dislocation is complete.

SUBLUXATION OF THE JAW.

Symptoms. As in the knee, the thigh-bone is sometimes thrown from its semilunar cartilages, so the jaw appears occasionally to quit the interarticular cartilage of the temporal cavity, slipping before its edge, and locking the jaw, with the mouth slightly opened. It generally happens, that this dislocation is quickly removed by natural efforts alone; but I have seen it continue for a length of time, and the motion of the jaw, and the power of closing the mouth have still returned. This state of the jaw happens from extreme relaxation. Cause. The patient finds himself suddenly incapable of entirely closing the mouth; some pain is felt, and the mouth is least closed on the side on which the pain is felt.

Reduction. Force for removing these appearances must be applied directly downwards, so as to separate the jaw from the temporal bone, and to give an opportunity for the cartilage to replace itself upon the rounded extremity of the condyloid process.

Relaxation of ligaments. In extreme degrees of relaxation, a *snapping* is felt in the maxillary articulation just before the ear, with some pain, arising from the sudden relapse of the jaw into its socket, which the relaxation of the ligament had permitted it to quit, and to advance upon the zygomatic tubercle.

Young women are generally subject to this sensation, and

the means which I have found most frequently and quickly tending to insure their recovery have been ammonia and steel as medicine; with the shower-bath, and the application of a blister before the ear, when the complaint has continued for a length of time.

DISLOCATIONS OF THE CLAVICLE.

As the clavicle is the only medium by which the arm is articulated with the bones of the chest, it might be expected that its dislocation would be extremely frequent; but this bone is so peculiarly and strongly articulated, both with the sternum and scapula, as to render its dislocation comparatively rare. Dislocations rare.

In other articulations we find a capsular ligament proceeding from the edges of the articulating surfaces and peculiar ligaments, to give strength to the junction of the bones; but in the articulation of the clavicle, like that of the lower jaw and knee, we meet with an interarticular cartilage, composing a part of the articulating apparatus. Articulation.

JUNCTION OF THE STERNAL EXTREMITY OF THE CLAVICLE WITH THE STERNUM.

The articulating surfaces, both of the sternum and clavicle, are in part rounded, and in part depressed; and both are covered by Bones.

Cartilage. an articular cartilage similar to that of the other joints. A capsular ligament proceeds from the end of the clavicle to the edge of the articulating surfaces of the sternum, and it is strengthened by short ligaments, which pass directly from one bone to the other.

Within the capsular ligament is situated the interarticular cartilage, joined at the upper part of the joint to the clavicle, and to the capsular ligament; and, below, to the edge of the articular surface of the sternum, and to the capsular ligament; it is inclined under the end of the clavicle with the capsular ligament, so that the clavicle rests upon its surface, and it is also interposed between that bone and the sternum. Of that portion of this cartilage which is inclined to the clavicle, only about one half is smooth, to allow of the motion of that bone, and this is its lower and anterior part. The residue of it adheres to the articular cartilage of the clavicle, forming a flat, rough surface; but on the side towards the sternum the interarticular cartilage forms a smooth and concave surface, which allows of its free motion on that bone. The interarticular cartilage is placed not perpendicularly, but obliquely; its upper end is inclined inwards, and its lower end outwards, towards the first rib. From the upper point of the

Interclavicular ligament. clavicle proceeds an interclavicular ligament, which adheres to the capsular ligament, and slightly to the sternum; and traversing the upper and back part of the sternum, it is fixed in the extremity of the opposite clavicle, and unites very strongly one clavicle to the other.

Clavicular costal ligament. The clavicle is also joined to the first rib by a clavicular costal, or, as it is called, rhomboid ligament, which proceeds from the

inferior edge of the sternal end of the clavicle to the cartilage of the first rib.

The motion of the clavicle, as well as that of the sternum, forwards and backwards, is performed upon the smooth surface of the interarticular cartilage, which is applied to the sternum; whilst the motion of the clavicle, upwards and downwards, is produced upon the portion of the smooth surface of the interarticular cartilage, which is applied to the clavicle; and another advantage is derived from this mode of articulation, which is, that it allows of the motion of the bone outwards and backwards to a considerable extent, without occasioning any weakness in the ligament: for in this view it may be considered that there are two ligaments, one from the clavicle to the cartilage, and one from the cartilage to the sternum, instead of one loose, long ligament from bone to bone.

Motion of the clavicle.

DISLOCATION OF THE STERNAL EXTREMITY OF THE CLAVICLE.

These are of two kinds, viz.: the dislocation *forwards*, the clavicle being then thrown upon the sternum; or *backwards*, when the end of the bone is placed behind the sternum.

Dislocation Forwards.

The circumstances by which this injury is known are, that upon looking at the upper part of the sternum a rounded projection is

seen, and when the fingers are carried upon the surface of the sternum upwards, this projection stops them. If the surgeon places himself behind the patient, puts his knees between the scapulæ, grasps the shoulders and draws them back, the projection on the sternum disappears; but directly when the shoulders advance, the projection upon the sternum is renewed. The clavicle may be readily traced with the finger into the projection on the sternum. If the shoulder be elevated the projection descends, if it be drawn downwards the dislocated extremity of the bone becomes elevated to the neck. The motions of the dislocated clavicle are painful, and the patient moves the shoulder with difficulty. The point of the injured shoulder is less distant from the central line of the sternum than usual. In a very thin person the nature of the accident can be at once ascertained, because the bone is but little covered; but in fat persons it is more difficult to detect. When the patient is at rest very little pain or tenderness is felt from the accident. It sometimes

Partial. happens that this dislocation is incomplete, the anterior portion of the capsular ligament only being torn, and the bone slightly projected; but generally all the ligaments are lacerated, and the bone, with its interarticular cartilage, is thrown forwards.

Its cause. The cause of this injury is a fall upon the point of the shoulder, when the force pushes the clavicle inwards and forwards, and projects it on the sternum; but it also frequently happens from a fall upon the elbow, at the time it is separated from the side, by which the clavicle is forced violently inwards and forwards against the anterior part of the capsular ligament.

Reduction. With respect to the means of reduction and the principle upon

which the treatment is to be regulated, there is no difficulty in practising the one, or in understanding the other. The clavicle is easily returned to its place by pulling the shoulder backwards, because then it is drawn off the sternum, and its end falls upon the cavity which naturally received it; but if pressure in this position of the shoulder be not made upon the fore part of the bone, it will be found still liable to project in some degree.

Principle.

The principle, therefore, upon which the extension is made, is to draw the scapula as far from the side as is practicable without inconvenience, and by supporting the arm, to prevent its weight from influencing the position of the bone.

Mode of extension.

The first of these objects is best effected by the use of the clavicle bandage *(see plate)*, and by the application of two pads or cushions affixed to it, which are placed in the axillæ. These pads throw the head of the os humeri from the side, and carry the scapula, and the clavicle connected with it, outwards and backwards, and thus the clavicle is drawn into its natural articular cavity. The second intention is effected by putting the arm in a sling, which, through the medium of the os humeri and scapula, supports it, and prevents the clavicle from being drawn down by the weight of the arm.

Dislocation Backwards.

Dislocation backwards.

The dislocation of the extremity of the bone backwards I have never known occur from violence, yet it might happen from excessive force, as from a blow upon the fore part of the bone, which should tear the capsular and clavicular costal ligament, and allow the bone to glide behind the sternum, occasioning

compression of the œsophagus, and rendering deglutition difficult. The trachea would, from its elasticity, elude pressure, and escape to the opposite side of the space by which this tube enters the thorax.

Cause. The only cause of this dislocation that I have known, was produced by great deformity of the spine, by which the scapula advanced, and sufficient space was not left for the clavicle, between the scapula and sternum; in consequence of which, the bone gradually glided back behind the sternum, and produced so much inconvenience by its pressure on the œsophagus, as to lead to a necessity for the removal of its sternal extremity.

This case is extremely creditable to the knowledge, skill, and dexterity of Mr. Davie, surgeon at Bungay, in Suffolk; few would have thought of the mode of relief—very few would have dared to perform the operation—and a still smaller number would have had sufficient knowledge to accomplish it.

The following particulars I in part received in conversation with Mr. Davie, who fell a victim to his great professional zeal, and in part from Mr. Henchman Crowfoot, surgeon at Beccles, who, to high professional skill, adds all the amiable qualities which can become a man. He had the kindness to go over to Dr. Camell, of Bungay, to learn from him some of the particulars, and there met with a person who gave him several others, and who knew the patient for some years after the operation.

CASE.

Case. Miss Loffly, of Metfield, Suffolk, had a great deformity, arising from a distorted spine, increased by an accident which displaced

the sternal extremity of the left clavicle, and threw it behind the sternum. The progressive distortion of the spine gradually advanced the scapula, and occasioned the sternal end of the clavicle to project inwards, behind the sternum, so as to press upon the œsophagus, and occasion extreme difficulty in deglutition. Her deformity had become excessive, and her emaciation extreme.

Mr. Davie conceived that he should be able to prevent the gradual destruction which the altered position of the clavicle threatened, by removing the sternal extremity of the bone; and the operation which he performed for this purpose was, according to all I can learn, as follows:

An incision was made of from two to three inches in extent on the sternal extremity of the clavicle, in a line with the axis of that bone; and its surrounding ligamentous connections, as far as he could then reach them, were divided with the saw of Scultetus (often called Hey's); he sawed through the end of the bone, one inch from its articular surface from the sternum, and fearful of doing unnecessary injury with the saw, he introduced a piece of well beaten sole leather under the bone whilst he divided it. When the sawing was completed he tried to detach the bone, but it still remained connected by its interclavicular ligament, and he was obliged to tear through that ligament by using the handle of the knife as an elevator, and after some time succeeded in removing the portion of bone which he had separated.

The wound healed without any untoward occurrence, and the patient was enabled to swallow, as the pressure of the clavicle upon the œsophagus was now removed.

She lived six years after the operation, and recovered considerably from her former emaciation. "Of what she ultimately died," says Mr. Crowfoot, "I have not learnt."

JUNCTION OF THE CLAVICLE WITH THE SCAPULA.

Articulation. The clavicle joins with the scapula about three quarters of an inch behind the extremity of the acromion. The end of the clavicle is slightly convex, and covered by an articular cartilage; the scapula is depressed to receive it, and this surface is also covered by an articular cartilage. Strong ligamentous fibres pass directly from the clavicle to the scapula, and under these a capsular ligament is extended from the edge of the socket of the scapula, to the extremity of the clavicle. The surface of junction is very small, the end of the clavicle not being longer than the end of the little finger of an adult; and the cavity in the scapula which receives it is very superficial, being not larger than is required to receive upon its surface the end of the clavicle. But the junction of the two bones is effected by much stronger means, through the medium of the coracoid process of the scapula, which

Ligaments. sends forth two ligaments to the clavicle. The first proceeds from the root of the coracoid process, and is fixed in a small tubercle of the clavicle on its under side, at the insertion of the subclavius muscle, and two inches from the extremity of the bone. This

Internal coraco-clavicular. ligament has been called the conoid, from its form, but may be better named the internal coraco-clavicular. The use of this

ligament is, to bind down the clavicle to the scapula, and to confine the motion of the clavicle forwards and upwards.

The second ligament of this part is called trapezoid; it proceeds from the coracoid process, and passes on the under side of the clavicle to near its scapular end, into which it is fixed; I call it the external coraco-clavicular. This ligament is the chief cause which lessens the tendency to dislocation of the scapular end of the clavicle, for when its capsular ligament is divided, the scapula cannot be forced under the clavicle without lacerating this ligament, so great is its resistance. It allows of very free motion of the scapula backwards and upwards, but confines its motions forwards. The motions of this extremity of the clavicle are performed by the subclavius muscle, although other muscles also move this bone.

External coraco-clavicular.

DISLOCATION OF THE SCAPULAR EXTREMITY OF THE CLAVICLE.

This accident is more frequent than the dislocation of the sternal extremity.

When this extremity of the bone is luxated, the signs by which the surgeon ascertains the nature of the injury are as follows:

The shoulder on that side, when compared with the opposite, appears depressed, for the clavicle is formed to give support to the scapula, and that support is lost in consequence of the accident. The point of the shoulder approaches nearer to the

Symptoms.

sternum; and if the distance of the two shoulders from that bone be measured, this inequality is directly detected; the clavicle being naturally the means of preserving the distance of the scapula from the side, to throw out the shoulders, and to render the motions of the arm extensive. But the easiest mode of detecting this accident is, to place the finger upon the spine of the scapula, and to trace this portion of bone forward to the acromion in which it ends; the finger is stopped by the projection of the clavicle, and so soon as the shoulders are drawn back, the point of the clavicle sinks into its place, but it reappears when the shoulders are let go. The point of the clavicle projects against the skin upon the superior part of the shoulder, and much pain is felt when it is pressed.

In this injury, the capsular ligament is necessarily torn through, as well as the external ligament, from the coracoid process to the clavicle, or no dislocation of the sternal extremity could occur. The internal ligament, when the dislocation is complete, must be also lacerated; but I have seen the clavicle project but slightly on the acromion in some of these accidents, denoting that the latter ligament had not given way.

It is scarcely probable, that the clavicle should be ever dislocated in any other direction than upwards. At least, I have never seen an instance of the clavicle gliding under the acromion, but I would not deny the possibility of such an accident.

Cause. This species of dislocation is caused by a fall upon the shoulders, through which the scapula is forced inwards towards the ribs, and the accident which produces it is excessively violent. It has been said, that the action of the trapezius muscle alone

could produce this effect, but that is impossible, as this muscle would not influence both the ligaments of the coracoid process, which must be torn through to produce the dislocation.

In the treatment of this accident, I adopt the following plan: Reduction. The assistant, standing behind the patient, puts his knee between the shoulders, and draws them backwards and upwards, when the clavicle sinks into its socket. A thick cushion is then placed in each axilla, for three purposes: First, to keep the scapula from the side: Secondly, to raise the scapula: Thirdly, to defend the axillæ from being hurt by the bandages: on which last account a cushion is employed on each side. Then the clavicle bandage is applied, and its straps should be sufficiently broad to press upon the clavicle, the scapula, and the upper part of the os humeri, to keep the former down, the scapula inwards and backwards (which is the chief object), and the arm backwards and elevated. To secure these objects more effectually, the arm Mode. is to be suspended in a short sling, by which it is made to support the scapula in its proper situation.

At the conclusion of my lecture upon this subject I have always given this counsel to the pupils:—"You are not to expect that the parts, after the utmost care in the treatment, will, in dislocations of either end of the clavicle, be very exactly adjusted; some projection, some slight deformity will remain; and it is necessary, from the first moment of the treatment, that this should be stated to the patient, as he may otherwise suspect that the fault has arisen from your ignorance or negligence. You may at the same time inform him, that a very good use of the limb will be recovered, although some deviation from the natural

form of the parts may remain, in a slight projection on the sternum, or some elevation of the sternal extremity of the clavicle."

DISLOCATION OF THE CLAVICLE WITH FRACTURE OF THE ACROMION.

We have a preparation of this injury in the Museum at St. Thomas's Hospital, and the following account of the case was given me by Mr. South.

Case. A man, aged sixty years, was admitted into King's Ward, St. Thomas's Hospital, Oct. 19, 1814, having fallen from a tree two or three days before. The surgeon to whom he applied told him that nothing was injured; but he himself persisted in saying his shoulder was broken, and walked up from Maidstone to the hospital. On examination, his shoulder appeared fallen as if displaced, but a little attention shewed that this was not the case. What, however, the accident was determined to be, I do not recollect, but the following treatment was adopted. Cushions were put in the axillæ, and a stellate bandage applied, with another just above the elbow to bind it to the side, and the arm was put in a sling, which seemed to keep the parts in their proper position; but the next morning the bandages were loose. Supposing that this effect was produced by restlessness, they were again applied, but continued slipping off, day after day, until a week from his admission, when a long splint, placed across the shoulders, was bound to them by rollers, and the parts resumed

their natural situation; but after a short time, they were also obliged to be removed on account of the extreme irritability of the patient. He was then ordered to lie in bed upon his back without any bandage, but the parts became again displaced. No other attempt at relief was made, and he died on December the 7th following, of some pulmonary disease, after an illness of three weeks.

On examination of his body, the clavicle was found dislocated at its scapular extremity, and projected considerably over the spine of that bone. The acromion process, just where the clavicle is united with it, was broken off.

Clavicle dislocated.

Acromion broken.

The splint across the shoulders seemed likely to succeed in keeping the parts in apposition, if the man's illness and impatience would have permitted him to continue to wear it.

STRUCTURE OF THE SHOULDER-JOINT.

Shoulder-joint.

The shoulder-joint is composed of two portions of bone; the glenoid cavity of the scapula, and the head of the os humeri.

Glenoid cavity.

The glenoid cavity is similar in form to a longitudinal section of an egg, with its larger extremity downwards and outwards, and its smaller upwards and inwards; the cavity is so superficial, that the head of the humerus rather rests upon its surface than is received into its hollow; it is, however, slightly concave, and is covered by an articular cartilage, which is somewhat extended beyond the edge of the bony cavity.

Coracoid process.

The coracoid process of the scapula is situated at the upper point of the glenoid cavity, and its basis extends from thence to the notch of the superior costa; it rises and inclines inwards and forwards, terminating in a point, which is situated under the clavicle, one third the length of that bone from its junction with the spine of the scapula, and on the inner side of the head of the os humeri, under the pectoral muscle. It covers and protects the joint on its inner side.

The glenoid cavity is united to the body of the scapula by a narrow neck, which is called the cervix scapulæ; and its narrowest part is opposite to the notch of the superior costa of the scapula. Cervix scapulæ.

The head of the humerus is divided into three portions. The first is an articular surface forming a small part of a sphere, which rests upon the glenoid cavity of the scapula, and is covered with an articular cartilage; the second is a process called the larger tubercle, formed for the insertion of three muscles; it is situated on the outer portion of the head of the bone, under the deltoid muscle; and the third is a process called the lesser tubercle, which is situated on the inner side of the head of the bone towards the axilla; and in the usual position of the arm, nearly in a line with the point of the corocoid process of the scapula. Head of the humerus.

Between these two processes is a groove, which lodges the tendon of the long-head of the biceps muscle, and is termed the bicepital groove. Bicepital groove,

Immediately below the head of the humerus is situated that portion of the bone called the cervix humeri. Cervix humeri.

The capsular ligament of this joint surrounds the head of the bone, and is attached to the whole circumference of the edge of the glenoid cavity, excepting where the tendon of the biceps muscle passes under it; and at that point it arises from a ligament which proceeds from the coracoid process to the edge of the glenoid cavity. The capsular ligament is also fixed to the two tubercles, and towards the axilla, to the neck of the humerus, just below its articular surface. This ligament is not of an uniform thickness; but at those parts where the joint is not defended from Capsular ligament.

injury by the tendinous insertions of muscles, the capsular ligament itself is thickened, and is capable of sustaining great violence; and this difference is remarkably shewn in that part of the ligament which is placed in the axilla, it being of a strong tendinous nature.

Four muscles are destined to move the os humeri, and to strengthen the capsular ligament. The first, the supra-spinatus, which arises from the fossa supra-spinata, covers the head of the bone, blends its tendon with the capsular ligament, and is inserted into the larger tubercle; the second, the infra-spinatus muscle, which proceeds from the fossa infra-spinata, adheres to the back part of the capsular ligament, and is also fixed to the greater tubercle; the third, the teres minor, which arises from the lower edge of the scapula, adheres to the back part of the capsular ligament, and is inserted into the greater tubercle, and into the cervix humeri; the fourth is the subscapularis muscle, which fills up the venter, or inner concave surface of the scapula: it passes over the inner side of the head of the bone, and is fixed to the smaller tubercle, firmly adhering to the capsular ligament as it passes over its inferior and inner surface. It is between the subscapularis muscle, and the teres minor, that the capsular ligament is found of great strength, as there are no muscles inserted into that part to protect the joint from injury.

Muscles of protection to the joint.

The deltoid muscle, the coraco-brachialis, and the teres major, which are also muscles of this joint, are not united with the capsular ligament as the other muscles, being only destined for the motion, and not particularly for the protection of the shoulder-joint.

Muscles of motion of the joint.

The tendon of the long-head of the biceps protects the upper part of the joint, where it otherwise would be weak; for this tendon is situated between that of the supra-spinatus and sub-scapularis: it arises from the upper point of the edge of the glenoid cavity of the scapula, and passes over the head of the bone into the groove between the two tubercles and the portion of the capsular ligament. Reflected towards the articular cartilage of the os humeri it adheres to the surface of this tendon, so that the synovia is prevented from escaping.

Tendon of the biceps.

The shoulder-joint has a greater extent and variety of motion than any other joint in the body; and its dislocations are, consequently, more frequent than those of all the other joints in the body collectively: those of the ancle-joint being next in frequency.

Cause of the frequent dislocation of this joint.

DISLOCATIONS OF THE OS HUMERI.

Four kinds of dislocation.

THIS bone is liable to be thrown from the glenoid cavity of the scapula in four directions; three of these luxations are complete, and one is partial only.

Downwards and inwards.

The *first* is downwards and inwards; it is usually called the dislocation into the axilla, and in this accident the bone rests upon the inner side of the inferior costa of the scapula.

Forwards.

The *second* is forwards upon the pectoral muscle, when the head of the os humeri is placed below the middle of the clavicle, and on the sternal side of the coracoid process.

Backwards.

The *third* is the dislocation backwards, when the head of the bone can be both felt and distinctly seen, forming a protuberance on the back and outer part of the inferior costa of the scapula, and situated upon its dorsum.

Partial dislocations.

The *fourth* is only partial, when the anterior portion of the capsular ligament is torn through, and the head of the bone is found resting against the coracoid process of the scapula, on its outer side.

It has been supposed that a dislocation of the os humeri upwards might occur, but it is obvious that this could only happen under fracture of the acromion. It is an accident which I have never seen. Of the dislocation upwards.

Of the dislocation in the axilla I have seen a multitude of instances; of that forwards on the inner side of the coracoid process several, although these are much less frequent than that in the axilla; of the dislocation backwards I have seen only two instances during the practice of my profession for thirty-eight years. I do not believe in any change of place after dislocation, when the muscles have once contracted (except from subsequent violence, which is very uncommon), beyond that slight change which pressure, by producing absorption, will sometimes occasion. The bone is generally at once thrown into the situation which it afterwards occupies; so that excepting from circumstances of great violence, the nature and direction of the dislocation are not subsequently changed. Dislocation in the axilla.

DISLOCATION IN THE AXILLA.

The usual signs of this dislocation are as follows: A hollow is produced below the acromion, by the displacement of the head of the humerus from the glenoid cavity, and the natural roundness of the shoulder is destroyed, because the deltoid muscle is flattened and dragged down with the depressed head of the bone. The arm is somewhat longer than the other, as the situation of the bone upon the inferior costa of the scapula is below the level of Signs of dislocation into the axilla.

the glenoid cavity. The elbow is with difficulty made to touch the patient's side, from the pain produced in this effort by pressure of the head of the bone upon the nerves of the axilla; and upon this account it usually happens, that the patient himself supports his arm at the wrist or fore arm with the other hand, to prevent its weight pressing upon these nerves. The head of the os humeri can be felt in the axilla, but only if the elbow be considerably removed from the side. I have several times seen surgeons deceived in these accidents, by thrusting the fingers into the axilla when the arm was close to the side, when they have directly said, "this is not a dislocation;" but upon raising the elbow, the head of the bone could be distinctly felt in the axilla; for that movement throws the head of the bone downwards and more into the axilla.

The motion of the shoulder is in a great degree lost, more especially in the direction upwards and outwards, for the patient can no longer raise his arm by muscular effort, and even the surgeon generally finds some difficulty in overcoming its fixed position; it is usual, therefore, as a first question in detecting dislocation, to ask the patient if he can raise his arm to his head, and if there be dislocation, the answer is invariably that he cannot. The power of rotation of the arm is also lost; but the motion of the limb forwards and backwards, as it hangs by the side, is still preserved. There is, however, great difference in respect to the motion of the limb, and this depends upon the age of the patient; in old people, the relaxed state of the muscles will not only admit of motion, but allow the surgeon to carry the arm to the upper part of the head. On moving the limb, a slight crepitus will

sometimes be felt from inflammatory effusion, and from the escape of synovia, but by the continuance of the motion this soon ceases; the crepitus, however, in these cases, is never so strong as that which a fracture produces. The central axis of the arm is changed, for the central line runs into the axilla.

In this accident, numbness of the fingers frequently occurs, from the pressure of the head of the bone upon a nerve, or the nerves of the axillary plexus.

These are the circumstances of greatest moment; but it will be seen that the accident can be detected principally by the fall of the shoulder, by the presence of the head of the bone in the axilla, and by the loss of the natural motions of the joint. But a few hours make these appearances much less decisive, from the extravasation of blood, and from the excessive swelling which sometimes ensue; but when the effused blood has become absorbed, and the inflammation has subsided, the marks of the injury become again decisive. At this period it is that surgeons of the metropolis are usually consulted; and if we detect a dislocation which has been overlooked, it is our duty, in candour, to state to the patient, that the difficulty in the detection of the nature of the accident is exceedingly diminished by the cessation of inflammation, and the absence of tumefaction.

Circumstances that render the nature of the accident difficult to ascertain.

It may be also observed, that there is great difference in the facility with which the accident is discovered in thin persons, of advanced age, and in those who are loaded with fat, or who have, by constant exertion, rendered their muscles excessively large.

Circumstances that render it easy.

Dissection of the Dislocation into the Axilla.

I have dissected two cases of recent dislocation downwards. A sailor fell from the yard-arm on the ship's deck, injured his skull, and dislocated the arm into the axilla. He was brought into St. Thomas's Hospital in a dying state, and expired immediately after he was put into his bed. On the following day I obtained permission to examine his shoulder, which I removed from the body for the purpose of obtaining a more minute examination, and the following were the appearances which I found: On removing the integuments, a quantity of extravasated blood presented itself in the cellular membrane, lying immediately under the skin, and in that which covers the axillary plexus of nerves, as well as in the interstices of the muscles, extending as far as the cervix of the humerus, below the insertion of the subscapularis muscle.

Appearances upon the dissection of a limb.

The axillary artery, and plexus of nerves, were thrown out of their course by the dislocated head of the bone, which was pushed backwards upon the subscapularis muscle. The deltoid muscle was sunken with the head of the bone. The supra and infra spinatus were stretched over the glenoid cavity and inferior costa of the scapula. The teres major and minor had undergone but little change of position; but the latter, near its insertion, was surrounded by extravasated blood. The coraco-brachialis was uninjured. In a space between the axillary plexus and coraco-brachialis, the dislocated head of the bone, covered by its smooth articular cartilage and by a thin layer of cellular membrane,

appeared. The capsular ligament was torn on the whole length of the inner side of the glenoid cavity, which would have admitted a much larger body than the head of the os humeri through the opening. The tendon of the subscapularis muscle, which covers the ligament, was also extensively torn. The opening of the ligament, by which the tendon of the long-head of the biceps passed, was rendered larger by laceration, but the tendon itself was not torn. The head of the os humeri was thrown on the inferior costa of the scapula, between it and the ribs; and the axis of its new situation was about an inch and a half below that of the glenoid cavity, from which it had been thrown.

The second case which I had an opportunity of examining was one in which the dislocation had existed five weeks, and in which very violent attempts had been made to reduce the dislocated bone, but without success. The subject of the accident was a woman fifty years of age. All the appearances were distinctly marked; the deltoid muscle being flattened, and the acromion pointed; the head of the bone could also be distinctly felt in the axilla; the skin had been abraded during the attempts at reduction, and the woman apparently died from the violence used in the extension. Upon exposing the muscles, the pectoralis major was found to have been slightly lacerated, and blood effused; the latissimus dorsi and teres major were not injured; the supra-spinatus was lacerated in several places; the infra-spinatus and teres minor were torn, but not to the same extent as the former muscle. Some of the fibres of the deltoid muscle and a few of those of the coraco brachialis had been torn; but

none of the muscles had suffered so much injury as the supra-spinatus. The biceps was not injured.

Having ascertained the injury which the muscles had sustained in the extension, and, in some degree, the resistance which they opposed to it, I proceeded to examine the joint.

The capsular ligament had given way in the axilla, between the teres minor and subscapularis muscles; the tendon of the subscapularis was torn through at its insertion into the lesser tubercle of the os humeri *(see plates)*; the head of the bone rested upon the axillary plexus of nerves and the artery. Having determined these points by dissection, I next endeavoured to reduce the bone, but finding the resistance too great to be overcome by my own efforts, I became very anxious to ascertain its origin. I therefore divided one muscle after another, cutting through the coraco-brachialis, teres major and minor, and infra spinatus muscles: yet still the opposition to my efforts remained, and with but little apparent change. I then conceived that the deltoid must be the chief cause of my failure, and by elevating the arm, I relaxed this muscle; but still could not reduce the dislocation. I next divided the deltoid muscle, and then found the supra-spinatus muscle my great opponent, until I drew the arm directly upwards, when the head of the bone glided into the glenoid cavity. The deltoid and supra-spinatus muscles, are those which most powerfully resist reduction in this accident.

It appears from these dissections, that the best direction in which the arm may be extended for reduction, is at a right angle with the body, or directly horizontally, rather than obliquely

downwards; as the deltoid, supra and infra spinati muscles, are, in this position of the limb, thrown into a relaxed state, and these muscles are, as I have explained, the principal sources of the resistance. The biceps is to be relaxed by slightly bending the elbow. The arm may be extended directly outwards, in the line between the pectoralis major on the outer side, and the latissimus dorsi and teres major on the inner; but if there be any deviation from this line, it will be better rather to advance the arm, to lessen the power of the pectoralis major.

This dissection explains the reason why the arm is sometimes easily reduced soon after the dislocation, by raising it suddenly above the horizontal line, and placing the fingers under the head of the bone, so as to raise it towards the glenoid cavity, which, as every tyro knows, will sometimes prove effectual, because, in this position, the muscles of opposition are relaxed so as to oppose no resistance to reduction.

Dissection of a Dislocation which had been long Unreduced.

Dissection of an old dislocation.

The head of the bone is found altered in its form; the surface towards the scapula being flattened, a complete capsular ligament covers the head of the os humeri. The glenoid cavity is completely filled by ligamentous matter, infused by a slow inflammatory process; in this ligamentous matter are suspended small portions of bone, which appear to be of new formation, as no portion of the scapula or humerus is broken; a new cavity is

formed for the head of the os humeri on the inferior costa of the scapula, but this is glenoid, like that from which the os humeri had escaped. *(See plate.)*

Causes of dislocation into the axilla.

The common causes of dislocation of the os humeri into the axilla are, falls upon the hand while the arm is raised above an horizontal line, by which the head of the bone is thrown downwards; also, a fall upon the elbow, when the arm is raised from the side; but the most frequent cause is, a fall directly upon the shoulder on some uneven surface, by which the head of the bone is driven downwards, whilst the muscles are but ill prepared to resist the shock.

Frequency of its recurrence.

When the arm has been once dislocated, if great care be not taken of the limb after its reduction, it is extremely liable to a recurrence of the accident. I remember, particularly, a carpenter, who used to be a frequent visitor at Guy's Hospital for several years, for the purpose of having his shoulder reduced. Slighter causes than that which originally produced it, will renew the dislocation; I have known it to recur from the act of throwing up the sash of a window. During my apprenticeship at St. Thomas's Hospital, in going through the wards early one morning, I was directed to see a man who had just dislocated the shoulder, which he had frequently done before, as he was lying in bed; and upon inquiring how it had happened, the man replied, that it occurred merely in the effort of rubbing his eyes and stretching himself, upon waking; but this disposition to the recurrence of dislocation may be prevented, by directing that the arm be kept fixed close to the side, and the shoulder rather elevated by a pad in the axilla, for three weeks after its reduction; during which time

the ruptured tendon of the subscapularis, and the capsular ligament will be united: a process which motion greatly impedes, if not wholly prevents.

Reduction of the Dislocation in the Axilla.

Various have been the means suggested for the reduction of the head of the humerus, when dislocated downwards into the axilla; but under the different circumstances attending this accident, different means must be employed; the first, and that which I usually adopt in my private practice in all recent cases, is

Means employed for reduction.

By the Heel in the Axilla:

And the best mode of its application is as follows: The patient should be placed in the recumbent posture, upon a table or a sofa, near to the edge of which he is to be brought; the surgeon then binds a wetted roller round the arm immediately above the elbow, upon which he ties a handkerchief; then, with one foot resting upon the floor, he separates the patient's elbow from his side, and places the heel of his other foot in the axilla, receiving the head of the os humeri upon it, whilst he is himself in the half sitting posture by the patient's side. He then draws the arm, by means of the handkerchief, steadily for three or four minutes, when, under common circumstances, the head of the bone is easily replaced *(see plate)*: but if more force be required, the handkerchief may be changed for a long towel, by which several persons may pull, the heel still remaining in the axilla. I

Heel in the axilla.

generally bend the fore arm nearly at right angles with the os humeri, because it relaxes the biceps, and consequently diminishes its resistance. I have, in many cases, extended from the wrist, by tying the handkerchief just above the hand, but more force is required in this than in the former mode, although it has this advantage, that the bandage is less liable to slip. In recent cases it very rarely happens that this mode of extension fails, and it is so easily applied in every situation, that I have recommended all our young men to employ it in the first instance, when called to this accident.

Second Mode.

Second mode

But in those cases in which the muscles are of very considerable strength, and the dislocation having existed for several days, the muscles have become permanently contracted, so that the limb is strongly fixed in its new situation, more force is required, and the following means should be employed. The patient must be placed upon a chair, and the scapula fixed by means of a bandage, which allows the arm to pass through it; that which we use at our hospital is a girt buckled on the top of the acromion, so as to raise the bandage high in the axilla, and thus enable it more completely to fix the scapula, which is the *principal object* to be attended to, as otherwise all efforts will be inefficient. When I first saw the mode of reduction adopted thirty-eight years ago, a round towel was used instead of this bandage, which was placed in the axilla, and crossed the chest, but it appeared to me that by this means the lower angle of the scapula alone was fixed, and that the glenoid cavity was drawn with the arm when extension was made; I directed, therefore, that the towel should be tied over

Application of the bandage.

the opposite shoulder with a handkerchief, so that it should be raised in the axilla on the injured side, and thus embrace a larger surface of the scapula; but still I found the scapula drawn from the side with the arm, and therefore had the bandage made as described *(see plate)*. A wetted roller is next to be bound around the upper arm just above the elbow, from which situation it cannot slip, and upon this a very strong worsted tape is to be fastened, in a manner to be described, when speaking of the reduction of dislocated fingers. The arm should then be raised at right angles with the body, and if there be much difficulty in the reduction, it should be elevated above the horizontal line, more completely to relax the deltoid and supra-spinatus muscles. Two persons should then draw from the bandage affixed to the arm, and two from the scapula bandage, with a steady, equal, and combined force; jerking should be entirely avoided, and every aim at quick reduction should be discountenanced: "*slowly and steadily*" should be the word of command from the surgeon; who, after the extension has been kept up for a few minutes, should place his knee in the axilla, resting his foot on the chair upon which the patient sits; he should then raise his knee by extending his foot, and placing his right hand upon the acromion, push it downwards and inwards, when the head of the bone will usually slip into its natural position. Whilst the extension is proceeding I have seen a gentle rotatory motion of the arm diminish opposition of the muscles, and the bone suddenly slip into its place.

But when a limb has remained a considerable length of time dislocated; when the muscles are so powerfully contracted that

the force of men cannot be so steadily exerted as to reduce the limb, after several attempts, the minds and bodies of the assistants becoming fatigued, and their efforts violent and unequal, then we employ the third mode of reduction,

By means of the Pullies.

Pullies. And here let it be understood that they are not adopted with a view of employing a greater force, for that might be obtained by the aid of more persons; but they are introduced to enable the surgeon to employ the force gradually and equally; to avoid jerks and unequal extension, which, in protracted cases, the efforts of men are sure to produce. If, therefore, I saw a surgeon, as soon as the pullies were fixed, draw them violently, and endeavour suddenly to reduce the limb, I should not hesitate at once to say, "that gentleman is ignorant of the principle upon which this mechanical power is employed, and has still this part of his profession to learn." For the application of the pulley, the patient sits between two staples, which are screwed into the wainscot on each side of him; the bandages are then applied, precisely as in the former mode, in which the extension is performed by men, and the force is applied in the same direction; the surgeon should first draw the pulley, as the class of people usually summoned to his assistance, being ignorant of the principle upon which it is employed, would use too great violence; he should draw gently and steadily, until the patient begins to complain of pain, and then cease, keeping up the degree of extension, and conversing with the patient to direct his mind to other objects. In two or three minutes, more force should be applied, and continued until

Application of the pulley.

pain be again complained of, when the surgeon should again cease to increase the force; and thus he should proceed for a quarter of an hour, at intervals slightly rotating the limb. He should, when he has applied all the extension he thinks right, give the string of the pulley to an assistant, desiring the existing degree of extension to be supported; then, putting his knee in the axilla, and resting his foot upon the chair, he should gently raise and push back the head of the bone towards the glenoid cavity, when the bone will pass into its socket; this takes place generally without the snap which is heard when other means are employed, yet both the surgeon and the patient are aware of some motion of the head of the bone at the time.* If the pullies be employed as above, the extension will be conducted infinitely more steadily and effectually than when performed by men. In my hospital practice I order the patient to be bled, and to be put into a warm bath at the temperature of 100° to 110°; and I give him a grain of tartarized antimony every ten minutes until he becomes faint; then I order him to be removed from the bath, to be wrapped in a blanket, and immediately placed upon the chair for extension, before his muscles have had time to recover, which expedient lessens the necessity of employing very considerable force. Mr. Henry Cline, Surgeon to St. Thomas's Hospital, son to my most excellent master, and who would have made an excellent practical surgeon if the hand of death had not prematurely deprived the

The efficacy of producing a tendency to syncope.

Constitutional means of assisting reduction.

* One of our pupils, a Mr. BARTLETT, of Ipswich, has invented a small spring, by means of which the strings are attached to the pulley, and which can suddenly detach them whilst the knee is in the axilla. This instrument may sometimes be useful.

world of his useful talents, was in the habit of directing his patients to support a weight for a length of time before the extension was began, with a view of fatiguing the muscles, and lessening their power of resistance. In apartments where it is not convenient to place the pullies in the walls, I have fixed them in the floor, on each side the patient, who must, under these circumstances, sit upon the floor. When the reduction has been effected, a small cushion should be placed in the axilla, and fixed there by a stellate bandage, to prevent the head of the bone again slipping from its situation, which the excessive relaxation of the muscles would readily permit; but the cushion should not be so large as to separate the arm far from the side. The sling is to be also worn to support the arm.

Means of preventing the head of the bone slipping from its situation immediately after the reduction.

There is still a fourth mode of reducing the dislocation into the axilla, which is applicable to recent dislocations, to delicate females, and to very old, relaxed, and emaciated persons, viz.:

By the Knee in the Axilla.

Fourth mode of reduction.

The patient is seated upon a low chair, the surgeon placing himself by him, separates the dislocated arm from the side sufficiently to admit his knee into the axilla, and resting his foot upon the side of the chair, he places one hand upon the os humeri, just above the condyles, and the other upon the acromion scapulæ; he then pulls down the arm over the knee, and in this manner reduces the dislocation. (*See plate.*) Even in persons of powerful muscles I have known this mode succeed, when the patient remained in the state of intoxication, in which he was found when the accident happened.

The Ambe has been recommended for the reduction of dislocations in the axilla, and this instrument was, in the last century, improved by the addition of a screw for the purpose of rendering its extension more gradual. It may succeed very well in recent cases, and in those persons whose muscles are not very powerful; but when a continued extension must of necessity be used to reduce the bone, as its fixed point of action is upon the ribs of the patient, it produces too much injury to the side, is too painful to be borne long, and is, therefore, an instrument which cannot be recommended for general use. The use of the Ambe.

Mr. Kirby, surgeon in Dublin, has lately advised an ingenious mode of applying force in dislocations of the shoulder: the scapula being fixed and the bandage applied to the arm, the patient sits upon a mattress which is laid upon the floor, and the assistants, to whose management the extension and counter-extension are consigned, place themselves at his sides, sitting opposite to each other, and disposing their legs so that the soles of their feet are opposed to each other, behind and before the patient. If occasion should require a greater force than the power of two men, the assistants may be increased by placing one or more at the backs of the other two, sitting close up to them with their faces turned towards the patient; the extension is now made, with the arm raised nearly to a right angle with the body, and in the direction forwards or backwards, as the circumstances of the case may require. The force should be maintained until it is perceived that the head of the bone (which can be easily felt, and should be pressed upon during the operation), has moved from its new situation; and when the head of the bone is found to change

its position, the assistants should slowly diminish their force while the surgeon directs it towards the glenoid cavity, by pressing the elbow to the side of the patient and slightly raising it.

Slight force necessary for reductions after repeated dislocation.

When a person has frequently dislocated his shoulder, a very slight effort is sufficient to restore the limb to its place; and I know a gentleman in the country who frequently has returned the dislocated head of the humerus into its situation, by walking up to a gate, reaching over as far as he could, and then holding by one of its lowest bars, the upper bar of the gate being pressed firmly into the axilla; still retaining his hold, he suffers his body to sink on the other side of the gate, and the head of the bone is thus pushed into the glenoid cavity; this mode of reduction is the same in principle as that of the heel in the axilla, which, as I have already mentioned, in three fourths of recent dislocations, is the best for effecting the reduction.

DISLOCATION FORWARDS, BEHIND THE PECTORAL MUSCLE, AND BELOW THE MIDDLE OF THE CLAVICLE.

Symptoms.

This species of dislocation is much more distinctly marked than the former. The acromion is more pointed, and the hollow below it, from the depression of the deltoid muscle, is much more considerable. The head of the os humeri can be readily and distinctly felt, and even seen, in thin persons, just below the clavicle; and when the arm is rotated from the elbow, the protuberance may be observed to be obedient to the motions of the arm.

Situation of the head of the humerus.

The coracoid process of the scapula is placed on the outer side of the head of the bone, so that the latter is situated between the scapula and the sternum, and is covered by the pectoralis major muscle. The arm is somewhat shortened, and the elbow is thrown more from the side, and further back, than in dislocation into the axilla. *(See plate.)* The axis of the limb is much altered, being thrown inward towards the middle of the clavicle.

The degree of pain in this accident.

The pain attending this accident, is slighter than when the head of the os humeri is thrown into the axilla, because the nerves of the axillary plexus are less compressed; but the motions of the joint are much more materially affected; the head of the bone becoming fixed by the coracoid process, and neck of the scapula, on the outside, and by the clavicle above, while the muscles of the scapula, as the supra and infra spinati, and teres minor, being put upon the stretch, confine all its motions inwards and backwards. If, therefore, the arm be attempted to be brought forwards, the head of the bone strikes against the clavicle; if outwards, from the side, the coracoid process stops it; but its motion backwards is confined, not by bone, but by the resistance of muscles. But the strongest diagnostic marks of this dislocation are these: the head of the bone is below the clavicle; the elbow is separated from the side, and thrown backwards; and the rotation of the arm gives motion to the head of the bone under the clavicle.

Diagnostic marks.

Dissection of the Dislocation Forwards.

The head of the os humeri is, in this accident, thrown on the inner side of the neck of the scapula, between it and the second

and third ribs. I have had no opportunity of dissecting a recent accident of this kind, but in the Museum at St. Thomas's Hospital, we have a beautiful specimen of one in a limb which had been long dislocated, and which was removed from the shoulder of a patient by my colleague, Mr. Green, and dissected by Mr. Key, who has given me the following account of the appearances: "The head of the bone was thrown on the neck and part of the venter of the scapula, near the edge of the glenoid cavity, and immediately under the notch of the superior costa; nothing intervened between the head of the humerus and scapula, the subscapularis being partly raised from its attachment to the venter. The head was situated on the inner side of the coracoid process, and immediately under the edge of the clavicle, without having the slightest connexion with the ribs; indeed, this must have been prevented, by the situation of the subscapularis and serratus magnus muscles between the thorax and humerus. The tendons of all the muscles attached to the tubercles of the humerus were perfect, and are shewn in the preparation. The tendon of the biceps was not torn; and it adhered to the capsular ligament. The glenoid cavity was completely filled up by ligamentous structure, still, however, preserving its general form and character. The tendons of the supra and infra spinatus, and teres minor muscles, adhered by means of bands to the ligamentous structure occupying the glenoid cavity; and to prevent the effects of friction between the tendons and the glenoid cavity in the motions of the arm, a sesamoid bone had been formed in the substance of the tendons. The newly formed socket reached from the edge of the glenoid cavity to about one third across the venter.

Appearances on dissection

A complete lip was formed around the new cavity, and the surface was irregularly covered with cartilage. The head of the bone had undergone considerable change of form, the cartilage being in many places absorbed. A complete new capsular ligament had been formed." *(See plate.)*

The pectoralis minor is not mentioned in this dissection, but from the natural situation of the coracoid process, into which this muscle is inserted, it must have passed over the head of the os humeri, as did the pectoralis major.

Causes of this dislocation.

The usual causes of this dislocation are, either a fall upon the elbow, or a violent blow upon the shoulder, as in the last described dislocation. If it be a blow upon the elbow which has produced the accident, it must have been inflicted at a time when the elbow was thrown behind the central line of the body; and when the shoulder received the blow, the head of the bone must have been driven forwards and inwards.

Reduction of the Dislocation Forwards.

In this, as in the former case, we can usually succeed in effecting reduction by placing the foot in the axilla, and by extending the arm in the same manner; excepting that in this dislocation, the foot is required to be brought more forward to press on the head of the bone, and the arm should be drawn obliquely downwards, and a little backwards; but in those cases in which some days have elapsed before reduction has been attempted, continued extension will be necessary, and to employ it steadily and effectually, the pullies should be used.

The same bandage is required as in the dislocation in the axilla, whether the power used be applied through the medium of pullies or directly by men. The arm should be bent to relax the biceps muscle; but the principal circumstance to be considered is, the direction in which the bone is to be drawn, and the best direction is slightly downwards; for if it be drawn horizontally, the head of the os humeri is pulled against the coracoid process of the scapula, and a difficulty created which may be avoided. The principle upon which the pulley is employed, and the manner in which the extension is supported, is the same as in the dislocation into the axilla, but the direction is different, the arm being drawn obliquely downwards and backwards. The extension must be kept up longer than in the dislocation downwards, as the resistance is greater; but as soon as the bone is felt to move from its situation, the surgeon should give the strings of the pulley to an assistant, and putting his knee or heel against the head of the bone at the fore part of the shoulder, should push it back towards the glenoid cavity; but this step is not of the smallest utility until the bone has been drawn below the level of the coracoid process; and whilst the surgeon is thus pressing the head of the bone backwards, he should pull the arm forwards from the elbow. This is the plan which I have found by far the most effectual in reducing the dislocation forwards.

DISLOCATION OF THE OS HUMERI ON THE DORSUM SCAPULÆ.

Diagnostic signs.

In this dislocation, the head of the bone is thrown upon the posterior surface of the inferior costa of the scapula. It is an accident which cannot be mistaken, as there is a protuberance formed by the bone upon the scapula, which immediately strikes the eye; and when the elbow is rotated, this protuberance rolls also. The dislocated head of the bone may be easily grasped between the fingers, and distinctly felt resting below the spine of the scapula; the motions of the arm are impaired, but not to the same extent as in either of the other states of luxation.

The unfrequent occurrence of this accident.

Two cases of this accident have occurred in Guy's Hospital in thirty-eight years; the first during my apprenticeship. It happened during the anatomical lecture at St. Thomas's Hospital. The surgery-man came to the theatre and announced that there was a dislocation of the shoulder at Guy's Hospital, when Mr. Cline went over with the students to see the accident, and met Mr. Forster, under whose care the patient was admitted. The nature of the accident was at once obvious, from the projection of the head of the bone on the dorsum scapulæ. The bandages were applied in the same manner as if the head of the humerus had been in the axilla, and the extension was made in the same direction as in that accident. During the progress of the adjustment of the apparatus, some conversation took place between Mr. Cline and Mr. Forster, as to what variation in direction there should be given to the bone, if the first attempt should not

succeed; but in less than five minutes, the bone slipped into the glenoid cavity with a loud snap.

The second case, which occurred several years after, was easily reduced by the dressers, under the same treatment.

Mr. Toulmin, of Hackney, has had the kindness to send me the following communication upon the subject of this species of dislocation:

Hackney, July 10, 1822.

My dear Sir,

Mr. Toulmin's case.

The gentleman to whom the dislocation of the head of the humerus upon the dorsum scapulæ occurred, was Mr. Collinson, who was about thirty-six years of age, six feet high, and unusually muscular. The injury was sustained in the neighbourhood of Windsor, in consequence of his horse falling with him, by which he was thrown over the animal's head. He applied to a surgeon at Windsor, but the character of the accident was not detected. He returned in a post-chaise to his own house, when Mr. Hacon and myself saw him. The shoulder had lost its natural roundness; the arm could be moved considerably, either upwards or downwards; but the motion, either in the anterior or posterior direction, was very limited. On raising the arm to a right angle with the side, the direction of the limb was obviously behind the glenoid cavity; and by placing the hand over the dorsum scapulæ, and then rotating the arm, the head of the bone was felt to obey the rotating motion.

Means employed for its reduction.

In order to reduce this dislocation, a large towel was applied to sustain the necessary force for the reduction, and to fix as much as

possible that part of the scapula unoccupied by the head of the bone. A gradual extension of the limb was made directly outwards, and then the arm being slowly moved forwards, the head of the bone was distinctly heard to snap into its socket. The extension was not continued for more than two or three minutes before the reduction was accomplished. To the best of my recollection, Mr. Collinson's arm was perfectly restored to all its functions within a month.

I am always, my dear Sir,
Very truly your's,
J. Toulmin.

I have also received the following remarks on the dislocation of the os humeri backwards, from Mr. C. M. Coley, of Bridgeworth.

May 11*th*, 1822.

My dear Sir,

The dislocation of the shoulder backwards is very rare, and I apprehend, imperfectly understood and described by surgical writers. The external appearances are a hollow and puckering of the parts just below the acromion; the arm lies close to the side; the fore-arm is turned inwards, and passes obliquely forwards across the body; a protuberance as large as an orange is seen on the dorsum scapulæ, close to the spine of that bone. This dislocation is, I suppose, produced by the action of the teres major and latissimus dorsi upon the bone, while its head is forced over the margin of the glenoid cavity.

Reduction.

This is effected by elevating the arm and rotating it outwards, so as to roll the head of the humerus towards the axilla; having brought it as much as possible to resemble a dislocation into the axilla, the operator must keep it in that situation, and, at the same time, bring down the arm in an horizontal direction, when, an extending force being applied, the bone will be readily reduced.

CASE I.

June 17th, 1820. Thomas Alding, of this town, was pulled down by a calf, which he was driving, a cord having been tied to one of the calf's legs, and held fast by the man's hand. The appearances corresponded with the above described general marks of the accident.

Means of Reduction employed.

Means of reduction.

I rotated the fore arm as much as possible outward, carrying the whole arm upwards at the same time, so that the hand was brought nearly in a line with the vertebræ, and as high as it could be extended above the head. By this expedient I succeeded in rolling the head of the humerus downwards and inwards, until it rested on the inferior costa of the scapula, and was in part to be felt in the axilla. Having thus reduced it as far as possible into the situation resembling the dislocation downwards, I brought the arm and fore arm carefully downwards and backwards into the horizontal line, keeping the head of the humerus in the same situation all the time. Extension being now made, and my hand

being placed firmly on the acromion, the bone was easily replaced. The rotatory motion produced considerable pain; and just as the head of the bone crossed the edge of the glenoid cavity, severe pain was felt, and a noise was heard. My father and Mr. Cantin were so kind as to assist me.

CASE II.

September 24th, 1820. — Jenkins, aged fourteen, was thrown against a tree by a furious horse, by which accident his shoulder was displaced backwards. The tumour produced by the head of the bone was to be seen in a line with the spine of the scapula, and in part projecting beyond it. The acromion projected very much, and the integuments below it were puckered and formed a cavity.

Reduction.

I rotated the arm in an extended direction, still outwards, and raising it as high as I could I brought the head of the displaced bone towards the axilla; then retaining the bone in this position, having carefully brought down the limb into a horizontal line, Mr. Cantin and I made an extension, and the limb was readily reduced.

C. M. Coley.

PARTIAL DISLOCATION OF THE OS HUMERI.

I believe this is not a very rare accident, and it shews itself by the following marks:

Symptoms. The head of the bone is drawn forwards against the coracoid process; there is a depression opposite the back of the shoulder-joint, and the posterior half of the glenoid cavity is perceptible, from the advance of the head of the bone; the axis of the arm is thrown inward and forwards; the inferior motions of the limb are still capable of being performed; but its elevation is prevented by the head of the humerus striking against the coracoid process; there is an evident protuberance formed by the head of the bone in its new situation, which is felt readily to roll when the arm is rotated.

CASE I.

Mr. Brown, aged fifty years, was thrown from his chaise on his shoulder, and, upon examination after the accident, the roundness of the shoulder was lost, and there was a hollow under the acromion; the head of the bone projected forwards and inwards against the coracoid process; the arm could be raised from the side if brought forwards, but with difficulty raised directly upwards. By extension of the shoulders backwards, I at last brought the head of the bone to the glenoid cavity, but it directly again slipped forwards as the extension ceased. This dislocation differs from that forwards under the pectoral muscle, in the head of the os humeri, being still on the scapular side of the coracoid process, while in the complete dislocation forwards it is thrown on its sternal side.

Dissection. The only case of dissection of this accident, which I have had an opportunity of seeing, was the following, for which I am indebted to Mr. Patey, surgeon in Dorset-street, who had the

subject brought to him for dissection, at the anatomical room, St. Thomas's Hospital.

The following is Mr. Patey's account:

CASE II.

Mr. Patey's case.

Partial dislocation of the head of the os humeri, found in a subject brought for dissection to St. Thomas's Hospital, during the latter part of the year 1819.

Appearances before dissection.

The appearances were as follow: The head of the os humeri, on the left side, was placed more forward than is natural, and the arm could be drawn no farther from the side than the half way to the horizontal position.

Dissection.

Appearances upon dissection.

The tendons of those muscles which are connected with the joint were not torn, and the capsular ligament was found attached to the coracoid process of the scapula. When this ligament was opened, it was found that the head of the os humeri was situated under the coracoid process, which formed the upper part of the new glenoid cavity; the head of the bone appeared to be thrown upon the anterior part of the neck of the scapula, which was hollowed, and formed the lower portion of the glenoid cavity. The natural rounded form of the head of the bone was much altered, it having become irregularly oviform, with its long axis, from above downwards; a small portion of the original glenoid cavity remained, but this was rendered irregular on its surface, by the deposition of cartilage; there were also many particles of cartilaginous matter upon the head of the os humeri, and upon

the hollow of the new cavity in the cervix scapulæ, which received the head of the bone. At the upper and back part of the joint there was a large piece of the cartilage which hung loosely into the cavity, being connected with the synovial membrane, at the upper part only, by two or three small membranous bands. The long head of the biceps muscle seemed to have been ruptured near to its origin at the upper part of the glenoid cavity, for at this part the tendon was very small, and had the appearance of being a new formation. *(See plate.)*

James Patey.

Cause.

This accident happens from the same causes which produce the dislocation forwards. The anterior part of the ligament is torn, and the head of the bone has an opportunity of escaping forwards to the coracoid process.

Means of reduction and of preventing the recurrence of the dislocation.

The mode for its reduction will be the same as that for the dislocation forwards, but it is necessary to draw the shoulders backwards to bring the head of the bone to the glenoid cavity; and immediately when the reduction is completed, the shoulders should be bound back by a clavicle bandage, or the bone will immediately again slip forward against the coracoid process.

Dislocation of the shoulder complicated with fracture.

Dislocations of the shoulder are sometimes complicated with fracture of the head of the os humeri; and we have a preparation in the Museum at St. Thomas's Hospital, in which the greater tubercle at the head of the bone had been broken off, and the os humeri thrown into the axilla. This complication of accident does not add to the difficulty of reduction, but, on the contrary, rather facilitates the return of the bone, as the insertion of the principal

opponent muscles, the supra and infra spinati, is removed; but it increases the difficulty of retaining the bone within the glenoid cavity after the reduction is completed.

FRACTURE OF THE NECK OF THE OS HUMERI, WITH THE DISLOCATION FORWARDS, UNDER THE PECTORAL MUSCLE.

Mr. John Blackburn fell from his horse, many years ago, at Enfield, and dislocated his shoulder forwards. Mr. Lucas, sen., Surgeon of Guy's Hospital, was sent for, who said, after he had made considerable extension, that the bone was reduced. Five weeks afterwards Mr. B. came to London, and shewed me his shoulder, when the appearances of dislocation still remaining, I advised a further extension, to which he would not consent. I had frequent opportunities of seeing him afterwards, but the shoulder exhibited the same appearances of dislocation. He had, however, the power of using the arm and hand in all directions, excepting upwards, but could not raise his arm parallel with his body; and suffered but little pain or inconvenience.

In June, 1824, he died; and as he had always promised me the dissection of his shoulder if I survived him, I removed it in the presence of Mr. Arnott, Surgeon of Greenwich Hospital, examined it with great care, and have the bones preserved. The deltoid teres major and coraco brachialis muscles did not appear to me to be altered; the supra-spinatus was lessened, as was the teres minor,

which had lost considerably of its natural colour: the infra-spinatus was stretched; the subscapularis diminished, and rounded by the projection of the head of the os humeri, and adhered to its cartilaginous surface. The capsular ligament was torn under the subscapularis muscle, but every other part was entire. The head of the os humeri had been thrown forwards on the inner side of the coracoid process, and had been united by bone to the scapula; but its cartilage remained under the tendon of the subscapularis. The neck of the os humeri was broken through, and had been covered by a granular ligamentous substance; but the parts were kept together only by the ligament of the joint, and a new and very useful joint had been formed. The outer edge of the glenoid cavity remained; the surface of the glenoid cavity was granulated and ligamentous. The greater tubercle of the os humeri was exceedingly increased, and the tendon of the biceps passed through the bone. The tubercles were separated with the body of the bone, and not with its head.

This, then, was a case of fracture of the cervix humeri within the capsular ligament, terminating in a ligamentous union.

COMPOUND DISLOCATION OF THE OS HUMERI.

Mr. Dixon's case.

An injury of excessive violence will sometimes occasion the head of the bone to be forced through the integuments in the dislocation forwards. It happened in the practice of Mr. Saumarez,

and Mr. Dixon, of Newington; and for the following detail of its circumstances I am indebted to Mr. Dixon.

CASE.

My dear Sir,

I feel pleasure in answering the queries you have put. The accident happened to Robert Price, fifty-five years of age, who, on returning in a state of intoxication from the Borough, fell down upon his shoulder. Upon examination, I found that the head of the bone having passed through the integuments in the axilla, lay exposed upon the anterior part of the chest, and situated over the pectoral muscle on the right side. The reduction of the dislocation was easy, being performed without the necessity of raising him from the state of stupor and insensibility in which he was lying, by the usual method of extension and counter-extension, taking care only to guide the bone into the glenoid cavity; he was then put to bed and an evaporating lotion applied. On the following morning considerable pain and tension had come on; he was bled, and purged freely; a large poultice was applied over the joint, and anodynes were given to lessen pain and procure sleep; leeches were frequently applied in the neighbourhood of the joint for the first ten days or fortnight, after which, a copious discharge of pus issued from the wound in the axilla. The constitution now felt the effects of so important an injury; he became irritable, restless, and lost flesh: healthy pus was discharged freely from the joint for ten or twelve weeks, when it somewhat abated. A succession of small abscesses, situated in the cellular membrane, surrounding the joint, were exceedingly

troublesome for several months, some of which formed extensive sinuses, and required to be freely dilated. The discharge of pus was kept up from the joint nearly twelve months, when it finally ceased, leaving the joint anchylosed, and the wound closed. He was quite recovered in fourteen months from the accident, at which time he called on me, and felt gratified, by shewing how freely he could make use of the fore arm, and handle his pen for all the purposes of business. He is still living in Paradise-row, Stockwell, and is employed by the parish of Lambeth as a collector of assessed taxes.

I am, my dear Sir,
Your's faithfully,
P. Dixon.

Treatment. Such a case will require an immediate reduction, by the means which I have described for the dislocation of the os humeri forwards; and, in general, the greater the violence done to the injured limb, the more easy is the reduction, from the diminution of the constitutional powers which so great a shock produces. When the bone is replaced, lint dipped in blood is to be applied to the wound, or if the wound be large, a suture should be employed, and then the lint applied; adhesive plaster should be used to support approximation, and the limb should be kept close to the side by means of a roller passed round the body, including the arm, and thus preventing the least motion of the head of the bone; by these means the suppurative inflammation may be prevented, and the cure may proceed without protracted suffering, or any danger to the patient's life.

PARTIAL DISLOCATION OF THE OS HUMERI FORWARDS.

Mr. Bachelor, of Southville, aged thirty-six, fell from a chaise on the 12th of November, and, as he supposes, pitched on his shoulder. On rising he could not move his right arm for ten minutes, when some sudden spasm gave him the power of moving it underhand. Inflammation succeeded; the shoulder became much swollen, with pain down the arm to the fingers, and particularly in the direction of the cubital nerve. On looking at the arm the same evening, he found that the os humeri appeared to be advanced.

It is two months since the injury, and the hand is now benumbed. There is much pain at the insertion of the biceps into the fore arm, so that he has been often obliged to rise twice during the night to put his hand in warm water.

The appearances are a projection of the acromion, and a hollow beneath it; the head of the os humeri rests against and under the coracoid process, and the scapular end of the clavicle is opposite to the middle of the head of the bone. The biceps muscle was relaxed and lessened; the coracoid process of the scapula was with difficulty felt above, and to the inner side of the head of the os humeri.

The principle of treatment in these cases is, to oppose the pectoralis major by a clavicle bandage, with a broad strap over the head of the os humeri, and to bring the elbow forward to keep the head of the os humeri back.

DISLOCATION OF THE OS HUMERI BACKWARDS.

A man fell from the roof of a coach, and struck the point of his left shoulder against a projecting stone. He suffered little pain from the accident, but finding himself incapable of using his arm, he came immediately to the hospital.

Upon examination, I found that the head of the humerus was thrown upon the dorsum of the scapula, where it presented a considerable prominence, behind the glenoid cavity, and immediately under the spine of the bone. The vacancy beneath the acromion was not so remarkable as in the axillary dislocation. The arm was closely applied to the side, and slightly inverted, the elbow being directed rather anteriorly. Free motion was practicable forward and backward, but the limb could not be raised or carried across the breast without great difficulty.

Reduction was easily effected in the following manner: The scapula being fixed, extension was made, by means of a cloth twisted around the elbow, for about three minutes, when finding no disposition in the head of the bone to return to the cavity, although it was already in close contact with its lower and back margin, I made a fulcrum by my right hand in the axilla, and grasping the elbow in my left, readily succeeded in lifting it into its socket.

J. S. Perry.

House Surgeon's Apartments,
St. Bartholomew's Hospital.

Mr. Perry, without solicitation, had the kindness to send me the foregoing case, for which I am much indebted to him. Our large hospitals in London should be made as conducive as possible to the public advantage, by a liberal and reciprocal communication.

FRACTURES NEAR THE SHOULDER-JOINT,

LIABLE TO BE MISTAKEN FOR DISLOCATIONS.

FRACTURE OF THE ACROMION.

Diagnostic symptoms.

THIS point of bone is sometimes broken; and in this accident, when the shoulders are compared, the roundness of the injured side is lost, and part of the attachment of the deltoid muscle being broken off, the head of the os humeri sinks towards the axilla as far as the capsular ligament will permit. On tracing the acromion from the spine of the scapula to the clavicle, just at their junction, a depression is felt, from the fall of the fractured portion. If the distance be measured from the sternal end of the clavicle to the extremity of the shoulder, it will be found lessened on the injured side. If the surgeon raises the arm from the elbow, so as to put the deltoid muscle in motion, the natural form of the shoulder is directly restored, but the deformity returns immediately when the arm is again suffered to fall.

This accident is best detected and distinguished from dislocation by raising the arm at the elbow: having restored the figure

of the part, the surgeon places his hand upon the acromion and rotates the arm, when a crepitus can be distinctly perceived at the point of the shoulder, and along the superior portion of the spine of the scapula. The patient, as soon as the accident has happened, feels as if his arm were falling off, the shoulder dropping with a great sense of weight, and there being but little power to raise the limb.

Fracture of the acromion scapulæ will unite by bone, but it generally unites by ligamentous substance, in consequence of the difficulty which exists in producing adaptation, and in preserving the limb perfectly at rest during the period required for union. In the treatment of this accident, the head of the os humeri is the splint which is employed to keep the acromion in its natural situation; and with this view the elbow is raised and the arm is fixed; thus the bone will be elevated to the inferior surface of the acromion, and if it be kept steadily in that position, it will support and keep in its place the broken process. The deltoid muscle should be also relaxed, and this is best effected by a cushion placed between the elbow and the side; for if the elbow be brought close to the side, the broken acromion is further separated. The arm should be raised as much as is possible, and the elbow be carried a little backwards, and then bound to the chest by a roller; in this position it should be kept firmly fixed for three weeks, every thing being done to prevent any motion of the bone. Very little inflammation succeeds this accident, and the disposition to ossific union is very feeble in the separated portions of bone. Treatment.

If a pad be placed in the axilla, the broken portion becomes

widely separated from the spine of the scapula, because it throws out the head of the os humeri.

FRACTURE OF THE NECK OF THE SCAPULÆ.

Symptoms. But the accident which is much more liable to be mistaken for dislocation, is the fracture through the narrow part of the cervix scapulæ, immediately opposite the notch of the superior costa; by which the glenoid cavity becomes detached from the scapula, and the head of the bone falls with it into the axilla; the shoulder in this case falls; there is a hollow below the acromion from the sinking of the deltoid muscle, and the head of the os humeri can be felt in the axilla.

CASE.

A young lady was thrown from a gig, by the fall of the horse, in the Strand; and being carried to her house, a surgeon in the neighbourhood was sent for, who told her the shoulder was dislocated; by extension all the appearances of dislocation were removed, and he bound up the arm. On the following morning he requested me to see the case, as the arm, he said, was again dislocated. On examination I found the head of the bone in the axilla, and the shoulder so fallen and flattened, as to give to the accident many of the characters of dislocation; however, by elevating the shoulder, in raising the arm at the elbow, and the

head of the bone from the axilla, it was immediately replaced; but when I gave up this support the limb instantly sunk again. I then rotated the elbow, and pressing the coracoid process of the scapula with my fingers, by grasping the top of the shoulder, directly felt a crepitus. Having satisfactorily ascertained the nature of the accident, I placed a thick cushion in the axilla, and drawing the shoulder into its natural position, secured it by the application of a clavical bandage, and in seven weeks it became united without deformity.

The degree of deformity produced by this accident depends upon the extent of laceration of a ligament which passes from the under part of the spine of the scapula to the glenoid cavity, and which is not generally described in anatomical books. If this be torn, the glenoid cavity and the head of the os humeri fall deeply into the axilla; but the displacement is much less if this remain whole.

Diagnostic marks.

The diagnostic marks of this accident are three: *first*, the facility with which the parts are replaced; *secondly*, the immediate fall of the head of the bone into the axilla, when the extension is removed; and *thirdly*, the crepitus which is felt at the extremity of the coracoid process of the scapula, when the arm is rotated. The best method of discovering the crepitus is, for the surgeon's hand to be placed over the top of the shoulder, and the point of the fore finger to be rested on the coracoid process; the arm being then rotated, the crepitus is directly perceived, because the coracoid process being attached to the glenoid cavity, and being broken off with it, although itself uninjured, the crepitus is communicated through the medium of that process.

Treatment of this accident.

The treatment of this fracture consists in attention to two principles. The first is to carry the head of the os humeri outwards; and the second, to raise the glenoid cavity and arm. The former is effected by a thick cushion placed in the axilla, which presses the head of the bone and glenoid cavity outwards, and this may be confined by the clavicle bandage; and the latter is produced by placing the arm in a short sling, and then the raised head of the os humeri supports the glenoid cavity and cervix scapulæ, and keeps it steadily in its place until union is produced. The time required for recovery from these accidents in the adult is, from ten to twelve weeks; in the very young, all the motions of the limb are restored in a shorter period, but it is a long time before the limb recovers its strength.

FRACTURE OF THE NECK OF THE OS HUMERI.

The humerus is sometimes broken just below its tubercles, through its cervix. I have seen this accident happen both in old and in young persons, but it rarely occurs in middle age. In the young it happens at the junction of the epiphysis, where the cartilage is situated; and in the old it arises from the greater softness of this part of the bone. In this fracture the head of the bone remains in its place, but the body of the humerus sinks into the axilla, where its extremity can be felt; and it draws down the deltoid muscle, so as to lessen the roundness of the shoulder. Just as I was writing this account, a child was

Age.

Symptoms.

brought into Guy's Hospital with this accident, and I made the following notes of it:

Its age was ten years. The symptoms of the injury were inability of moving the elbow from the side, or of supporting the arm, unless by the aid of the other hand, without great pain. The tension which succeeded filled up the hollow which was at first produced by the fall of the deltoid muscle. When the head of the bone was fixed, the fractured extremity of the body of the humerus could be tilted under the deltoid muscle, so as to be felt, and even shewn, by raising the arm at the elbow. Crepitus could be perceived, not by rotating the arm, but by raising the bone and pushing it outwards. The cause of the fracture was a fall upon the shoulder into a saw-pit of the depth of eight feet.

It is in old persons that this accident is most liable to be mistaken for dislocation; for in them the flexibility of the joint is much diminished by it, and the changes of position of the bone are less easily produced.

Diagnostic symptoms.

The best diagnostic marks are the following: Embrace the head of the os humeri with the fingers and fix it, then rotate the arm at the elbow, and it will be found that the head of the bone does not obey the rotatory motion, as it is separated from the body of the humerus by the fracture, which is, in this case, external to the capsular ligament. The bone in these cases unites in from three to six weeks, according to the age of the patient.

Treatment.

The treatment consists in applying a roller from the elbow to the shoulder-joint, in placing a splint on the inner and on the

outer side of the arm, and in confining these by means of a roller. A cushion is then to be placed in the axilla, to throw out the head of the bone, and the arm is to be gently supported by a sling; for if it be much raised, the bones will overlap, and the union will be deformed.

CASE.

January, 1823.

William Mills, aged seventy-two, fell down during the severe frost upon his shoulder, three days after which he was admitted into Guy's Hospital. The arm and shoulder were much swollen, there was also acute pain and discolouration of the integuments. Crepitus could not be felt; and, from the degree of swelling, it was impossible to ascertain the precise nature of the accident. Leeches and evaporating lotions were applied. The shoulder was again examined on the second day, after the swelling had somewhat subsided, and a fracture of the neck of the humerus was discovered. The pain and swelling again became greater, and gradually increased; the integuments inflamed, having the appearance of erysipelas; the skin became discoloured and gangrenous. He was feverish and irritable, then delirious, and gradually sunk on the tenth day from the accident.

Appearances found on Dissection.

The integuments and cellular membrane, on the inner part of the shoulder over the clavicle, were considerably thickened, having a sloughy appearance; and on cutting through the deltoid muscle, a large quantity of bloody matter, mixed with serum, was effused.

The capsular ligament was extensively lacerated, the humerus was fractured through the cervix, also obliquely through the head; and a small spicula of bone was separated from the cervix.

JAMES MASH,
Dresser to Mr. Forster.

STRUCTURE OF THE ELBOW-JOINT.

Bones.

This joint is composed of three bones: The lower extremity of the humerus, the upper part of the ulna, and the head of the radius. The extremity of the os humeri is expanded, and presents two lateral eminences, which are called its condyles, the internal of which is the most prominent; between these condyles the articular surface for the ulna is situated, which is in the form of a pulley, and above it, both anteriorly and posteriorly, is situated a deep cavity with a thin partition intervening. On the lower extremity of the external condyle is placed an articular surface, on which the head of the radius is received. The upper extremity of the ulna forms two processes, with an articulatory surface between them, which is adapted to the pulley-like articular surface of the os humeri: both these surfaces of the ulna and humerus are covered with cartilage. The superior and posterior process of the ulna is called the olecranon, which forms the point of the elbow, and into which the triceps muscle is inserted; the anterior and smaller process is called the coronoid, which gives insertion

to the brachialis internus. When the arm is extended, the point of the olecranon is received into the posterior cavity, between the condyles of the humerus; and when it is flexed, the coronoid process passes into the anterior hollow; so that these cavities are formed for the purpose of admitting of free extension and flexion of the arm. The head of the radius is rounded, and rests upon the broad articular surface of the humerus, upon which it bends; and on its inner side it is received into an articular cavity on the radial side of the coronoid process of the ulna, upon which the radius rolls; and thus all the motions of the fore arm are performed: immediately below its head the radius becomes smaller, and this part is called its cervix; at the distance of an inch below its head is seated a process which is called its tubercle.

Ligaments.

The ligaments which bind these bones together are the *capsular*, which is united with the condyles, and with the portion of bone above the cavities of the os humeri; it passes over the extremity of the humerus, and is united behind to the olecranon, and to the coronoid process, on the fore part of the ulna; it is also connected to the coronary ligament of the radius: this ligament posteriorly is loose and slender, but on the fore part it is of considerable strength.

Capsular.

Coronary.

The *coronary* ligament surrounds the head of this radius; it is connected above with the capsular ligament, and below with the neck of the radius, by a thin ligament of sufficient length to allow of rotation of the head of the bone; it is also attached to the fore and back part of the coronoid process of the ulna, at its lateral articulatory surface, and thus firmly unites the radius with the ulna, yet allows of the rotation of the former.

Brachio cubital.

There are four peculiar ligaments; first, the *brachio cubital*, or internal lateral ligament, which passes from the internal condyle of the os humeri into the coronoid process of the ulna.

Brachio radial.

Secondly, the *brachio radial*, or external lateral ligament, which is fixed to the external condyle of the humerus, and to the coronary ligament of the radius; these ligaments give to the joint a strong lateral support.

Oblique.

The third ligament is the *oblique*, which passes from the coronoid process of the ulna to the radius, just below its tubercle; and it is this ligament which limits the rotation of the radius.

A ligament also reaches from the inner side of the coronoid process to the olecranon; and when this latter process is broken off, it is this ligament, in some instances, which prevents its extensive separation.

Muscles.

The muscles of the joint are, first, the *brachialis internus*, which passes over the anterior part of the condyles and capsular ligament, to which it is attached; it is inserted in an oblique direction into the coronoid process, and into the body of the ulna just below it. The use of this muscle is to bend the fore arm, and give support to the elbow-joint, by strengthening the capsular ligament. The next muscle is the *triceps*, which arises by one of its heads from the inferior costa of the scapula, and by its two others from the os humeri; it descends to the capsular ligament, to the loose portion of which it adheres, and is inserted into the point of the olecranon. This muscle extends the arm, and draws up and supports the capsular ligament. Thirdly, the *anconeus*, which arises from the back part of the external condyle of the humerus, adheres to the capsular ligament, and is inserted to the

extent of an inch and a half into the body of the ulna, directly below the olecranon; the course of this muscle is oblique; and whilst it extends the arm, it supports the capsular ligament. The biceps muscle does not protect the ulna joint, but has great influence in preventing a dislocation of the radius forwards, in the extended state of the arm. It is not connected with the capsular ligament, as the other muscles are; but arising from the glenoid cavity, and coracoid process of the scapula, tendinous, it becomes fleshy in its middle, and again forms a tendon at the elbow-joint, which is fixed into the tubercle of the radius. This muscle bends the fore arm, rotates the radius outwards, that is, supines the hand, and compresses the capsular ligament opposite the head of the radius.

DISLOCATIONS OF THE ELBOW-JOINT.

THERE are five species of dislocation of this joint:
First, both bones are dislocated backwards.
Secondly, both are dislocated laterally.
Thirdly, the ulna is dislocated separately from the radius.
Fourthly, the radius alone is dislocated forwards: and
Fifthly, the radius is dislocated backwards.

DISLOCATION OF BOTH BONES BACKWARDS.

Symptoms.

This dislocation is strongly marked by the great change which is produced in the form of the joint, and by its partial loss of motion. The shape of the elbow is altered, as there is considerable projection posteriorly formed by the ulna and radius above the natural situation of the olecranon. On each side of the olecranon appears a hollow. A considerable hard swelling is

felt at the fore part of the joint, immediately behind the tendon of the biceps muscle, formed by the extremity of the humerus; the hand and fore arm are supine, and cannot be rendered entirely prone. The flexion of the joint is also in a great degree lost.

Dissection of this Dislocation.

I have had an opportunity of dissecting a compound dislocation of this joint, where the radius and ulna were thrown backwards, and it is preserved in the Museum at St. Thomas's Hospital. (*See plate.*) The coronoid process of the ulna was thrown into the posterior fossa of the os humeri, and the olecranon projected at the back part of the elbow, above its usual situation, an inch and a half; the radius was placed behind the external condyle of the os humeri, and the humerus was thrown forwards on the anterior part of the fore arm, where it formed a large projection. The capsular ligament was torn through, anteriorly, to a great extent. The coronary ligament remained entire. The biceps muscle was slightly put upon the stretch, by the radius receding; but the brachialis internus was excessively stretched by the altered position of the coronoid process of the ulna. (*See plate.*)

Dissection of the dislocation backwards.

This accident usually happens in a fall when a person puts out his hand to save himself, the arm not being perfectly extended, so that the bones are forced back behind the axis of the os humeri, by pressure of the whole weight of the body upon them.

Cause of the accident.

This dislocation is easily reduced by the following means. The

patient is made to sit down upon a chair, and the surgeon, placing his knee on the inner side of the elbow-joint, in the bend of the arm, and taking hold of the patient's wrist, bends the arm; at the same time he presses on the radius and ulna with his knee, so as to separate them from the os humeri, and thus the coronoid process is thrown from the posterior fossa of the humerus; whilst this pressure is supported by the knee, the arm is to be forcibly, but slowly bent, and the reduction is soon effected. It may be also accomplished by placing the arm around the post of a bed, and by forcibly bending it while it is thus confined. I have also reduced the limb by making the patient, whilst placed upon an elbow-chair, put his arm through the opening in its back, and then, having bent the arm, the body and limb being thus well fixed, the reduction was easily effected.

This dislocation is sometimes undiscovered at first, in consequence of the great tumefaction which immediately succeeds the injury; but this circumstance does not prevent the reduction, even at the period of several weeks after the accident: for I have known it then effected by bending the limb over the knee, even without the application of very great force.

After-treatment.

As soon as the reduction has been accomplished, the arm should be bandaged in the bent position; evaporating lotions should be applied, and the limb be supported in a sling; the fore arm should be bent at rather less than a right angle with the upper arm. A splint may be placed in the sling, for the better support of the limb.

COMPOUND DISLOCATION OF THE OS HUMERI AT THE ELBOW-JOINT.

William Dowson, aged thirteen, was admitted into the accident ward of Guy's Hospital on the 5th of November, 1822, at twenty minutes past seven o'clock in the evening, with compound dislocation of the elbow-joint, occasioned by the overturning of a cart in which he was riding, and which fell with great violence upon the elbow of the left arm.

The appearances were as follow: The condyles of the humerus were thrown inwards through the skin; the articulating surface receiving the sigmoid cavity of the ulna being completely exposed to view; the ulna was dislocated backwards, and the radius outwards; the lateral and capsular ligaments were torn asunder, with extensive laceration of the parts about the joint, but the artery and nerve remained perfectly free from injury.

By the kind assistance of Mr. Key the reduction was easily effected in the following manner: The humerus being firmly grasped above its condyles, making that part a fixed point, we gradually extended the fore arm from the position in which it was found (at right angles), and the parts returned to their relative situation; but upon slightly moving the fore arm, they became displaced as before; but the reduction was effected a second time as above described, and in the semiflexed position the arm was dressed with adhesive plaster, and a pasteboard splint put on, previously dipped in warm water, so as to give it pliability in order to adapt it to the form of the part; a roller was then applied, and

a sling was attached to the wrist and conveyed round the neck, by which means the patient was prevented from moving the arm from the posture in which it was placed. He was then laid recumbent, with the elbow resting on a pillow; and the evaporating lotion of our hospital was employed, to keep the parts constantly moist and cool. I saw him during the night, and found that he was generally composed, and had slept. Early the next morning he was free from pain, his pulse 112; he experienced much thirst during the day, without any other unpleasant symptoms, except some tension of the parts, by no means considerable. On the following morning, there being some symptoms of inflammation, accompanied with pain in the head, I drew from the right arm ten ounces of blood, which appeared to relieve him; in the evening of the same day he was restless, and complained of great thirst; small quantities of barley water were given to him, and in the evening three grains of hydrag: submur. He slept during the night, and on the following morning the pulse had risen to 121; febrile action appearing, the julepum ammon: acet: was given to him every three or four hours, and in the evening his pulse had fallen to 109; he complained of darting pains in the shoulder, and his bowels being in a constipated state, I gave him 3ss of ol: ricini, and two hours afterwards he had a copious evacuation, from which he felt easier and much relieved, and he passed a good night. On the following day I found him free from pain and much better. The next day (Sunday) he complained of slight pains in the upper arm, accompanied with a small discharge from the wound. On the following day he was better, pulse 105; and on Tuesday the discharge had increased, but on the three following days it

decreased, when I ventured to dress the wound: the granulations were extremely healthy, the parts appeared to be well adjusted, leaving only a small sinus, by which the discharge escaped. It was again dressed as at first, with the exception of the splint: the lotion was discontinued, the parts being perfectly cool, and the tension much reduced. The bowels being confined, the ol: ricini was repeated, which procured him two stools. On the following day he complained of pains in the shoulder; the discharge was again increasing; but on the four following days he proceeded well, the pulse varying from 98 to 109. On the sixth day from the first dressing I proceeded to repeat that operation; the granulations were rather prominent, but healthy; and the wound was dressed with straps of soap cerate; during the six following days the patient continued to get better; but on the seventh day from the second dressing of the wound some inflammation appeared, and the lotion was renewed; the discharge at this time was very slight. On examining the part, an abscess had formed upon the external condyle, which I relieved in a day or two after by the lancet: the quantity of matter discharged was about ʒij, but quite healthy. The next day he was much better; and from this time he continued improving until the 24th of December, on which day he was able to leave his bed, and walk about the ward. By great attention to the use of passive motion, he is now enabled to move the joint to a considerable extent.

SAMUEL WHITE,
Dresser at Guy's Hospital.

I frequently witnessed the progress of this case with the greatest pleasure. A. C.

LATERAL DISLOCATION OF THE ELBOW.

Nature of the accident.

In this case the ulna, instead of being thrown into the posterior fossa of the os humeri, has its coronoid process situated on the back part of the external condyle of the humerus. The projection of the ulna backwards is, in this case, greater than in the former dislocation, and the radius forms a protuberance behind and on the outer side of the os humeri, so as to produce a hollow above it; the rotation of the head of the radius is distinctly felt by rolling the hand. Sometimes the ulna is thrown upon the internal condyle of the os humeri, so as to produce an apparent hollow above it; the rotation of the head of the radius is distinctly felt by rolling the hand. Sometimes the ulna is thrown upon the internal condyle of the os humeri, but it still projects posteriorly, as in the external dislocation; and then the head of the radius is placed in the posterior fossa of the humerus. The external condyle of the os humeri in this case projects very much outwards. I have never had an opportunity of dissecting this injury.

Causes of the accident.

The manner in which the lateral dislocation is produced is the same as in that directly backwards, but the direction of the fall is varied; it is also caused by the wheel of a carriage passing over the arm whilst it is placed upon uneven ground. The reduction of each may be effected as in the former dislocation, by bending the arm over the knee, even without particularly attending to the direction of it inwards or outwards; for as soon as the radius and ulna are separated from the os humeri by the pressure of the knee, the muscles give them the proper direction for reduction.

But the bones may be more easily reduced in a recent injury in the following manner:

CASE.

A lady consulted me respecting a fracture of the patella, which had united by a long ligament; and I told her to be careful to wear a bandage, as she was very liable to fall and to break the other patella, which I have frequently known to happen. This was at ten o'clock in the morning; at two o'clock she came to me at Guy's Hospital, having her elbow dislocated backwards, and also laterally inwards. Finding that the tendon of the biceps, and (as I knew) the brachialis internus, were put upon the stretch, I thought I might make use of them to draw the os humeri backwards, as by the string of a pulley, and I forcibly extended the arm, when the dislocation was immediately reduced.

The plate of the dislocation backwards will explain the mode in which the reduction was effected. It will be there seen that the tendon of the brachialis internus is stretched over the condyles of the humerus, and the biceps is also stretched over that bone; so that if the fore arm be forcibly extended, these muscles force back the condyles of the humerus into their natural situation.

DISLOCATION OF THE ULNA BACKWARDS.

The ulna is sometimes thrown back upon the os humeri without being followed by the radius. The appearance of the limb is

Symptoms of this accident.

then much deformed by the contortion inwards of the fore arm and hand. The olecranon projects, and can be felt behind the os humeri. Extension of the arm is impracticable, but by a force which will reduce the dislocation, and it cannot be bent to more than a right angle. It is an accident somewhat difficult to detect; but its distinguishing marks are the projection of the ulna, and the twist of the fore arm inwards.

We have an excellent specimen of this accident in the Museum at St. Thomas's Hospital. (*See plate.*) It had existed a great length of time without reduction; the coronoid process of the ulna was thrown into the posterior fossa of the humerus; the olecranon is seen projecting behind the os humeri; the radius rests upon the external condyle, and has formed a small socket for its head, in which it was able to roll. The coronary and oblique ligaments had been torn through, and also a small part of the interosseous ligament; the lower extremity of the internal condyle of the humerus seems to have had an oblique fracture in it; but I doubt whether it had been broken, or only altered in form, on account of the unnatural position of the ulna. If it had been broken, it was re-united; the triceps was thrown backwards, and the brachialis internus muscle was stretched under the extremity of the humerus. The accident arises from a severe blow on the lower extremity of the ulna, by which it is pushed suddenly upwards and backwards.

Dissection.

Cause.

This dislocation is more easily reduced than that of both bones; and the best method is to bend the arm over the knee, and to draw the fore arm downwards; the reduction will then be easy, as not only the brachialis muscle will act in resistance, but the

Mode of reduction.

radius, resting against the external condyle, will push the os humeri backwards upon the ulna when the arm is bent.

DISLOCATION OF THE RADIUS FORWARDS.

This bone is sometimes separated from the ulna at their junction at the coronoid process, and its head is thrown into the hollow above the external condyle of the os humeri, and upon the coronoid process of the ulna. *(See plate.)*

I have seen six examples of this accident; its symptoms are as follows: The fore arm is slightly bent but cannot be brought to a right angle with the upper, nor can it be completely extended. When it is suddenly bent, the head of the radius strikes against the fore part of the os humeri, and produces so sudden a stop to its motion, as at once to convince the surgeon that one bone strikes against the other. The hand is placed in a prone position, but neither its pronation nor supination can be completely performed, although its pronation be nearly complete. If the thumb be carried into the fore and upper part of the elbow-joint, the head of the radius may be there felt; and if rotation of the hand be attempted, the bone will be perceived to roll; this last circumstance, and the sudden stop to the bending of the arm, are the best diagnostic marks of the injury. Symptoms of this accident.

In the dissection of this case, the head of the radius is found resting in the hollow above the external condyle of the os humeri; the ulna is in its natural situation. The coronary ligament of the Dissection.

radius, the oblique ligament, and the fore part of the capsular, as well as a portion of the interosseous ligament, are torn through; the laceration of the latter ligament allows the separation of the two bones. The biceps muscle is shortened; and those who have not seen an example of this injury, will do well to consult the preparation from which this plate is taken.

Cause of this accident.

The cause of this accident is a fall upon the hand when the arm is extended; the radius receiving the weight of the body, is forced up by the side of the ulna, and thrown over the condyle, and upon the coronoid process of the ulna.

Case.

The first case I saw of this accident was in a woman, who was a patient of Mr. Cline's, in St. Thomas's Hospital, whilst I was an apprentice to him. The most varied attempts, which his strong judgment could direct, were made to reduce the bone, but it could not be replaced; and the woman was discharged from the hospital with the dislocation unreduced.

The second case was in a lad to whom I was called by Mr. Balmanno, of Bishopsgate-street; and although I made attempts, by continuing and varying the extension in every direction for an hour and a quarter, I could not succeed in effecting the reduction.

The third case was that of a hair-dresser, who, having been intoxicated in the evening, came to my house on the following morning with his radius dislocated; during the time of examination the patient became faint, and at last fell upon the floor in a state of syncope; this I thought afforded me a most favourable opportunity for replacing the bone, and whilst he was still upon the floor I rested his olecranon upon my foot, so as to

prevent the ulna from receding, and then extended the fore arm, and under these favourable circumstances the radius returned to its natural situation.

The fourth case was that of a gentleman in Old Broad-street, to whom I was called by Mr. Gordon, of Oxford-court, in the City; and the manner in which we succeeded in the reduction was as follows: We placed our patient upon a sofa and bent his arm over the back of it, and then making extension from the hand without including the ulna, the os humeri being fixed by the sofa, the radius in a few minutes slipped into its place.

The fifth case was that from which was made the preparation preserved in our collection at St. Thomas's, and of which I have given a plate: that preparation was one morning lying on my chimney-piece, when a gentleman of high character at the bar called upon me; he said, "What have you here?" and when I mentioned the nature of the injury, "Well, that is very curious," said he, "for I have myself been the subject of this accident." He then exposed his arm, and shewed me a dislocation of the radius; it had happened many years before, and he told me that numerous and most violent attempts had been made to reduce it without success.

The observations here stated upon this subject I have usually given in my lectures, carefully explaining the difficulty in restoring the bone to its situation; once, on an occasion of this kind, Mr. Williams, one of the most intelligent of my pupils, said to me, "I have known the radius reduced in these accidents by extending from the hand only." From a consideration of what he said, and from an experiment on the dead body, placing the radius in the

situation in which it is thrown by this accident, I was convinced that the mode of extension mentioned by Mr. Williams was the best; as, from the connection of the hand with the radius, that bone alone is acted upon, and the ulna being excluded from the force applied, the radius sustains the whole extension. It is also right in making the extension to render the hand supine, as this position draws the head of the radius from the upper part of the coronoid process of the ulna, upon which it would otherwise be directed; and then to draw the fore arm, by pulling the hand, and by fixing the os humeri.

Mr. Tyrrel informed me that a sailor, about thirty years of age, came to St. Thomas's Hospital, as an out-patient, with a dislocation of the radius forwards, which had happened between six and seven months before. The head of the radius could be distinctly felt upon the anterior part of the humerus, especially when the arm was bent as much as the nature of the accident would allow, and when the hand was bent as much as it could be towards the fore arm. The position of the limb was half supine; and when the humerus was fixed, the hand could be rendered neither perfectly supine nor prone. On the attempt to flex the fore arm, a sudden check to its motion was produced by the head of the radius striking against the humerus. From constant use of the arm after the accident, considerable motion had been reacquired,* yet the man was anxious that an attempt should be made to reduce it, from which he was dissuaded, and he went to Guy's Hospital, where the same advice was given to him.

* For he could, although with great difficulty, touch the lips with his hand.

DISLOCATION OF THE RADIUS BACKWARDS.

This is an accident which I have never seen in the living person; but in the winter of 1821, a man was brought for dissection into the theatre of St. Thomas's Hospital, in whom was found this dislocation, which had never been reduced. The head of the radius was thrown behind the external condyle of the os humeri, and rather to the outer side of the lower extremity of that bone. Mr. Sylvester, from Gloucester, a very intelligent student, had the kindness to make me a drawing of the parts as they were dissected, and the appearances will be seen in plate xxvi. When the arm was extended, the head of the radius could be seen, as well as felt, behind the external condyle of the os humeri. On dissecting the ligaments, the coronary ligament was found to be torn through at its fore part, and the oblique also had given way. The capsular ligament was partially torn, and the head of radius would have receded much more, had it not been supported by the fascia, which extends over the muscles of the fore arm.

Appearance of this accident.

Of the causes of this accident I know nothing, never having seen it in the living subject.

As to its reduction, it will be easily effected by bending the arm; but to secure the bone from subsequent displacement, the arm must be kept steadily bent at right angles, and secured by splints and a circular bandage in that situation, until the union of the coronary ligament has been effected, which will require the lapse of three or four weeks from the accident.

Mode of reduction.

LATERAL DISLOCATION OF THE RADIUS.

Mr. Freeman, Surgeon, of Spring-gardens, brought to my house a gentleman of the name of Whaley, aged twenty-five years, whose poney having run away with him, when he was twelve years of age, he had struck his elbow against a tree whilst his arm was bent and advanced before his head. The olecranon was broken, and the radius dislocated upwards and outwards, above the external condyle; and when the arm is bent, the head of the radius passes the os humeri. He has an useful motion of the arm, but neither the flexion nor the extension is complete.

FRACTURES OF THE ELBOW-JOINT.

FRACTURES ABOVE THE CONDYLES OF THE HUMERI.

The condyles of the os humeri are sometimes obliquely broken off just above the joint, and the appearance produced is so similar to that of the dislocation of the radius and ulna backwards, that this fracture is very liable to be mistaken for that injury. The following case will best exemplify its diagnostic marks.

CASE.

William Law, aged nine years, was admitted into Guy's Hospital on the 3rd of July, 1822, with a fracture of the condyles of the os humeri above the elbow-joint, which he had sustained in being thrown from a cart, having fallen upon his elbow. At the time of his admission the arm was slightly bent, and the radius and ulna appeared to project considerably backwards; just above the projection there was a hollow in the back of the arm, so

that the appearances much resembled those of dislocation. I extended the fore arm, and the appearances of the dislocation ceased; but when the extension was discontinued, those appearances returned. At this time Mr. Key arrived, who explained the accident to be a fracture above the condyles. The arm was put in splints, which were continued to be worn until the 13th of July, when they were occasionally removed, and passive motion was employed.

D. B. Major,
Dresser, Guy's Hospital.

Diagnostic marks of the nature of this accident.

The appearances of this accident, as will be seen, are like those of dislocation of the radius and ulna backwards; and the mode of distinguishing the two injuries is, by the removal of all the marks of dislocation on extension, and by their return so soon as the extension is discontinued; in general, also, these accidents are detected by rolling the fore arm upon the humerus, when a crepitus may be felt just above the elbow-joint.

The period of life at which the accident happens most frequently.

This fracture happens at all periods of life, but much more frequently in children than in persons of more advanced age.

Treatment.

Its treatment consists in bending the arm, and drawing it forwards to effect replacement; then a roller should be applied while it is in the bent position. The best splint for it is one formed at right angles, the upper portion of which should be placed behind the upper arm, and the lower portion under the fore arm; a splint must also be placed upon the fore part of the upper arm, and both should be confined by straps; evaporating lotions should be used, and the arm kept in a bent position by a

sling. In a fortnight, if the patient be young, passive motion may be gently begun to prevent the occurrence of anchylosis; and in the adult, at the end of three weeks, a similar treatment is to be pursued. But even after the most careful and judicious means which can be adopted, there is sometimes considerable loss of motion; and when the accident has not been understood, or has been carelessly treated, the deformity and loss of motion become very considerable. *(See plate.)*

FRACTURE OF THE CONDYLES OF THE OS HUMERI.

Portsea, March 5th, 1823.

Dear Sir,

Allow me to recommend to you the bearer, Mrs. Hewett, of Southsea, who met with a severe accident on the 21st of September last, by a fall from a chaise, which occasioned a compound fracture of the left arm as follows: The external and internal condyles were fractured longitudinally; the intermediate space which receives the olecranon was quite comminuted, and three pieces of bone were extracted soon after the accident from the external wound: there was also a transverse fracture about two inches and a half above the condyles.

Evaporating lotions were applied during the two first weeks, and the case proceeded favourably. I more particularly call your attention to the wrist of the right arm, which was much injured

at the time of the accident; I recommended friction, which I am afraid has been neglected.

If time will permit, your opinion of the above case will much oblige

Your's respectfully,

THOMAS IVIMY.

This lady has, in a great degree, reacquired the flexion and extension of the left arm.

A. C.

FRACTURE OF THE INTERNAL CONDYLE OF THE OS HUMERI.

The internal condyle of the humerus is frequently broken obliquely from the other condyles and body of the bone; and the symptoms by which the accident is known are as follow:

First. The ulna appears dislocated, from it and the broken condyle, projecting behind the humerus when the arm is extended.

Secondly. The ulna resumes its natural situation in bending the arm.

Thirdly. By grasping the condyles, and bending and extending the fore arm, a crepitus is perceived at the internal condyle.

Fourthly. When the arm is extended, the lower end of the os humeri advances upon the ulna, so as to be felt upon the anterior part of the joint.

I saw a girl, a patient of Mr. Steel, of Berkhampstead, who, by

a fall upon her elbow, had fractured the olecranon, and also broken the internal condyle of the os humeri, the point of the broken bone having almost penetrated the skin: the cubital nerve had been also injured; for the little finger, and half the ring finger, were benumbed.

The cause of this accident is a fall upon the point of the elbow. It usually occurs in youth, before the epiphysis is completely ossified; although I have seen it, but less frequently, in age. It is often mistaken for dislocation.

Its treatment consists in applying a roller around the elbow-joint, to keep the bone in complete apposition; in wetting it frequently with spirits of wine and water; in bending the limb at a right angle, and supporting it in a sling; and in beginning with passive motion, in the child, at the expiration of three weeks after the accident, and at a month in the adult, to prevent the loss of motion in the joint. Treatment.

FRACTURES OF THE EXTERNAL CONDYLE OF THE OS HUMERI.

This accident is readily detected by the following symptoms: Swelling upon the external condyle, and pain upon pressure; the motions of the elbow-joint, both of extension and flexion, are performed with pain; but the principal diagnostic sign is, the crepitus produced by the rotatory motion of the hand and radius. If the portion of the fractured condyle be large, it is Diagnostic marks of this accident.

drawn a little backwards, and carries the radius with it; but if the portion be small, this circumstance does not occur. We have two excellent preparations of this accident in the Museum at St. Thomas's Hospital, and in neither case has there been any other than ligamentous union. In one preparation, in which the external condyle is split obliquely, the bone is somewhat thickened; but although this accident had obviously happened long before death, no union but that by ligament had been produced. The second preparation is a specimen of the transverse fracture of the extremity of the condyle, within the capsular ligament, in which not the least attempt at ossific union can be detected. (*See plate.*)

It is obvious, therefore, that this principle of ligamentous union extends to all detached portions within a capsular ligament; the vitality of the bone being supported merely by the ligament within the joint.

This accident usually happens in children, by falls upon the elbow; at least, in the course of my observation, a very large proportion of the cases have been in young persons: I have seen it occur in the adult, but very rarely in advanced age.

Treatment. The treatment required is the following: A roller is applied around the elbow, and above and below the joint. An angular splint is to be adapted, which should admit the elbow, extend behind the upper arm, and receive the fore arm (*see plate*), so as to support it; a roller should then be bound over the whole to keep it firmly fixed. In the child, this splint may be made of stiff paste-board, bent to the shape of the elbow; but the best mode for its application is, to dip it in hot water and apply it wet,

so that it may exactly adapt itself to the form of the limb; it thus becomes the best possible support to the injured arm. Indeed, it may be here observed, that for children this is the best mode of making every support of this kind. The splint is to be worn for three weeks, when passive motion is to be begun; it must be very gentle at first, and may be gradually increased as the pain and inconvenience attending it subside.

Result of this injury.

The result of the case depends upon the seat of the fracture: if the bone be broken very obliquely, a steady and long continued support of the part will occasion it to unite; for in these cases a considerable portion of the fracture is external to the capsular ligament; but if the whole extent of the fracture be within the ligament, it does not, so far as I have seen, unite by bone, whatever be the means employed.

FRACTURE OF THE CORONOID PROCESS OF THE ULNA.

A gentleman came to London for the opinion of different surgeons upon the following case:

CASE.

Appearances of the fracture of the coronoid process of the ulna.

This gentleman had fallen upon his hand whilst in the act of running, and on rising, he found his elbow incapable of being bent, nor could he entirely straighten it; he applied to his surgeon in the country, who, upon examination, found that the ulna

projected considerably backwards; but that so soon as he bent the arm, it resumed its natural form. He immediately confined the limb in a splint, and kept it in a sling. When I saw this gentleman in town, several months had elapsed since the accident, yet the same appearances which the surgeon described when he first saw the injury, remained; namely, the ulna projected backwards whilst the arm was extended, but it was without much difficulty drawn forwards and bent, and the deformity was then removed. It was thought, at the consultation which was held about him in London, that the coronoid process was detached from the ulna, and that thus, during extension, the ulna slipped back behind the inner condyle of the humerus.

I had been several years in the habit of mentioning this case at lecture, when a person was brought to the dissecting-room at St. Thomas's Hospital who had been the subject of the same accident, and the joint is preserved in our museum. *(See plate.)*

Dissection.

The coronoid process, which had been broken off within the joint, had united by ligament only, so as to move readily upon the ulna, and thus alter the sygmoid cavity of the ulna so much as to allow in extension, that bone to glide backwards upon the condyles of the humerus.

Treatment.

As to the treatment of this accident, I am doubtful whether any mode can completely succeed, as the coronoid process, like the head of the thigh-bone, loses its ossific nourishment, and has no other than a ligamentous support. Its life is preserved by the vessels of the reflected portions of the capsular ligament upon the end of the bone, which do not appear capable of

supporting the least attempt at ossific union; nor is any change on the surface of the bone apparent. It will be proper, however, in this accident, to keep the arm steadily in the bent position for three weeks after the injury, and thus to make the ligamentous union as short as possible, by leaving the bone perfectly at rest.

FRACTURE OF THE OLECRANON.

This process of the ulna is not unfrequently broken off, and the accident is followed by symptoms which render the injury so evident, that the nature of the case can scarcely be mistaken. Pain is felt at the back of the elbow, and a soft swelling is soon produced there, through which the surgeon's finger readily sinks into the joint; the olecranon can be felt in a detached piece, elevated sometimes to half an inch, and sometimes to two inches, above the portion of the ulna, from which it has been broken. This elevated portion of bone moves readily from side to side, but is with great difficulty drawn downwards; if the arm be bent, the separation between the ulna and the olecranon becomes much greater. The patient has scarcely any power to extend the limb, and the attempt produces very considerable pain; but he bends it with facility, and if the limb be undisturbed, it is prone to remain in the semiflexed position. For several days after the injury has been sustained, much swelling of the elbow is produced; there is an appearance of ecchymosis to a considerable extent, and an effusion of fluid ensues into the joint

Symptoms of fracture of the olecranon.

in a much larger quantity than is natural; but the extent to which these symptoms proceed, depends upon the violence which produced the accident. The rotation of the radius upon the ulna is still preserved. No crepitus is felt unless the separation of the bone be extremely slight.

Dissection of this Accident.

Appearances of the dissection of this accident.

The fracture is usually found to have happened through the centre of the olecranon; and it is most frequently in the transverse direction; but I have seen the bone broken obliquely, so that the fractured parts presented very thin edges. On that portion of the olecranon attached to the ulna there are some marks of ossific inflammation, and some very slight traces of it on the detached portion. The cancellated structure of the fractured olecranon is filled by ossific matter, and is sometimes smoothed by occasional friction. The os humeri and radius undergo no change. In the appearances of one case which I dissected, and of which I have given a plate, the olecranon is separated two inches from the ulna: the capsular ligament of the elbow-joint is torn through on each side of the olecranon; and the separated portion is united by a ligamentous band, which is stretched from one broken extremity of the bone to the other. *(See plate.)*

Mode of union.

The nature of this injury then is as follows: So soon as the extremity of the bone is broken off, it is, by the action of the triceps muscle, drawn up from half an inch to two inches from the ulna, and the extent of its separation depends upon the degree of laceration of the capsular ligament, and of that portion of the ligamentous band which proceeds from the side of the coronoid

process of the ulna to that of the olecranon. That I might perfectly understand the nature of this accident, and its means of reparation, I tried the following experiments on a dog.

Experiments.

The integuments having been drawn laterally and firmly over the end of the olecranon I made a small incision, and placed a knife upon the middle of that process, in a transverse direction; on striking it with a mallet, the bone was readily cut through; a separation directly took place by the action of the triceps muscle; adhesive matter was effused; and when I examined the limb a month afterwards, I found the bone united by a strong ligament. I broke the olecranon in the same manner in several rabbits; blood was in these experiments first thrown out, and then adhesive matter filled up the space of separation, which subsequently became ligamentous, and firmer and firmer, as the time was protracted between the experiment and the examination. As I found that ligament was formed in each of these experiments, I was anxious to learn whether the olecranon could be made to unite by bone, if a longitudinal fracture were produced with but slight obliquity, so that the broken portions might still remain in contact; and I found that under these circumstances, the osseous union readily took place. Therefore, this bone, like the extremity of the os calcis when it is broken off, is detached by the action of muscles, and ligamentous union ensues from want of adaptation; but a different cause exists where bony union fails in fractured bones within joints in the neck of the thigh-bone, in the coronoid process of the ulna, and in the extremity of the

Union in fractured olecranon depending on want of adaptation.

external condyle of the os humeri; in these injuries, the want of union proceeds from the diminished support which the fractured parts receive, the little that exists being derived through the medium of blood-vessels intended for the nourishment of ligament. The preparations made from these experiments, may be seen in the Museum, at St. Thomas's Hospital. I have also seen this bone in the living person united by an ossific process, when the fracture has happened very near to the shaft of the ulna.

The ligamentous substance, which generally forms the bond of union in these cases, is often incomplete; having an aperture, and sometimes several apertures in it, when it is of considerable length. The arm is weakened in proportion to the length of the ligament, for if this be very long, extension of the arm is rendered difficult from the necessarily diminished power of the triceps muscle.

Causes of this injury.

The causes of this injury are, first, a fall upon the elbow when the joint is bent; and secondly, fracture by the action of the triceps muscle only, when a great and sudden exertion is made during the flexed position of the arm.

Treatment of fracture of the olecranon.

The treatment of this accident is as follows; but it is to be modified according to the degree of injury. If there be much swelling and contusion, it is right to apply evaporating lotions and leeches for two or three days; and after the inflammation is reduced, a bandage should be applied; but in those cases where but little violence is done to the limb, it should be at once secured by bandage. The principle of the treatment is to preserve the power of the limb, by making the separation of the bones as slight as possible, that their ligamentous union may be shortened;

and secondly, to restore the natural motions of the joint. If the swelling and inflammation do not prevent it, the surgeon is to place the arm in a straight position, and to press down the upper portion of the fractured olecranon until he brings it in contact with the ulna; a piece of linen is then laid longitudinally on each side of the joint, a wetted roller is applied above the elbow, and another below it, the extremities of the linen are then to be doubled down over the rollers and tightly tied, so as to cause an approximation; thus the bones are brought and held together; a splint well padded is to be applied upon the fore part of the arm, to preserve it in a straight position, and is to be confined to it by a circular bandage; the whole is to be frequently wetted with spirits of wine and water.

This is the only injury of the elbow-joint which requires the straight position; those of the condyles and coronoid process demanding that the limb should be kept bent.

In a month the splint is to be removed, and passive motion is to be begun; but if it be attempted earlier, the olecranon will separate from the shaft of the bone, and the ligament become lengthened and weakened: all attempts at motion must be made with the greatest gentleness.

Fracture of the olecranon an inch from the point of the elbow into the body of the ulna, requires the same treatment as the common fracture of this portion of bone.

Miss ———, aged thirty, fell from her horse on her elbow, and broke the ulna one inch from the point of the olecranon. It was kept bent three months, and no extension could be produced by any effort of herself. I forcibly straightened the arm, and kept it so

by a wooden splint.—Bony union may in this case be readily produced.

The subjoined plate is intended to shew the band of ligamentous fibres, which, if it remains untorn, prevents the olecranon from separating far from the ulna. In general, however, by bending the arm, the fracture of the olecranon is easily discovered.

A band of ligamentous fibres crosses from the side of the coronoid process to the olecranon; and upon the radial side of the ulna, the upper portion of the coronary ligament of the radius passes from the side of the olecranon towards the neck of the radius. If the olecranon be broken off, and these ligamentous fibres be left entire, the olecranon will remain still united to the ulna by means of these ligamentous productions, which I should not have noticed, but for their influence on fractures of this bone.

a. Os humeri.
b. Radius.
c. Ulna
d. Olecranon.
e. External condyle of the os humeri.
f. Internal condyle.
g. Coronary ligament, the upper part of which ascends towards the olecranon.

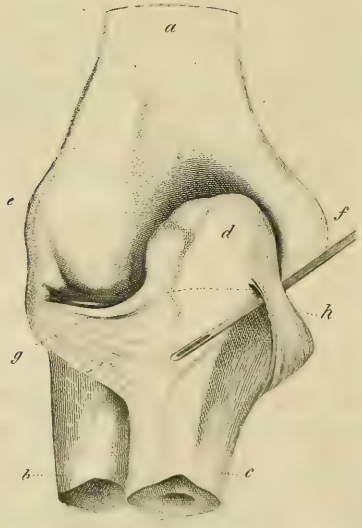

h. Ligamentous fibres from the coronoid process to the olecranon. If the olecranon be broken off at the dotted line, and the upper part of the coronary ligament, and these ligamentous fibres remain entire, the bone moves laterally, but it separates little from the ulna.

COMPOUND FRACTURE OF THE OLECRANON.

In compound fractures of this bone, the edges of the skin must be brought into exact apposition; lint embued in blood must be applied on the wound, with adhesive plaster over it, and union by adhesion must be effected if possible; but in other respects the treatment is the same as in simple fracture.

I have seen two cases of this accident, both of which have been successfully treated.

FRACTURE OF THE NECK OF THE RADIUS.

This fracture I have heard mentioned by surgeons as being of frequent occurrence, but there must be some mistake in the statement, for it is an accident which I have never seen; and if instances ever present themselves (which I do not mean to deny), they must be very rare.

Diagnostic marks of this accident.

The injury would be known by fixing the external condyle of the humerus and rolling the radius, when a crepitus would be perceived.

If such an accident should occur, the treatment which it will require will be the same as that which is demanded for fracture of the external condyle of the os humeri.

COMPOUND FRACTURES AND DISLOCATIONS OF THE ELBOW-JOINT.

These generally happen through the internal condyles of the os humeri, and the fracture takes an oblique direction into the joint.

Generally not destructive.

In the most severe accident of this kind, the constitution is generally able to support the injury, if it be judiciously treated; and the recital of the following cases will evince the happy result that may be expected, if union by adhesion be effected in the treatment.

CASE I.

I was called to Guy's Hospital, to see a brewer's servant, who had a compound fracture of the elbow-joint, caused by his dray passing over the arm, which had considerably comminuted the bones. I could pass my finger readily into the joint, and feel the brachial artery pulsating on its fore part. Considering the violence done to the part, and the constitution of the patient, who, like most of those in such employment, drank much porter and spirits, and ate but little, I at once told him, I feared there was scarcely any hope of his recovery, unless he consented to the loss of his limb; the man, however, determined not to submit to the operation, although Dr. Hulme, who accompanied me, also endeavoured to convince him of the necessity of amputation; I therefore did all in my power to save both his life and his limb. The bones were easily replaced, and the parts were carefully brought together. The limb was laid upon a splint, lightly bandaged, and placed at right angles. The wound united with-

out any untoward circumstance; and the only check that interrupted his progressive recovery, was the formation of an abscess in the shoulder, which was opened, and immediately healed. The elbow-joint was not even completely anchylosed, for he retained sufficient motion in it to allow him to resume his former occupation.

CASE II.

A gentleman, of the name of Stewart, was thrown from his chaise, and had a fracture of the condyles of the os humeri, with a projection of a portion of its inner condyle through the integuments. The edges of the wound were immediately brought together; and lint, dipped in blood, was laid over them; evaporating lotions were then applied, and the limb was kept in the bent position until the fracture was united. He had some use of the joint afterwards, but its motion was much more limited than in the former case.

CASE III.

Mr. L——, aged seventy-four, who is nearly my opposite neighbour in New-street, Spring-gardens, fell down some steps on the 20th of April, 1818, and shattered his elbow-joint. The condyles were broken, as well as the olecranon, and the internal condyle projected through the skin. Mr. Freeman, surgeon in New-street, was called to him, and he requested me to attend him. When I visited Mr. L——, I found, in addition to the above-mentioned circumstances, a considerable hæmorrhage from the wound, whilst the comminuted state of the joint allowed it to be twisted in all directions.

The treatment which we adopted was, to apply lint to the wound dipped in the blood which flowed from the arm; recourse was also had to a many tailed bandage, a pasteboard splint, and an evaporating lotion. As the parts were in a tranquil state, the dressing was not disturbed until the 15th of May. Some matter was discharged from the external wound, but the joint never manifested any signs of suppuration. The little discharge that appeared, did not exceed that which a small superficial wound would produce. The wound was some time in healing, being prevented by the pressure of the splint, on which the arm rested. So soon as it was healed, and the bones united, passive motion was begun; and although the form of the joint was irregular, yet a considerable degree of motion was preserved.

This case gratified me exceedingly, the subject of the accident being universally respected for his virtues and his talents; his constitution was feeble, his age advanced, and he could not have supported suppuration of the elbow-joint, nor is it probable that he would have survived the loss of his limb. By the simple treatment described, all the dangers which threatened him were averted; and he has, for several years, survived this very severe injury. On the contrary, if poultices be applied in these accidents, the adhesive process is prevented, and suppuration produced, which endangers life, or renders amputation necessary.

CASE IV.

A woman, between fifty and sixty years of age, was admitted into Guy's Hospital, with a wound of the elbow-joint, and fracture

of both the condyles of the os humeri. A poultice was directed to be applied, and fomentation ordered twice a day. On the day following the accident, she had a considerable degree of fever. On the third day the upper arm was exceedingly swollen, attended with an abundant sanious discharge from the wound. On the fourth day, her strength was greatly reduced, and the wound had almost ceased to discharge, but the arm was very much swollen. On the fifth day she died.

Treatment of compound fractures of the elbow-joint.

In all cases of this accident, the arm should be kept in the bent position; for as anchylosis, in a greater or lesser degree, is sure to be the consequence, it is attended with much less inconvenience in this position than in any other. If the bones be much comminuted, and the wound large, all the detached portions of bone should be removed; but in old people, when much injury is done, there is often not sufficient strength to support the adhesive process, and amputation should be recommended. The edges of the wound should be kept together by placing a piece of lint dipped in blood over them, supported by adhesive plaster, and a bandage lightly applied, wetted with spirits of wine and water.

STRUCTURE OF THE WRIST-JOINT.

Structure of the joint.

Bones.

THE radius, and the three first bones of the carpus, form the articular surfaces of the wrist-joint; the radius having an oval cavity at its lower extremity, which receives the rounded surfaces of the scaphoid, lunar, and cuneiform bones. The articular cartilage which covers this surface of the radius is, at its inner edge, extended beneath the ulna, so as to exclude that bone from the general cavity of the wrist-joint. This articular cartilage is hollow, both above and below; and at its lower surface it rests upon the os cuneiforme.

Capsular ligament.

A capsular ligament passes from the edge of the articular cavity of the radius, and from the interarticular cartilage of the ulna, to the three first bones of the carpus, surrounding a large portion of the scaphoid and lunar bones, and but a small surface of the cuneiform.

Ulna joint.

The second joint at this part, is that formed between the radius and the ulna. On the inner side of the lower extremity of the

radius is situated a hollow articulatory surface, which receives an articular surface on the outer side of the ulna, and both are covered by an articular cartilage. At the lower part of this joint is placed the interarticular cartilage of the ulna, the outer edge of which is joined to the articular cartilage of the radius, and its inner edge is united to the ulna by ligament, which sinks into a cavity formed at the lower extremity of this bone, between the styloid process of the ulna and its rounded extremity.

The capsular ligament which unites the ulna to the radius, is called the sacciform ligament; it covers the articular surfaces of the two bones, and is united below to the moveable cartilage of the ulna. This joint of the wrist is formed for the purpose of supporting the rotatory motion of the radius upon the ulna, and of strongly uniting one bone to the other. Sacciform ligament.

The wrist is strengthened on each side by peculiar ligaments; one proceeds from the styloid process of the radius, to be fixed to the outer edge of the scaphoid bone, which is the *radio-carpal ligament;* and an *ulna-carpal ligament* extends from the styloid process of the ulna, to the os cuneiforme, and os orbiculare. Radiocarpal Ulna carpal.

DISLOCATIONS OF THE WRIST-JOINT.

The dislocations of this joint are of three kinds:
First, dislocation of both bones.
Second, dislocation of the radius only.
Third, dislocation of the ulna.

Mode in which this accident happens.

The first accident, namely, the dislocation of both bones, is not of very frequent occurrence; but when it does happen, the bones are thrown either backwards or forwards, according to the direction in which the force is applied. If the person in falling puts out his hand to save himself, and falls upon the palm, a dislocation is produced, the radius and ulna are forced forwards upon the ligamentum carpi annulare, and the carpal bones are thrown backwards.

Appearance.

The appearances of this dislocation are these: a considerable swelling is produced by the radius and ulna, on the fore part of the wrist, and a similar protuberance upon the back of the wrist

by the carpus, with a depression above it; the hand is bent back, being no longer in the line with the fore arm.

In the dislocation of the radius and ulna backwards, the person falls upon the back of the hand, the radius and ulna are thrown upon the posterior part of the carpus, and the carpus itself is forced under the flexor tendons, which pass behind the ligamentum carpi annulare; but in each of these cases two swellings are produced, one by the radius and ulna, and the other by the bones of the carpus, according to the direction in which they are thrown; and these become the diagnostic signs of the accident.

Severe falls upon the palm of the hand will produce sprains of the tendons on the fore part of the wrist, and occasion a very considerable swelling of the flexor tendons, opposite the wrist-joint. This accident assumes the appearance of dislocation, but may always be distinguished from it by the existence of one swelling only, which does not appear immediately after the injury is received, but succeeds it gradually. And further, if the surgeon be called directly after the dislocation has happened, there is then a great flexibility of the hand, as well as distortion, and the extremities of the radius and ulna on one side, and of the carpal bones on the other, are easily detected. Sprains.

The reduction of this dislocation, in whatever form it may have occurred, is by no means difficult. The surgeon grasps the patient's hand with his right hand, supporting the fore arm with his left, whilst an assistant places his hands around the upper arm, just above the elbow; they then pull in different directions, and the bones become easily replaced. The reduction is in both cases the same, for the muscles draw the bones towards their Treatment.

natural position as soon as they are separated from the carpus by extension.

When the hand recovers its natural situation, a roller, wetted in spirits of wine and water, is to be lightly applied around the wrist, and the whole is to be supported by splints, placed before and behind the fore arm, reaching as far as the extremities of the metacarpal bones, for the more perfect security of the limb.

DISLOCATION OF THE RADIUS AT THE WRIST.

Diagnostic marks of this accident.

This bone is sometimes separately thrown upon the fore part of the carpus, and lodged upon the scaphoid bone and the os trapezium. The outer side of the hand is, in this case, twisted backwards, and the inner, forwards: the extremity of the radius can be felt and seen, forming a protuberance on the fore part of the wrist. The styloid process of the radius is no longer situated opposite to the os trapezium.

Cause of the accident.

This accident usually happens from a fall when the hand is bent back; and I have also known it arise from a fall upon the hand, by which the condyles of the os humeri were broken obliquely, and the radius dislocated at the wrist, being thrown upon the fore part of the scaphoid bone, where it could be distinctly felt; this case happened in the lad whom I mentioned when speaking of fractures of the os humeri; his hand was hanging backwards, and he felt great pain upon its being moved.

The extension necessary to reduce a dislocation of the radius, and the treatment which it demands, are the same which are required for the luxation of both bones; and there is no difficulty in the operation, the hand being extended whilst the fore arm is fixed.

DISLOCATION OF THE ULNA.

As this bone does not form a part of the wrist-joint, but is received into a capsular ligament of its own, and is separated from the wrist by a moveable cartilage, it is more frequently dislocated, separately, than the radius.

When this accident occurs, the sacciform ligament is torn through, and the bone generally projects backwards, without any accompanying fracture of the radius. It rises and forms a protuberance at the back of the wrist; and although it is easily pressed down into its natural position, yet so soon as the pressure is removed the deformity returns, as the lacerated ligament has no longer the power to retain it in its place. Symptoms.

The diagnostic marks of the injury are the projection of the ulna, much above the level of the os cuneiforme, and the altered position of the styloid process, which is no longer in a line with the metacarpal bone of the little finger. Diagnostic marks.

The reduction is accomplished by pressure of the bone forwards, which brings the ulna into its natural articular cavity by the side of the radius; and to retain it in this situation, splints must be placed along the fore arm, in a line with the back and palm of Mode of reduction.

the hand; the splints should be padded throughout; but upon the extremity of the ulna a compress of leather should be placed, to keep it in a line with the radius; a roller should then be applied over the splints to confine them with sufficient firmness.

COMPOUND DISLOCATION OF THE WRIST, ULNA PROJECTED, AND FRACTURE OF THE RADIUS.

June 21*st*, 1818

John Winter fell from a ladder on his hand and knee; the hand was bent back, and the ulna protruded at the inner part of the wrist. Mr. Steel, of Berkhampstead, attended; the bone was reduced, a roller was put around the wrist, and the wound healed very soon by adhesion. In seven weeks he was well, excepting that a slight swelling of the tendons remained for a few weeks longer.

SIMPLE FRACTURE OF THE RADIUS, AND DISLOCATION OF THE ULNA.

A frequent accident.

The radius is frequently broken, and the ulna at the same time dislocated; the fracture usually happens one inch above the articulation. If it occurs in a very oblique direction, so great a displacement of the radius ensues, that dislocation of the ulna forwards is also produced.

I have given a plate of this accident, from a preparation of it in the Museum at St. Thomas's Hospital. *(See plate.)* The lower end of the radius is seen in its natural situation, articulated with the carpal bones. An inch above the ligamentum annulare carpi, the broken extremity of the radius is seen projecting under the flexor tendons of the wrist, which have been removed to shew its situation; the ulna is dislocated forwards, and rests upon the os orbiculare. Dissection.

The signs of this injury are, that the hand is thrown back upon the fore arm, so as, at first sight, to exhibit the appearance of a dislocation of the hand backwards; and a projection of the ulna is felt under the tendon of the flexor carpi ulnaris muscle, just above the os orbiculare; and thirdly, the fractured extremity of the radius is easily detected, under the flexor tendons of the hand. I have seen this accident frequently, and at first did not exactly understand the nature of the injury; indeed, dissection alone, taught me its real character. Diagnostic marks of this accident.

A very powerful extension is required to bring the broken ends of the radius into apposition, and great difficulty exists in confining them when this is effected. The hand is to be extended by the surgeon, and the fore and upper arm are to be drawn back by an assistant; then a cushion is to be placed upon the inner part of the wrist, and another to the back of the hand, firmly bound down by a roller, for the purpose of keeping the ulna and broken end of the radius in situ; a splint, well padded, is then to be applied to the back part and inner side of the fore arm, which is to extend to the extremities of the metacarpal bones; these splints are to be confined by a roller, reaching from the upper part of the fore arm Mode of reduction and its difficulties.

to the wrist, and no further. The arm should be then placed in a sling: this position is to be preserved for three weeks in young persons, and for four or five in the aged, before passive motion be attempted. The recovery in these cases is slow, and six months will sometimes elapse before motion of the fingers is completely restored. *(See plate.)*

FRACTURE OF THE LOWER END OF THE RADIUS WITHOUT DISLOCATION OF THE ULNA.

Symptoms of this accident.

This fracture generally happens about an inch above the styloid process. The cure is difficult, the lower extremity of the broken bone being drawn by the action of the pronator quadratus amongst the flexor tendons, where it may be distinctly felt; in this situation it interferes very considerably with the motions of the fingers, by confining the action of the flexor profundus perforans. Mr. Cline,

Treatment.

in his lectures on this subject, used, nearly in these terms, to recommend the following treatment: "When a fracture of the radius happens just above the wrist-joint, you must be very careful in your treatment of it, to prevent the injury from leading to the permanent loss of the use of the fingers; for so soon as the injury has happened, the pronator quadratus muscle draws the fractured end of the bone obliquely across the fore arm, amidst the flexor tendons; your object, therefore, in the treatment of this accident is, to prevent the action of the pronator from producing that effect; and the mode of treatment which you are to adopt is, to

make the hand by its weight oppose the action of that muscle. For this purpose, when the bone has been placed in its right position, by drawing the hand in a line with the fore arm, apply a roller around the fore arm to the wrist; then a splint upon the fore and back part of the arm to reach to the palm and back of the hand, so as to preserve it in a half supine position; and confine the splints by means of a roller, which should reach only to the wrist. The arm is then to be placed in a sling, which is also to support it no further than to the wrist. Thus, the hand being allowed to hang between the ends of the splints, draws the end of the radius, so as to maintain a constant extension upon it, opposing the action of the pronator quadratus muscle, and keeping the broken end of the bone constantly in its place."

COMPOUND DISLOCATION OF THE ULNA, WITH FRACTURE OF THE RADIUS.

Often a very serious accident.

This is a very serious accident when the radius is much comminuted *(see plate)*, but recovery proceeds very well, when the radius is broken without being shattered. I saw a case of this injury in Hertfordshire, in which the man met with the accident by falling upon the back of his hand, and the ulna protruded an inch and a half through the integuments; the bone was immediately reduced and bandaged; the wound healed by the adhesive process, and the man recovered the perfect use of his limb.

CASE I.

Susannah Griffith, a woman from Rotherhithe Poorhouse, aged seventy-two, was admitted into Guy's Hospital, on the 10th of April, 1822. Whilst walking on the pavement, her foot had accidentally slipped, and she fell with her right hand under her, in such a manner, that the palmar surface was forcibly bent against the inner side of the fore arm; the carpal extremity of the ulna was, consequently, thrown violently outwards through the integuments, and the lower end of the radius was obliquely fractured.

The parts were reduced, and the edges of the wound brought as closely into contact as the lacerated condition of it would admit; a pledget of lint, dipped in blood, was applied to the part, and a bandage over it.

On the third day the arm became tumefied and inflamed, and poultices were applied. By the 21st of May, the fracture of the radius had united, and the patient recovered the use of the thumb and two first fingers; the whole of the articular cartilage had come off in the form of black sloughs, intermixed with spiculæ of the subjacent bone, and the granulations were so prominent, as to lead to the application of adhesive straps; the healing process, however, was greatly retarded by a frequent displacement of the extremity of the ulna, owing to the constitutional irritability of the patient, and to the œdematous state of the arm, which did not allow the bandages to be applied with the tightness requisite for its due confinement.

On the 18th of June, the wound was nearly healed; but still

a small portion of the end of the ulna will exfoliate, and she applies the lotion acidi nitrici, to hasten its exfoliation.

PEPLOE CARTWRIGHT,

August 19*th*, 1822. *Dresser, Guy's Hospital.*

CASE II.

A man was admitted into St. Thomas's Hospital, under the care of Mr. Chandler. I now forget in what manner the accident had happened, but the ulna projected through the integuments at the back of the carpus; and a compound fracture of the radius, with great comminution of the bone, was produced. The ulna was at first replaced, but immediately resumed its dislocated position on the back of the wrist, although it did not again protrude through the skin. The hand and fore arm were placed in a poultice, and were ordered to be fomented twice a day. A copious suppuration ensued, attended with violent constitutional irritation; and Mr. Chandler, in order to save the patient's life, after a lapse of five weeks, amputated the limb.

On dissection, I found the ulna dislocated backwards, and its extremity just drawn within the opening of the integuments, through which it had protruded. The radius was broken into several pieces, some of which being loose, were necessarily a great source of irritation; the tendons and muscles were some of them lacerated, as the extensor carpi radialis longior, and the extensors of the thumb. Dissection.

In a similar case it would be proper, when loose pieces of bone can be felt at the extremity of the radius, that the wound should be enlarged for their removal; and instead of fomentations and Treatment.

poultices, a quantity of lint, dipped in the patient's blood, should be applied round the wrist, lightly bound with a roller. The arm should be supported upon a splint, so as to be kept perfectly free from motion; evaporating lotions should be applied; and the limb should not be disturbed, unless the patient has symptoms of a suppurative process, when a small opening should be made in the bandage to allow of the escape of pus, but still the bandages should be suffered to remain. The patient should be bled from the arm if the inflammation and constitutional irritation be considerable, and under these circumstances, leeches should be occasionally applied. The bowels should be kept gently open, but all active purging avoided.

DISLOCATIONS OF THE CARPAL-BONES.

THE eight bones of the carpus are joined to each other by short ligaments, which pass from bone to bone, allowing but a very slight degree of motion of one bone upon another; but, beside this mode of articulation, there is a transverse joint between the first and second row of carpal bones, forming a complete ball and socket. The ball is produced by the rounded extremities of the os magnum, and os cuneiforme: the cup, by the scaphoid, lunar, and cuneiform bones. A ligament passes from one row of bones to the other, including this articulation. Carpal joint.

The dislocation of a carpal-bone is but of rare occurrence; the following is an example of it:

CASE.

Mary Nichols, aged sixty, slipped down, and, trying to save herself, fell upon the back of her hand and fractured the radius obliquely outwards, through the lower articulating surface. The fractured portion, with the os scaphoides, was thrown backwards

upon the carpus. The wrist was slightly bent, and there was an evident projection at the back of the carpus. The fingers could be completely extended, but only semiflexed. A crepitus might be distinctly felt, either by moving the hand, or the styloid process of the radius backwards or forwards. By slight extension, and steady pressure upon the displaced part, the fracture was easily reduced. There was much extravasation and pain; six leeches were applied, afterwards evaporating lotions, and two long splints; and as soon as the swelling had in some measure subsided, strips of soap plaster. At the end of six weeks the fracture was firmly united, but the motions of the wrist are still imperfect, and she cannot grasp any thing.

F. R. Elkington,

August 13*th*, 1822. *Dresser, Guy's Hospital.*

Ganglia are sometimes mistaken for this accident; but in such cases a smart blow with a book will disperse the swelling, and dispel the cloud of doubt which enveloped the mind of the surgeon.

Relaxation of the carpal-joint.

The os magnum and the cunneiform bone, from relaxation of their ligaments, are sometimes thrown somewhat out of their natural situation, so that when the hand is bent, they form protuberances at the back of the wrist. This state is productive of so great a degree of weakness, as to render the hand useless unless the wrist be supported. I was consulted by a young lady, a patient of Mr. Cumming, of Chelsea, who had such a projection of the os magnum, that she was, in consequence, obliged to give up her music and other accomplishments, on account of the attendant

weakness; for when she wished to use her hand, she was compelled to wear two short splints, which were adjusted to the wrist, and bound upon the back and fore part of the hand, and fore arm. Another lady, who had a weakened state of limb, arising from a similar cause, wore for the purpose of giving it strength, a strong bracelet of steel chain, clasped very tightly around the wrist. But the supports generally directed to be worn in these cases are straps of adhesive plaster, and a bandage over the wrist to confine and strengthen it. The affusion of cold water upon the hand from a considerable height is also employed, and the part is afterwards rubbed with a coarse towel, to give vigour to the circulation, and strength to the joints.

COMPOUND DISLOCATION OF THE CARPAL-BONES.

These accidents are of frequent occurrence, and they are generally caused by guns bursting in the hand; portions of the instrument being forced through the carpus, and between the metacarpal-bones.

In these cases a carpal-bone may be removed by dissection, and the patient may recover; not only saving his hand, but, in a considerable degree, preserving its motions; of which the following is a good example: Recovery.

CASE.

Richard Mitchell, aged twenty-two, was admitted into Guy's Hospital, under Mr. Forster, on the 17th of October, 1822, for an

extensive wound in the wrist-joint, inflicted by what is called a wool-comber's devil. On examination it was found that the wound extended through two thirds of the circumference of the joint, and was attended with a great deal of contusion; the scaphoid bone projected at the back part, being attached only on the side towards the joint; in consequence of this, the joints into which it enters were laid open; the extensor tendons of the thumb, and of the middle and fore fingers, were torn through; the radial artery was also torn, but did not afford any considerable hæmorrhage. The scaphoid bone was removed with a scalpel; the edges of the wound were brought together by sutures, and lint dipped in blood was applied to it and confined by adhesive straps; the fore arm and hand were laid on a splint, so as to keep the joint perfectly at rest; the patient was bled to twelve ounces, and an evaporating lotion ordered. In two or three days the dressings were removed, in consequence of the pain, when a good deal of surrounding inflammation was found, and in one spot a slough; the sutures were removed, and a poultice ordered; two or three days after this, abscesses formed along the thecæ of the tendons which were opened. The slough quickly separated, and the inflammation subsided, as the suppurative process became established. In two or three weeks, the wound was so well filled, as to allow the application of adhesive straps, under which treatment it gradually healed. The only constitutional symptoms which occurred during the progress of the case were those of common irritative fever, which were relieved by the exhibition of antimony, with opium and the liq. ammon. acet. with the tinct. opii. and the use of mild cathartics; and a pulmonic affection, which threatened phthisis,

was relieved by the use of leeches and diaphoretics, which, however, considerably retarded his recovery.

Whilst his wound was in the progress of healing, passive motion was early and regularly resorted to; and after it had healed, friction, with the soap liniment; but he had only a limited power of moving his fingers when he left the hospital.

The only intelligence I can now gain of him is, that he has lately gone to work, under the hope that the constant habit of grasping bodies (which indeed I strenuously recommended to him previously), will restore the motion of his fingers.

CHARLES FAGG,
Dresser to Mr. Forster,
Guy's Hospital.

Aug. 12*th*, 1822.

When only one or two of the carpal-bones are displaced by guns bursting in the hand, they may be dissected away; but if more considerable injury be done, amputation will be necessary.

DISLOCATIONS OF THE METACARPAL-BONES.

THESE bones are so firmly articulated with the bones of the carpus, that I have never seen them dislocated but by the bursting of guns, or by the passage of heavy laden carriages over the hand; and in each of these cases there is generally so much injury produced as to render amputation necessary. In the former of these accidents, a bone, and sometimes two, are capable of being removed; and if it be necessary to amputate the middle and ring finger, the fore and little finger may be so nicely brought together, and secured in such exact adhesion, as to produce little deformity.

Amputation often necessary.

CASE I.

I was called by Mr. Hood, surgeon at Vauxhall, to a Mr. Waddle, of Bow-lane, Cheapside, who, whilst shooting, had his gun burst, and his hand lacerated by a portion of the barrel passing through its centre; the metacarpal-bones of the middle and ring fingers were fractured, and also much comminuted by

the violence of the injury, but the integuments were only lacerated, and not completely removed. I dissected out the two fingers, with the metacarpal-bones which supported them, and brought the edges of the skin together by suture, approximating the fore and little finger, and applying a roller, so as to bind them together; the parts united perfectly, and the maimed hand was afterwards extremely useful to him; the case, indeed, is highly worthy inspection.

CASE II.

A boy of twelve years of age was brought into Guy's Hospital, who, by the bursting of a gun, had his thumb and all the fingers, excepting the fore finger, blown to pieces; the whole hand was exceedingly shattered, and the metacarpal-bones were separated from the carpus. Upon examination of the hand, I found that the tendon of the fore finger was uninjured, so that its use remained perfect; and as the integument could be still saved, so as to cover its metacarpal-bone, I dissected out the trapezium (the thumb had been entirely carried away by the concussion), and the metacarpal-bones of all the fingers, excepting that of the fore finger, which was afterwards of the greatest use to him. I kept him for some time at the hospital to shew to the students the restorative powers of nature, and the utility of this finger, saved out of the wreck of his hand; he used it as a hook with the greatest facility.

FRACTURE OF THE HEAD OF THE METACARPAL-BONE.

Fracture.

The extremity of the metacarpal-bone towards the fingers, which is called its head, is sometimes broken off, and it gives the appearance of dislocation of the finger, as the head of the bone sinks towards the palm of the hand. In the treatment of this case, a large ball is to be placed in the hand, grasped by it, and bound over it by a roller; and thus the depressed extremity of the bone is raised to its natural situation.

DISLOCATIONS OF THE FINGERS AND TOES.

Structure.

The phalanges of the fingers and of the toes are united by capsular ligaments to the metacarpal and metatarsal-bones, and to each other; and their union is further strengthened by lateral ligaments, proceeding from the side of one phalanx to the other. Posteriorly, they are defended by the tendon of the extensor muscle of the fingers; and anteriorly, by the thecæ and flexor tendons. Dislocation of the phalanges, therefore, is but rare; but when this accident does occur, it more frequently happens between the first and second phalanges, than between the second and third.

In plate xxviii. this dislocation will be seen; the second phalanx being thrown forwards towards the thecæ, and the first, backwards. I could not learn if the ligaments had been torn, as the dislocation had existed for a length of time, and the ligament, if it had ever been lacerated, was then united: the extensor tendon was very much stretched over the end of the first phalanx.

Diagnostic marks of this accident.

This accident may be readily distinguished by the projection of the first phalanx backwards, while the head of the second may be, although less distinctly, felt under the thecæ.

Reduction.

The reduction may be effected by making extension with a slight inclination forwards to relax the flexor muscles. If the bone has not been dislocated many hours, it is easily reduced; but if neglected at first, this can only be accomplished by a long continued extension very steadily applied. I have seen too much mischief arise from injury to the tendons and ligaments of these joints, ever to recommend the division of them (which some have advised) to facilitate reduction, when extension will not succeed. The observations which I have made respecting the dislocation of the fingers, also apply to the toes; of which, however, the dislocations are more difficult to reduce, from their greater shortness, and the less pliability of the joints.

DISLOCATION FROM CONTRACTION OF THE TENDON.

Contraction of tendon.

A toe or finger is sometimes gradually thrown out of its natural direction, by a contraction of the flexor tendon and thecæ; and the first and second phalanges are, consequently, drawn up and projected against the shoe, so as to prevent the patient from being able to take his usual exercise.

I have frequently seen young ladies subject to this inconvenience in the toe, and attribute it to the tightness of their

shoes: it appears an extremely harsh measure on the part of the surgeon to amputate a toe under such circumstances, yet it is sometimes absolutely necessary, as the contraction deprives the person of exercise, and of many of the enjoyments of life. In the first person whom I saw with this state of the toe I refused to amputate, fearful of tetanus being produced by the operation; but the lady went to another surgeon, who complied with her request, and she did very well. In consequence of the perfect recovery of this lady, and the comfort which she derived from the loss of the annoyance, I was induced, at the request of Mr. Toulmin, of Hackney, to remove from Miss T——, a patient of his, one of her toes, which was constantly irritated by the pressure of her shoe in walking, and prevented her from taking the exercise necessary to the preservation of her health; she did very well, perfectly recovering the use of her foot.

Amputation required.

The fingers are sometimes contracted in a similar manner by a chronic inflammation of the thecæ, and aponeurosis of the palm of the hand, from excessive action of the hand, in the use of the hammer, the oar, ploughing, &c. &c. When the thecæ are contracted, nothing should be attempted for the patient's relief, as no operation or other means will succeed; but when the aponeurosis is the cause of the contraction, and the contracted band is narrow, it may be with advantage divided by a pointed bistoury, introduced through a very small wound in the integument. The finger is then extended, and a splint is applied to preserve it in the straight position.

Division of aponeurosis.

Last September twelvemonth, my nephew, Mr. Bransby Cooper, who was transacting my business during my absence from town,

performed this operation for a Lincolnshire farmer, who, by this circumstance, had been prevented following his avocations; and he perfectly recovered the use of his foot.

DISLOCATION OF THE THUMB.

These accidents are very difficult to reduce, on account of the numerous strong muscles which are inserted into the part.

Structure. The thumb consists of three bones: its metacarpal-bone, and two phalanges. The metacarpal-bone of the thumb is articulated with the os trapezium by means of a double pulley; that of the trapezium directing the thumb towards the palm of the hand, and that of the metacarpal-bone directing it laterally. The metacarpal-bone is connected with the trapezium by a capsular ligament, and a very strong ligament joins the first phalanx to the palmar part of the trapezium, at its lower extremity. The metacarpal-bone forms a rounded projecting articulatory surface, upon which the hollow of the first phalanx rests, both being surrounded by a capsular ligament, and strengthened by two strong lateral ligaments. There are eight muscles inserted into the thumb; two into the metacarpal-bone, as the extensor and flexor ossis metacarpi; two into the first phalanx, the flexor brevis pollicis, and the extensor primi internodii; the abductor and adductor pollicis are also inserted into the first phalanx, through the medium of the sesamoid bones; the extensor secundi internodii and flexor longus pollicis are inserted into the second

phalanx. These muscles necessarily offer great resistance to the reduction of dislocations, and therefore those of the thumb are amongst the most difficult to reduce, if any considerable time be allowed to elapse after the accident has occurred, before the attempt at reduction be made.

DISLOCATION OF THE METACARPAL-BONE FROM THE OS TRAPEZIUM.

Symptoms.

In the cases which I have seen of this accident, the metacarpal-bone has been thrown inwards, between the trapezium, and the root of the metacarpal-bone supporting the fore finger; it forms a protuberance towards the palm of the hand; the thumb is bent backwards, and cannot be brought towards the little finger. Considerable pain, with swelling, is produced by this accident.

Mode adopted for reduction.

For the facility of reduction, as the flexor muscles are much stronger than the extensors, it is best to incline the thumb towards the palm of the hand during extension, and thus the flexors become relaxed, and their resistance diminished. The extension must be steadily, and for a considerable time, supported, as no sudden violence will effect the reduction. If the bone cannot be reduced by simple extension, it is best to leave the case to the degree of recovery which nature will in time produce, rather than divide the muscles, or run any risk of injuring the nerves and blood-vessels.

This bone is sometimes dislocated by the bursting of a gun,

Compound luxation.

which produces compound luxation; it can in these cases, usually, be with ease returned to its natural situation; the integuments being brought and confined over it by suture, a poultice is applied; and under common circumstances, where the degree of bruise has not been very considerable, a cure is perfected. Sometimes, however, the metacarpal-bone becomes so much detached from the trapezium, and the muscles are so severely torn, that it is necessary to remove the thumb, in which case it is best to saw off the articular surface of the trapezium. Such a case happened lately to a servant of Mr. Grover, of Hemel Hempstead: the metacarpal bone of the thumb was dislocated, and the muscles were so much lacerated, that it became necessary to remove the thumb at the os trapezium; but the articular surface of the trapezium projected so far that the integuments could not be brought over it, I therefore directed this surface to be sawn off, through the os trapezium; and a poultice being applied, the man recovered by the granulating process.

Dear Sir, *Brentford, April 6th*, 1820.

I some time since promised to send you an account of a compound dislocation of the thumb, which came under my care during the last year, but really I have been in such a whirl of engagements, that I have not until this evening had leisure to look at my notes of the case.

CASE.

Master Arthur Trimmer, aged thirteen years, on the 2nd of

February, 1819, whilst a wild-fire was gradually consuming, was in the act of adding, from a copper flask, dry powder, of which it contained about half a pound, when explosion took place, and the flask bursting in his hand, caused severe laceration of the palm, and a compound dislocation of the thumb. The whole mass of muscle connecting the thumb with the hand was completely torn through; and observing the thumb lying upon the carpus, dislocated from its articulation with the trapezium, I was about to have removed it with a scalpel, when I saw the tendon of the flexor longus pollicis glisten in its sheath, uninjured, as well as the tendon of the extensor longus; I therefore put the parts in something like a natural position, and took ten minutes to reflect upon the best mode of proceeding. The hæmorrhage was great at the moment, but the wound being contused and lacerated, it ceased on slight pressure.

Considering the thumb of the right hand to be a very important organ, I resolved, if possible, that it should be preserved, assuring the friends of the young gentleman, who were under great apprehension lest tetanus should ensue, that the probability of trismus supervening, would not be increased by the attempt to save the thumb.

That intelligent surgeon, Mr. Brodie, having been also sent for at the time of the accident, arrived in about three hours, when being of opinion with myself that there was a chance that the limb might be saved, I brought the parts together with three ligatures, two towards the palm, and one on the posterior part of the hand, put on adhesive straps, allowing sufficient room for extension, and to the hand and fore arm applied an evaporating lotion. Gave

him at bed-time a pill containing three grains of calomel and one of opium, and in the morning a cathartic mixture.

February 3rd. Had a restless night, but the part not very painful.

February 4th. His pulse running 120 and hard, I took away about eight ounces of blood, and ordered him the effervescing mixture, paying attention to the state of the bowels. Continued the antiphlogistic plan.

February 7th. Removed the dressings and ligatures, and had the pleasure to find that considerable adhesion had taken place; that no tetanic symptoms made their appearance, and that every day he suffered less from constitutional irritation.

February 9th. Again removed the dressings, wound looking healthy, and suppuration not considerable; I therefore continued to dress with adhesive plaster, small quantities of lint, and over that a bandage about an inch wide and two yards long, by means of which sufficiently equable pressure could be made to promote the inosculation of granulating surfaces, as well as to produce a tolerably even external state of the parts during the advance of the adhesive process.

From this time it was dressed every second day, and on the sixteenth I began to give it passive motion, at first by simply bending the first phalanx of the thumb, so as to break down any adhesions that might have taken place between the tendons and their thecæ. By the twenty-third I gave trifling motion to the second phalanx, and towards the end of the month the wound was healed. Through the month of March I gradually increased the motion, and on the 1st of April, my little patient left Brentford on

a visit to the Isle of Wight, with injunctions to give daily motion to the joint; and I am happy to add, he now makes use of it in writing as well as ever, and finds the thumb perfectly useful for all the ordinary purposes of life.

I am, dear Sir,
Most truly your's,
GEORGE COOPER.

DISLOCATION OF THE FIRST PHALANX.

This accident may be either simple or compound. I shall first describe the simple dislocation. In this accident the first phalanx is thrown back upon the metacarpal-bone, and the lower extremity of the latter projects very much inward towards the palm of the hand, and the extremity of the phalanx projects backwards. The motion of that joint is lost, but that of the thumb, through the medium of the metacarpal-bone and trapezium, remains free; so that, as an opponent to the fingers, its power of action continues; but with respect to flexion and extension, which are performed between the metacarpal-bone and the first phalanx, they are destroyed by the dislocation.

Diagnostic marks of simple dislocation of the first phalanx.

The extension is to be made by bending the thumb towards the palm of the hand, to relax the flexor muscles as much as possible; and the following is the mode of applying the extending force, which may be considered as the general mode to be adopted in dislocations of the toes, thumb, and fingers. The hand is to be

Mode of reduction.

first steeped in warm water for a considerable time, to relax the parts as much as is possible; then a piece of thin wetted leather, wash-leather for instance, is to be put around the first phalanx, and as closely adapted to the thumb as possible; a portion of tape about two yards in length is then to be applied upon the surface of the leather, in the knot which is called by sailors the *clove hitch (see plate)*, for this becomes tighter as the extension proceeds. An assistant places his middle and fore finger between the thumb and fore finger of the patient, and makes the counter extension, whilst the surgeon, assisted by others, draws the first phalanx from the metacarpal-bone, directing it a little inward towards the palm of the hand.

The extension should be supported for a considerable length of time, and if success does not attend the surgeon's efforts, it is right to adopt the following plan: The leather and sailors' knot are to be applied as before directed, and a strong worsted tape is to be carried between the metacarpal-bone of the thumb and the fore finger; the arm is then to be bent around a bed-post, and the worsted tape fixed to it; a pulley is then to be hooked to the tape which surrounds the first phalanx, and extension is to be made: this mode is almost sure to succeed. If, however, under the steadiest, best directed, and most persevering attention, the bone be not reduced, a disappointment which will sometimes happen in dislocations which have been neglected, then the surgeon's efforts must cease; no operation for the division of parts should be made, as the patient will have a very useful thumb after a time, even without reduction.

In compound dislocations of the first phalanx of the thumb, if

there be much difficulty in its reduction, and the wound be large, it is best to saw off the extremity of the bone, rather than to bruise the parts by long continued extension: they are to be healed by adhesion; and if passive motion be begun early, a joint will soon be formed, and a very useful member remain. In this case lint, dipped in blood, is to be applied to the wound; a roller must be bound round, and the part kept cool by evaporating lotions for several days, until the wound be healed. Treatment of compound dislocation of the thumb.

I very recently saw the following case of *compound dislocation* of this bone.

CASE.

A gentleman came to my house, whose first phalanx had been thrown upon the back of the metacarpal-bone of the thumb by the bursting of a gun. The flexor muscles, and the abductor, were much lacerated just below the os trapezium; the extensors were not injured. I applied the tape to the first phalanx, and extending, easily reduced it; I then brought the edges of the integuments together by suture, and directed a poultice to be applied, on account of the great contusion of the parts; and the recovery was very complete.

DISLOCATION OF THE SECOND PHALANX.

If this be a simple dislocation the best mode of reducing it is, that the surgeon should grasp the back of the first phalanx with his fingers, apply his thumb upon the fore part of the dislocated Simple.

phalanx, and then bend it upon the first as much as he possibly can.

Compound. In compound dislocations of this joint (of which I have given a plate), it is best to saw off the extremity of the second phalanx, taking care not to injure the tendon which is torn through; for when the bone is removed, the ends of the tendon may be readily approximated, and adapted to each other. The extremity of the tendon should be smoothed by a knife, and the part be then bound up in lint, dipped in blood, confined by a roller; and it should be kept quiet for a fortnight or three weeks, when passive motion may be begun.

DISLOCATION OF THE RIBS.

Authors describe different species of dislocations of the ribs; their heads are said to be thrown from their articulation with the vertebræ forwards upon the spine; if this accident ever does occur, it is certainly extremely rare, and must be very difficult of detection.

Heads of ribs.

A person, by falling on his back upon some pointed body, may, however, receive a blow upon his ribs, by which they may be driven from their articulations.

Symptoms.

Such an injury would produce the usual symptoms of fracture of these bones; their motions would be painful, and respiration necessarily difficult.

Treatment.

The treatment which would be required, would also be the same as that which is pursued in fracture of the ribs, viz., the abstraction of blood, and the application of a circular bandage; the former to prevent inflammation of the pleura and lungs; the latter to lessen the motion of the ribs. Any attempt made to effect their reduction would be entirely fruitless.

Cartilages.

The cartilages connecting the ribs with the sternum frequently appear to have been dislocated from the extremities of the ribs, and sometimes from the sternum. Mothers have several times brought their children to me, saying, "My child has sometime since had a fall, and see how the form of its breast is altered." The sixth, seventh, and eighth cartilages of the ribs are most frequently the subjects of this alteration of form; and when the ribs are carefully examined, it is found that their natural arch is diminished, their sides flattened, and, consequently, the extremities of the ribs, with their cartilages, thrust forward; the appearance which is thus produced is the result of constitutional weakness, and not of the accident to which it is attributed.

The termination of the cartilages at the sternum sometimes projects from a similar cause, giving rise to the same false impression upon the minds of the parents, that the circumstance must have arisen from accident, and not from disease. Sometimes, however, but very rarely, a cartilage is torn from the extremity of the rib, and projects over its surface; when this happens, a similar treatment is required as in fracture of the ribs. The patient is to be directed to make a deep inspiration, and then the projecting cartilage is to be pressed into its natural situation; a long piece of wetted paste-board should be placed in the course of three of the ribs and their cartilages, the injured rib being in the centre; this dries upon the chest, takes the exact form of the parts, prevents motion, and affords the same support as a splint upon a fractured limb. A flannel roller is to be applied over this splint, and a system of depletion pursued, to prevent inflammation of the thoracic viscera.

Cartilage forcibly separated.

Treatment.

INJURIES OF THE SPINE.

It has been generally stated by surgeons that dislocations of the spinal column frequently occur; but if luxation of the spine ever does happen, it is extremely rare; as in the numerous instances which I have seen of violence done to the spine, I have never witnessed a separation of one vertebra from another through the intervertebral substance, without fracture of the articular processes; or, if those processes remain unbroken, without a fracture through the bodies of the vertebræ. Still I would not be understood to deny the possibility of dislocation of the cervical vertebræ, as their articulatory processes are placed more obliquely than those of the other vertebræ. I must, however, observe, that from the vicinity of our hospitals to the river, sailors are often brought into them with injuries of the spine, by falls from the yard-arm to the deck; and as there is almost always an opportunity of inspection in these cases, a dislocation must be extremely rare, since I have never met with a single instance of it, those injuries having all proved to be fractures with displacement.

Dislocations very rare.

I am well aware that respectable surgeons have described dislocations as occurring in the cervical vertebræ, but I wish to state my own experience, with no further reference to that of others.

The following short account of the structure of the spine, is given merely to revive the ideas which may have faded from the memory.

Structure. The spinal column is composed of twenty-four vertebræ, which are divided into three classes, namely: the *cervical*, *dorsal*, and the *lumbar;* they are very strongly connected by four articular processes, and are firmly joined by an elastic substance, which proceeds from the broad surface of the body of one vertebra to that of the other. The spinous processes of many of the vertebræ, and particularly those nearest to the centre of the column, are locked together, one being admitted into a depression of the other.

Bones.

Intervertebral substance. The bodies of the vertebræ are united by a ligamento cartilaginous substance, extremely elastic, and composed of concentric lamellæ, connected by oblique fibres, which decussate each other, but in the centre become mucous, so as to form a pivot, which supports the central line of the vertebræ; whilst the elasticity and compressibility of the outer edge of this uniting medium, allows the vertebræ to move upon this centre in all directions. The column is also further connected by an *anterior spinal* ligament, which proceeds from the second vertebra of the neck to the sacrum, and is united to all the bodies of the vertebræ excepting the first. There is also a *posterior spinal* ligament, situated within the canal of the spinal column, and proceeding from the second vertebra; but it is also intermixed with the perpendicular

Anterior spinal ligament.

Posterior spinal.

ligament; and descending to the sacrum, it sends out lateral processes to the superior and inferior edges of the bodies of the vertebræ. *Intervertebral* ligaments also pass in a crucial direction from vertebra to vertebra. The articular processes are united by *capsular* ligaments, and the transverse processes have ligaments passing from the one to the other. Between the arches of the roots of the spinous processes is placed an elastic ligament, called the *ligamentum subflavum*, which allows of considerable separation of the spinous processes; and, by its elasticity, approximates them, rendering muscular support for the erect position of the body less necessary. The vertebræ of the neck are united at their spinous processes by an elastic ligamentous substance, which is termed the *ligamentum nuchæ*.

Intervertebral.

Capsular.

Ligamentum subflavum.

Ligamentum nuchæ.

The head is connected to the spinal column by *capsular ligaments*, enclosing the condyles of the os occipitis and the articular processes of the atlas, or the first vertebra.

Capsular.

A circular ligament proceeds from the foramen magnum to the edge of the aperture of the first vertebra.

Circular.

A perpendicular ligament passes from the anterior part of the foramen magnum to the dentiform process of the second vertebra.

Perpendicular.

Lateral ligaments proceed from the edge of the foramen magnum and first vertebra on each side, and are united to the dentiform process of the second vertebra: these ligaments limit the lateral motions of the head.

Lateral.

The first vertebra of the neck is united to the second by means of a *transverse ligament*, which is also fixed to the first vertebra on each side, and passes behind the dentiform process of the second vertebra.

Transverse.

The spinal column, from the two important purposes which it serves, namely, that of supporting the head and all that part of the body situated above the pelvis, and also from its containing and protecting the spinal marrow, upon which the volition and sensation of the extremities depend, is, by the number of its bones, the strength of its joints, and its connection with the bones of the chest, most carefully protected from external injury.

Effects of injuries.

The effects which are produced by violence done to the spinal chord, are very similar to those which are produced by injuries to the brain; for example:

Concussion.

Extravasation.

Fracture.

Fracture with depression.

Suppuration and ulceration.

CONCUSSION OF THE SPINAL MARROW.

Concussion.

When a person receives a very severe blow upon the spine, or, from any great force, has it very suddenly bent, a paralysis of the parts beneath will frequently succeed, in a degree proportionable to the violence of the injury; but, after such an effect, the person, in general, gradually recovers the motion and sensation of the parts.

CASE.

Case.

A man was admitted into Guy's Hospital under the care of

Dr. Curry, who had received a severe blow from a piece of wood, which, falling upon his loins, knocked him down; and as he came to the hospital on the regular day of admission, and not immediately after he had received the injury, he was placed amongst the physicians' patients. His lower extremities were in a great degree deprived of motion, and their sensibility was much diminished. When resting upon his back in bed he could slightly draw up his legs, but could not bend them to a right angle with the thigh; and a considerable time elapsed before he could make the muscles of the lower extremities obey the effort of his will. As there was still the appearance of severe contusion, and much deep seated tenderness in the situation of the blow upon the loins, Dr. Curry ordered blood to be repeatedly drawn away by cupping, and the bowels to be acted upon by calomel; and when the pain and tenderness, in consequence of the contusion, had been removed, a blister was applied to the loins, and a discharge supported for three weeks by the application of the unguentum sabinæ. The liniment ammoniæ was ordered to be daily rubbed upon the lower extremities. In six weeks the motion and sensation of his legs had almost entirely returned, and he was then directed to be submitted to the influence of electricity. By this treatment, in ten weeks, he completely recovered.

I lately attended a gentleman, who, by a fall from his gig, had received a severe blow upon his loins, and who had, at first, great difficulty in discharging both his urine and fæces, but he was relieved by fomentation and cupping.

EXTRAVASATION IN THE SPINAL CANAL.

Extravasation.

A very severe blow upon the vertebræ will sometimes produce extravasation upon the spinal chord, but more frequently upon the sheath in which it is contained. Of late years it has been our custom, in examining dead bodies, to saw off the spinous processes of the vertebræ, the more accurately to examine the spinal marrow; and under such circumstances, in cases of severe injury, blood has been several times found on the outer side of the spinal sheath; and, in one instance, it occurred upon the spinal marrow, just above the cauda equina.

Spinal marrow examined in dissection.

The case which best illustrates this subject is one which I visited with Dr. Baillie, and Mr. Heaviside, the particulars of which I have obtained from Mr. Heaviside, whom I have ever found ready to make his beautiful anatomical collection useful to the profession.

CASE.

Case.

Master ——, a fine youth, aged twelve years, in June, 1814, was swinging in a heavy wooden swing, and in just commencing the motion forward, was caught by a line which had got under his chin, by which accident his head was violently strained, and the whole of the cervical vertebræ; as, however, the line slipt immediately off, he thought no more of it. Subsequently to the accident, for some months, he was not aware of any pain or inconvenience, but his school-fellows observed that he was less active than usual: instead of filling up his time by play, he would

be lying on the school forms, or leaning on a stile or gate, when in the fields. They were always teasing him on this account; and at last he was persuaded that he was weaker than he used to be. From this time he continued to decline both in strength and power. About the middle of May following he came to London. His complaints were occasional pains in the head, which were more severe and frequent about the back of his neck (where a blister had been applied without relief) and down his back. The muscles at the back of the head and neck were stiff, indurated, and very tender to external pressure. He felt pain in moving his head or neck in any direction; added to these symptoms, there was a great deficiency in the voluntary powers of motion, especially in the limbs.

May 18th. Two setons were made in the neck, and he was ordered various medicines, none of which proved useful.

May 29th. His complaints and the paralytic affection of his limbs were getting much worse, added to which he felt a most vehement hot burning pain in the small of his back. This, by the next day, was succeeded by a sense of extreme coldness in the same part. Some time after the same pain occurred higher up in the back, and then disappeared. Pulse and heat natural.

June 3rd. A consultation of Dr. Baillie, Dr. Pemberton, Mr. A. Cooper, and Mr. Heaviside, was held, and the application of mercury was determined on. The pil hydr: was taken for a few days, but as it ran off by the bowels, mercurial frictions were consequently preferred. He felt his limbs getting every day weaker, but his neck was more free from pain when moved, and he was more capable of moving it by his own natural efforts.

June 7th. His respiration became laborious; he passed a bad night; on the following day all his symptoms increased, and at five in the afternoon he expired.

Examination.

Dissection. The whole contents of the head were carefully examined and found perfectly healthy; but upon sawing out the posterior parts of the cervical vertebræ, the theca vertebralis was found overflowed with blood, which was effused between the theca and the enclosing canals of bone. The dissection being further prosecuted, this effusion extended from the first vertebra of the neck to the second vertebra of the back, both included.

The preparation only shews a small proportion of the effused blood which had become coagulated on the theca, as much of it, being fluid, escaped in the act of removal.

J. H.

FRACTURE OF THE SPINE.

Produce symptoms of irritation on pressure. These accidents, even when the bones retain their situation, produce, by admitting unnatural variations in the positions of the spinal column, very extraordinary symptoms, and sometimes sudden death. Mr. Else, who preceded Mr. Cline as teacher in anatomy at St. Thomas's Hospital, used to mention the following case in his lectures.

CASE.

Case. A woman who was in the venereal ward at St. Thomas's

Hospital, and who was then under a mercurial course, while sitting in bed, eating her dinner, was observed to fall suddenly forward; and the patients, hastening to her, found that she was dead. Upon examination of her body, the dentiform process of the second vertebra had been broken off, the head, in falling forwards, had forced the root of the process back upon the spinal marrow, which had occasioned her instant dissolution.

At the time when I lived with Mr. Cline, as his apprentice, the following case occurred in his practice, the particulars of which I cite from his account.

CASE.

A boy, about three years of age, from a severe fall, injured his neck; and the following symptoms succeeding the accident, Mr. Cline was consulted. Fracture of the atlas.

He was obliged to walk carefully upright, as persons do when carrying a weight on the head; and when he wished to examine any object beneath him, he supported his chin upon his hands and gradually lowered his head, to enable him to direct his eyes downwards; but if the object was above him, he placed both his hands upon the back of his head, and very gradually raised it until his eyes caught the point he wished to see. Symptoms.

If, in playing with other children, they ran against him, it produced a shock which caused great pain, and he was obliged to support his chin with his hand, and to go immediately to a table, upon which he placed his elbows, and thus supporting his head he remained a considerable time, until the effects of

concussion had ceased. He died about twelve months after the accident; and upon the inspection of his body, which was conducted by Mr. Cline, the first vertebra of the neck was found broken across, so that the dentiform process of the second vertebra had so far lost its support, that, under different inclinations of the head, it required great care to prevent the spinal marrow from being co npressed by it; and as the patient could not depend upon the action of the muscles of the neck, he therefore used his hands to support the head during different motions and positions.

Spinous process.

Portions of the spinous processes are sometimes broken off, but these accidents do not usually affect the spinal marrow, unless when attended with considerable concussion. Mr. Aston Key, in dissecting a subject at St. Thomas's Hospital, found a spinous process loose, which he kindly brought to me, with the following account: "The fractured vertebra was the third dorsal: the cause of the accident I could not ascertain, as it occurred in a subject brought into the dissecting room. There was a complete articulation formed between the broken surfaces, which had become covered with a thin layer of cartilage. The synovial membrane and capsular ligaments resembled those of other joints, excepting that the former was more vascular. The fluid within the joint had the lubricating feel characterizing synovia.

CASE.

Case.

A boy was admitted into Guy's Hospital, who had been endeavouring to support a heavy wheel by putting his head between the spokes, and receiving its weight upon his shoulders. The

wheel overbalanced him, and he fell, bent double. When he was brought into Guy's Hospital, although he had been perfectly straight before, he had the appearance of one who had long suffered from distorted spine, yet this injury had not produced paralysis of the lower extremities. Three or four of the spinous processes had been broken off, and the muscles torn on one side, so as to give an obliquity to the situations of the fractured portions. This boy quickly recovered without any particular attention, and was discharged with the free use of his body and limbs, but he still remained deformed.

FRACTURES OF THE BODIES OF THE VERTEBRÆ, WITH DISPLACEMENT.

These fractures frequently come under our observation, producing displacement of the vertebræ. As the symptoms and result of the accident differ according to the situation of the fractured bones, these injuries may be divided into two classes: *first*, those which occur above the third cervical vertebra; and, *secondly*, those which occur below that bone.

Displacement of the vertebræ.

In the first class, the accident is almost always immediately fatal, if the displacement be to the usual extent. Death, in the second class, occurs at various periods after the injury. The origin of the phrenic nerve, from the third and fourth cervical pair, is the reason of this difference; for as the parts below are

These accidents fatal.

paralyzed by the pressure upon the spinal chord, if the accident be below the fourth cervical vertebra, the phrenic nerve retains its functions, and the diaphragm supports respiration; but if, on the contrary, the fracture be situated above the origin of this nerve, death immediately ensues. It is true, that a small filament of the second cervical nerve contributes to the formation of the phrenic, but is in itself insufficient to support respiration under fracture of the third vertebra.

Displacement below the phrenic nerve.

The effects which arise from fracture and displacement of the spine, below the origin of the phrenic nerve, depend upon the proximity of the accident to the head. If the lumbar vertebræ be displaced, the lower extremities are rendered so completely insensible, that no injury inflicted upon them can be perceived by the patient. Pinching, burning with caustic, or the application of a blister, are alike unfelt. The power of volition is completely destroyed, not the smallest influence over the muscles remaining. The sphincter ani loses its power of resistance to the peristaltic motion of the intestines, and the fæces pass off involuntarily. The bladder is no longer able to contract, and the urine is retained until drawn off by a catheter, and yet the involuntary powers of the limbs remain nearly the same as before. The circulation proceeds, although perhaps somewhat more languidly, but sufficiently to preserve their heat; and local inflammation can be excited in them. A blister applied upon the inner side of the thigh or leg, of which the patient is wholly unconscious, will still inflame, vesicate, and heal; shewing that the involuntary functions may proceed in parts which are cut off from their connection with

Lumbar vertebræ.

the brain and spinal marrow.* The penis, under these circumstances, is generally erect. Patients die from this injury at various periods, according to the degree of displacement of the vertebræ. In general, in fractures of the lumbar vertebræ, the patient dies within the space of a month or six weeks after the injury; and usually for some time before death, the urine passes off involuntarily, from extreme debility. I remember a patient of Mr. Birch, in St. Thomas's Hospital, who lived more than two years after this accident, and then died of gangrene of the nates.

Displacement of the dorsal vertebræ.

In fractures and displacement of the dorsal vertebræ, the symptoms are very similar to those described in fractures of the lumbar; but the paralysis extends higher, and the abdomen becomes excessively inflated. I remember one of our pupils saying, when a patient was brought into Guy's Hospital who had suffered from injury to the dorsal vertebræ, "Surely this man has ruptured his intestines, for observe how his abdomen is distended." But the first fæcal evacuation relieved this state, and proved that it had merely arisen from excessive flatulency. This symptom proceeds from diminished nervous influence in the intestines;† for although their peristaltic motion can proceed independently of the brain and spinal marrow, yet it is quite certain that the involuntary functions of the intestines, like those of the heart, can be influenced by the brain and spinal marrow; for we see even states of the mind producing affections of the intestines; one state rendering

* I have always thought that although sensation and volition depend upon the brain, the spinal marrow, and the nerves, yet the involuntary functions depend principally upon the nerves.

† Preceding dissolution, in almost all diseases, a great evolution of air into the intestines is observed, and from the same cause.

them torpid, and another irritable; as we see the heart leaping with joy, and depressed by disappointment. We also observe pressure on the brain rendering the intestines very difficult of excitement, even through the influence of the strongest aperients. From displacement of the dorsal vertebræ, death sooner succeeds than in similar injuries to the lumbar, the patient usually surviving the accident not more than a fortnight or three weeks: but still I knew a case of a gentleman in the City, who met with this accident, and who lived rather more than nine months. The period of existence is short or protracted, as the injury is near or distant from the cervical vertebræ, and as the displacement is slight or considerable; it depends also upon the degree of injury which the spinal marrow has sustained.

Fractures of the cervical vertebræ.

Fractures of the cervical vertebræ, below the origin of the phrenic nerve, produce paralysis of the arms, as well as of the lower parts of the body; but this paralysis is seldom complete. If it occurs at the sixth or seventh vertebra, the patient has some feeling and powers of motion; but if at the fifth, little or none. Sometimes one arm is much more affected than the other, when the fracture is oblique, and the axillary plexus of nerves is, in consequence, partially influenced. Respiration in these cases is difficult, and is performed wholly by the diaphragm, the power of the intercostal muscles being destroyed by the accident. The abdomen is also tumid from flatulency, as when the dorsal vertebræ have sustained injury. The other symptoms, in regard to the lower extremities, the bladder, and the sphincter ani, are the same as in fractures of the vertebræ below the cervical. Death ensues in these cases in from three to seven days, as the

disease happens to be seated in the fifth, sixth, or seventh vertebra. I have scarcely known the subject of this injury to live beyond a week, and but rarely to die on the second day, although they sometimes die so early, if the fifth cervical vertebra has sustained the injury. I have already stated, that in fractures and displacements above the fourth cervical vertebra, death almost instantaneously follows. The longest life I have known after such an accident has been ten minutes.

Dissection.

In the dissection of these cases the following appearances are found: The spinous process of the displaced vertebra is depressed; the articular processes are fractured; the body of the vertebra is broken through; for it but rarely happens that the separation and displacement occur at the intervertebral substance. The body of the vertebra is usually advanced from half an inch to an inch. Between the vertebræ and the sheath of the spinal marrow, blood is extravasated; and frequently there is extravasation of blood on the spinal chord itself. The spinal marrow is compressed and bruised in slight displacements, and is torn through when the injury has been very extensive; but the dura mater remains whole. A bulb is formed at each end of the lacerated spinal marrow, which laceration is usually produced by the bony arch of the spinous process.

A most interesting case of this accident has been published by Mr. Harrold, an intelligent surgeon at Cheshunt; and a preparation made from his case is preserved in the Museum at the Royal College of Surgeons.

The outline of the case is as follows:

CASE.

Case. A man, twenty-eight years of age, was knocked down by a quantity of chalk, which, falling upon him, broke his spine at the lower part of the dorsal, or the beginning of the lumbar, vertebra.

The principle upon which Mr. Harrold proceeded was, to produce union of the bones, by preserving the spine perfectly at rest; and to effect this object the patient was placed in a fracture bed, which permitted him to evacuate his bowels without disturbance. The urine was drawn off daily by the catheter for several weeks; after which time he was able to retain from a pint to a pint and a half, and to discharge it when he pleased. A wound was produced upon the sacrum, from the constant pressure of his body upon the bed; and, although he was insensible of it, the sore gradually healed.

Symptoms. At the end of six months his state was as follows: His back was straight, flexible, and apparently as strong as ever. He retained and passed his urine, but probably he discharged it more by the action of the abdominal muscles than by any contraction of the bladder. He had a stool once in three or four days. His health and spirits were good, but he had neither sensation nor volition in the lower extremities. He dressed himself entirely: he let himself down stairs step by step. He died after the lapse of twelve months, wanting nine days, from the accident, owing to a sore on the tuberosity of the ischium, and to disease of the bone.

Examination. I carefully examined the preparation, which is preserved in the Museum of the College, and found the following circumstances:

The bodies of the first and second lumbar vertebræ had been fractured: the first had advanced, and the second had been forced backwards.

The fracture had united by ossific matter, which had been spread over the fore part of both vertebræ to a considerable extent, and a little had been deposited upon the dorsal vertebræ.

The spinal canal had been much diminished by a portion of bone forced into it from the first vertebra of the loins: this portion of bone had split the theca vertebralis into two, and divided the spinal marrow almost entirely: a bulbous projection of the spinal marrow appeared above and below the bone, formed by its divided extremities, which were separated nearly an inch from each other.

Mr. Brookes also has a preparation in his excellent anatomical collection, of fracture of the spine at the seventh and eighth dorsal vertebræ. The person had lived sufficiently long for a great deposit of ossiffic matter to have formed upon the anterior and lateral part of the fractured vertebræ. The spinal marrow was almost entirely torn through, but the spinal sheath remained. Mr. Brookes could not learn how long the person had survived the accident.

Ossific matter.

As to the treatment of these cases, I fear, that whatever be done, the majority of them will prove fatal.

To bring the spine into its natural form by extension would be impossible, if it were attempted; and even if that object were attained, it would scarcely be practicable to preserve it in its situation, as the least motion would again displace it. Rest will

be essential to ossific union, but ossific union will not save the patient if the pressure upon the spinal marrow be not removed.

Operation by Mr. H. Cline.

Mr. Henry Cline was the only person who took a scientific view of this accident. He considered it to be similar to fracture with depression of the cranium, and to require that the pressure should be removed; and as the cases had proved so uniformly fatal, he thought himself justified in stepping out of the usual course, with the hope of preserving life. He made an incision upon the depressed bone as the patient was lying upon his breast, raised the muscles covering the spinal arch, applied a small trephine to the arch, and cut it through on each side, so as to remove the spinous process, and the arch of bone which pressed upon the spinal marrow. The only case in which he tried it did not succeed; and, unfortunately, he did not live to bring his opinion sufficiently to the test of experiment, to warrant a decided judgment. He was blamed for making this trial. I am not sure that he would have been ultimately successful; but, in a case otherwise without hope, I am certain that such an attempt was laudable.*

In those cases in which the first and second cervical vertebræ have been broken and displaced, death, from obstructed respiration, is too sudden to allow time for any surgical relief.

---

* I beg the reader to observe, that this operation is not mine,—that I have expressed some doubts of its ultimate success; but I wish the trial to be made, as the only means of deciding positively on its utility; and if it saves only a life in one hundred, it is more than I have yet seen accomplished by surgery.

INFLAMMATION AND ULCERATION OF THE SPINAL MARROW.

The only case which I could determine to be of this nature by dissection was the following:

CASE.

A gentleman, who resided about eight miles from London, had, by a fall, received a severe blow upon his spine; but as it produced no immediate ill effect he thought very lightly of it. In going down to his country house he was exposed to the inclemencies of the weather, and he was on a sudden seized with pain in his back, and paralysis of the lower extremities, retention of urine, and an involuntary discharge of fæces. I was requested to see him on account of the retention of urine, and went daily for a length of time to Wimbledon Common, where he resided, to make use of the catheter. For several weeks his symptoms remained unchanged, excepting that now and then the integuments of the sacrum gave way, and required great attention to prevent a dangerous sore. Towards the close of his existence he complained of a sense of uneasiness and distention at the upper part of his abdomen. His appetite failed him; he rejected his food, and had a great deal of fever, with quick pulse and profuse perspiration. He sunk gradually, worn out by irritation. Case.

I removed the spinal marrow, and have it preserved in the collection at St. Thomas's Hospital.

Upon opening the spinal sheath, a milky fluid was found within Dissection.

it, just above the cauda equina; and higher than this, for the space of three inches, the spinal marrow was ulcerated to a considerable depth, and was in the softened state which the brain assumes when it is rendered semifluid by putrefaction. All the other parts of the body were healthy, excepting the bladder, which was considerably inflamed and exceedingly extended by the long continued retention of the urine.

In a case similar to this, it will be necessary to make use of precautions to prevent inflammation, by cupping or by leeches. Blisters should be applied; and if the fever still continue, a seton should be made, or issues be opened, to prevent the continuance of inflammation, by producing and supporting external irritation.

EXPLANATION OF PLATES.

PL. 1.

FIG. 1.

FIG. 2.

FIG. 3.

FIG. 5.

FIG. 4.



PLATE I.

Shews the positions of the limb in the different dislocations of the thigh-bone, and in the fracture of the cervix femoris.

Fig. 1.

The thigh-bone dislocated *upwards,* upon the dorsum ilii.

The leg shorter; the hip projecting; the knee turned inwards, and the patella at least two inches higher than the other. The foot turned inwards, and the toes resting upon the metatarsal bones of the other foot. The head of the bone is thrown back, and the trochanter major forwards.

Fig. 2.

The dislocation *downwards* in the foramen ovale.

The leg is longer than the other; the knee is advanced and separated from that on the sound side; the toe is pointed down; the heel does not touch the ground: the body is bent forwards.

This is the only accident of this joint in which the leg is longer.

Fig. 3.

Dislocation in the ischiatic notch.

The leg is shorter; the patella from half an inch to an inch above the other; the foot slightly turned inwards; the great toe rests against the ball of the great toe of the other foot; the leg is with difficulty separated from the other.

In thin persons the head of the os femoris may be felt a little above and behind the acetabulum; more especially if the surgeon rolls the knee inwards.

Fig. 4.

Dislocation of the os femoris upon the pubes.

Prominence at Poupart's ligament, from the head of the bone; the knee turned out, and widely separated from the other; leg a little shorter, the one patella being about an inch higher than the other; the toe touches the ground, but the heel does not reach it; the knee and foot turned out.

Fig. 5.

Fracture of the neck of the thigh-bone.

The leg shorter; the knee turned out; the patella from one to two inches above the other, and sometimes more; the foot is generally everted, and does not reach the ground when the other leg is straight; the leg is easily drawn to the same length with the other, and then, if rotated, a crepitus is felt.

PL. II.

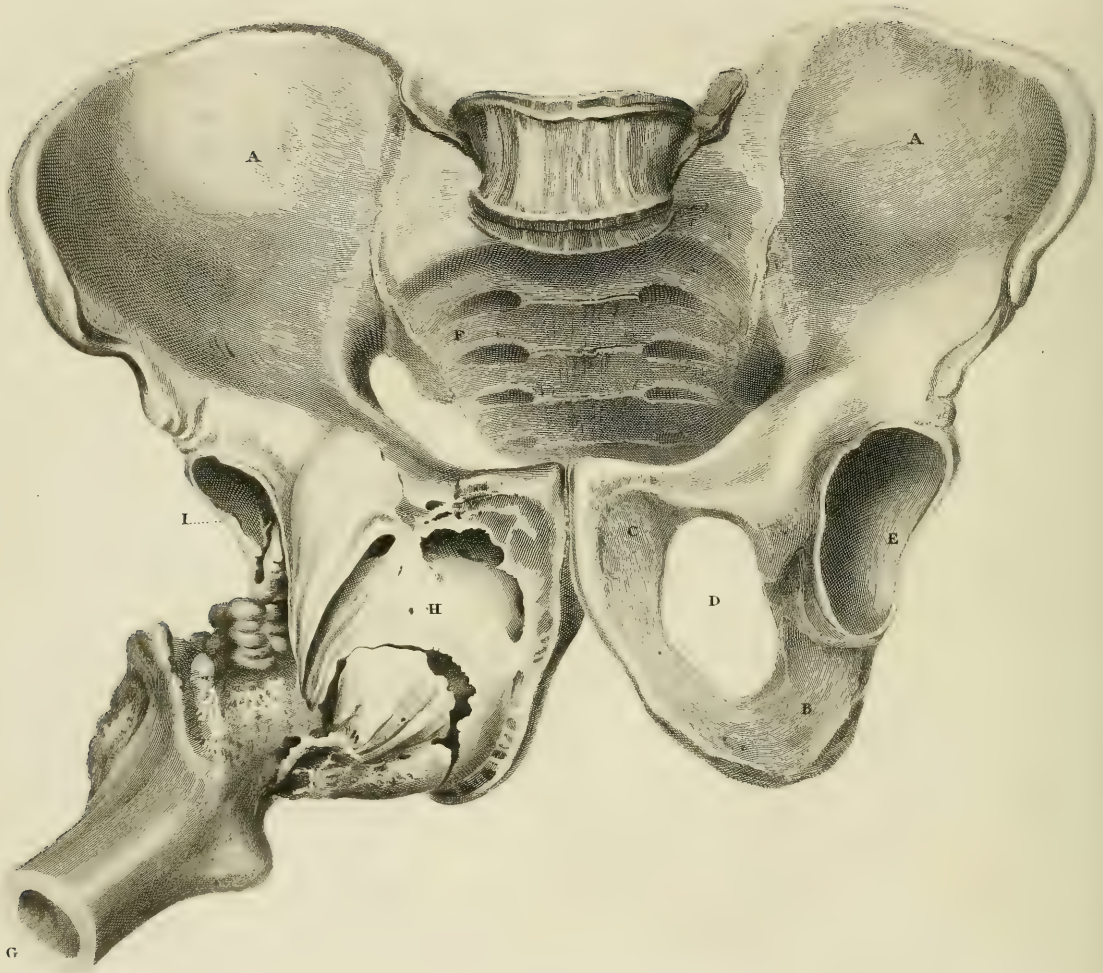

Published by Astley Cooper 1822

PLATE II.

Shews a dislocation into the foramen ovale which had never been reduced, and beautifully exhibits the resources of nature, in forming a new socket for the head of the bone, and allowing of the restoration of a considerable degree of motion.

A. Right and left ilium
B. Ischium
C. Pubes
D. Foramen ovale
E. The left acetabulum
F. Sacrum
G. Os femoris
H. The new acetabulum, formed in the foramen ovale, in which the head of the thigh-bone was contained, and in which it was so completely enclosed, that it became impossible to remove it, unless a portion of the new socket were broken away. It was lined by a ligamentous substance, on which the head of the bone moved to a considerable extent
I. The original acetabulum, situated above the level, and to the outer side, of the new cavity.

Museum, St. Thomas's Hospital.

PL. III.

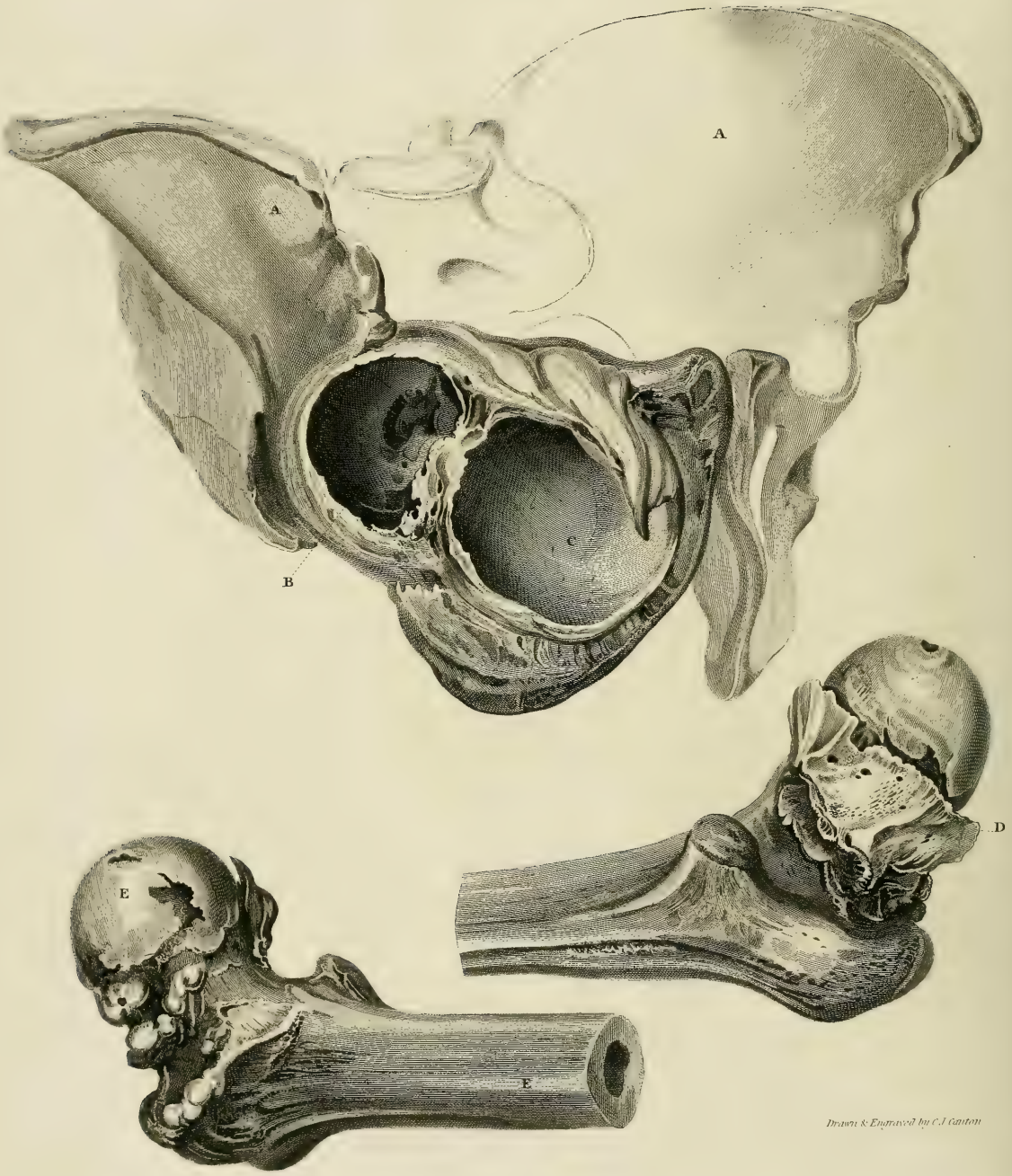

Drawn & Engraved by C. J. Canton

Published by Astley Cooper & Co.

PLATE III.

Exhibits another view of the same preparation, shewing the relative situation and appearance of the new and original acetabulum.

AA. Ilia

B. The original acetabulum, little more than half its natural size, the edge of the new acetabulum occupying its lower and anterior part

B. The new acetabulum formed in the foramen ovale, a deep ossific edge surrounding it; its internal surface is extremely smooth. The ligament of the foramen ovale has disappeared, and ossific matter has been deposited in its stead

D. The thigh-bone removed, and the portion of the new acetabulum is shewn, which was obliged to be broken off to separate the thigh-bone from its new socket

E. Head and neck of the thigh-bone; the former a little changed by absorption, and the latter by ossific deposit.

PL. IV.

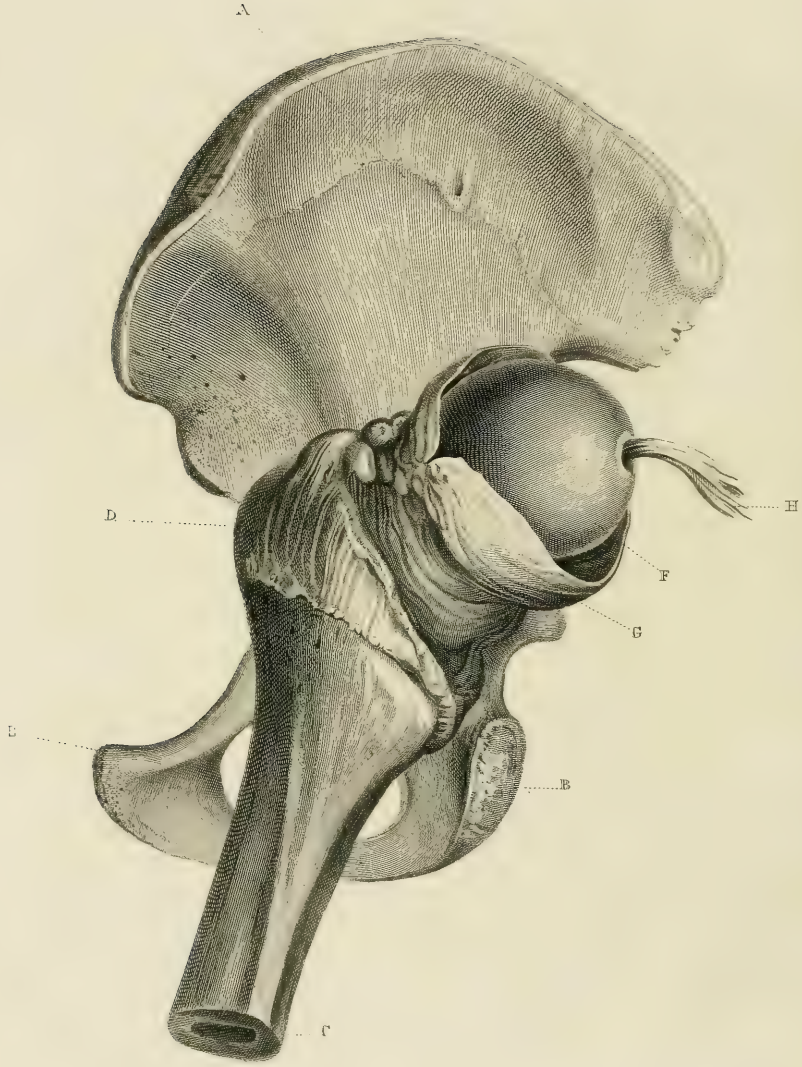

Drawn & Engraved by [illegible]

Published by Astley Cooper 1822

PLATE IV.

Shews a dislocation in the ischiatic notch. This is a side view of the exterior surface of the os innominatum.

A. Ilium
B. Ischium
C. Pubes
D. Trochanter major, covering and concealing the acetabulum
F. Head of the os femoris thrown into the ischiatic notch, and situated between the posterior and inferior spinous process of the ilium, and the spinous process of the ischium
G. A new capsular ligament, formed around the head of the bone, and composed of cellular membrane, condensed by inflammation.
H. Ligamentum teres, which had been torn through in the dislocation, as well as the original capsular ligament.

Museum, St. Thomas's Hospital.

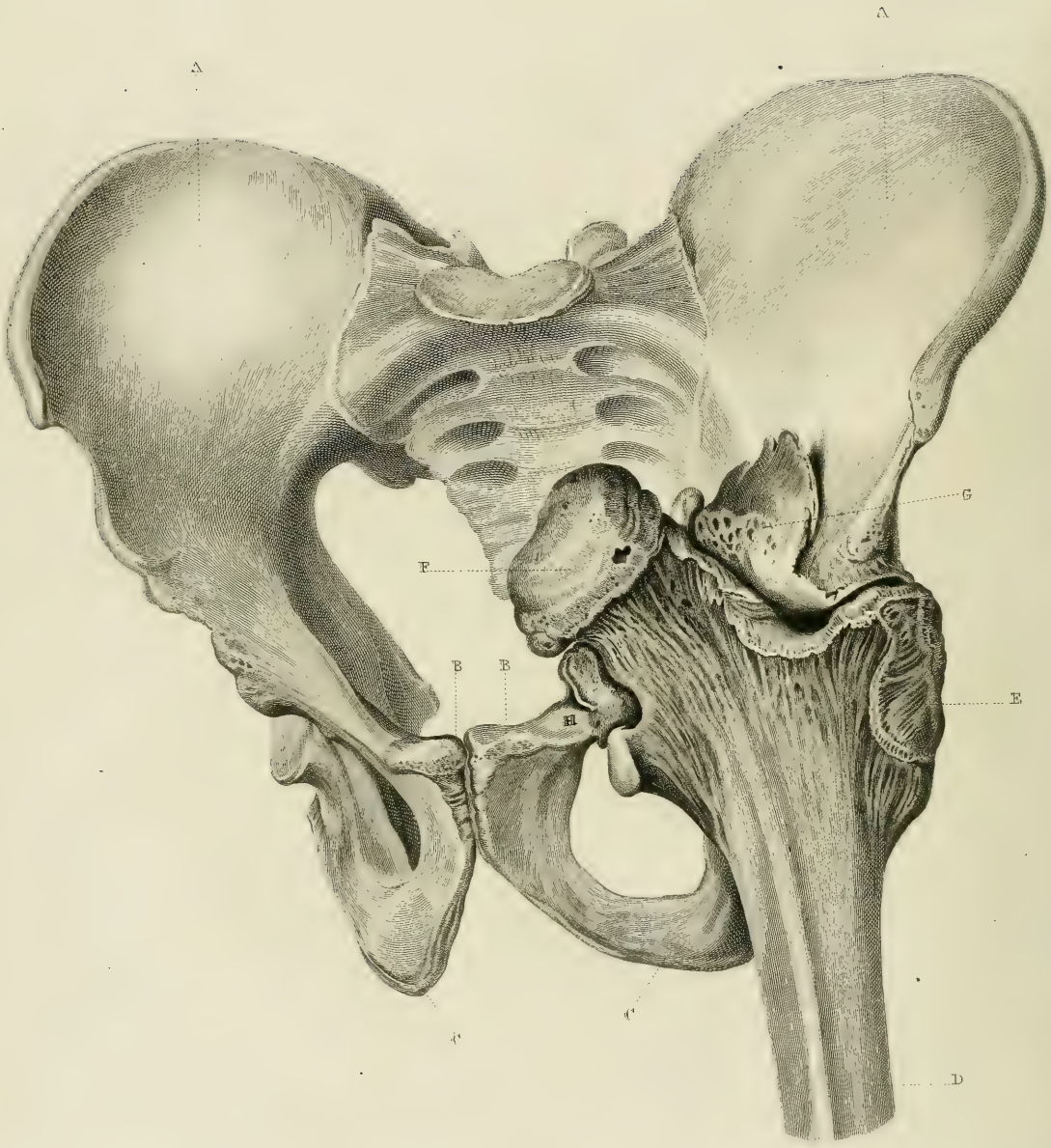
A
A
G
F
B
B
E
H
C
C
D

PLATE V.

Exhibits a view of the dislocation of the os femoris upon the pubes, or forwards and upwards. This preparation beautifully shews the power of nature in accommodating itself to new circumstances.

A A. Ilia
B. Pubes
C. Ischia
D. Os femoris
E. Trochanter major, occupying the original acetabulum
F. Head and neck of the os femoris, upon the junction of the pubes and ilium
G. The new cup formed for the neck of the os femoris
H. The femoral artery and vein, passed upon the smooth surface of the pubes, on the inner side of the new acetabulum.

Museum, St. Thomas's Hospital.

PL. VI.

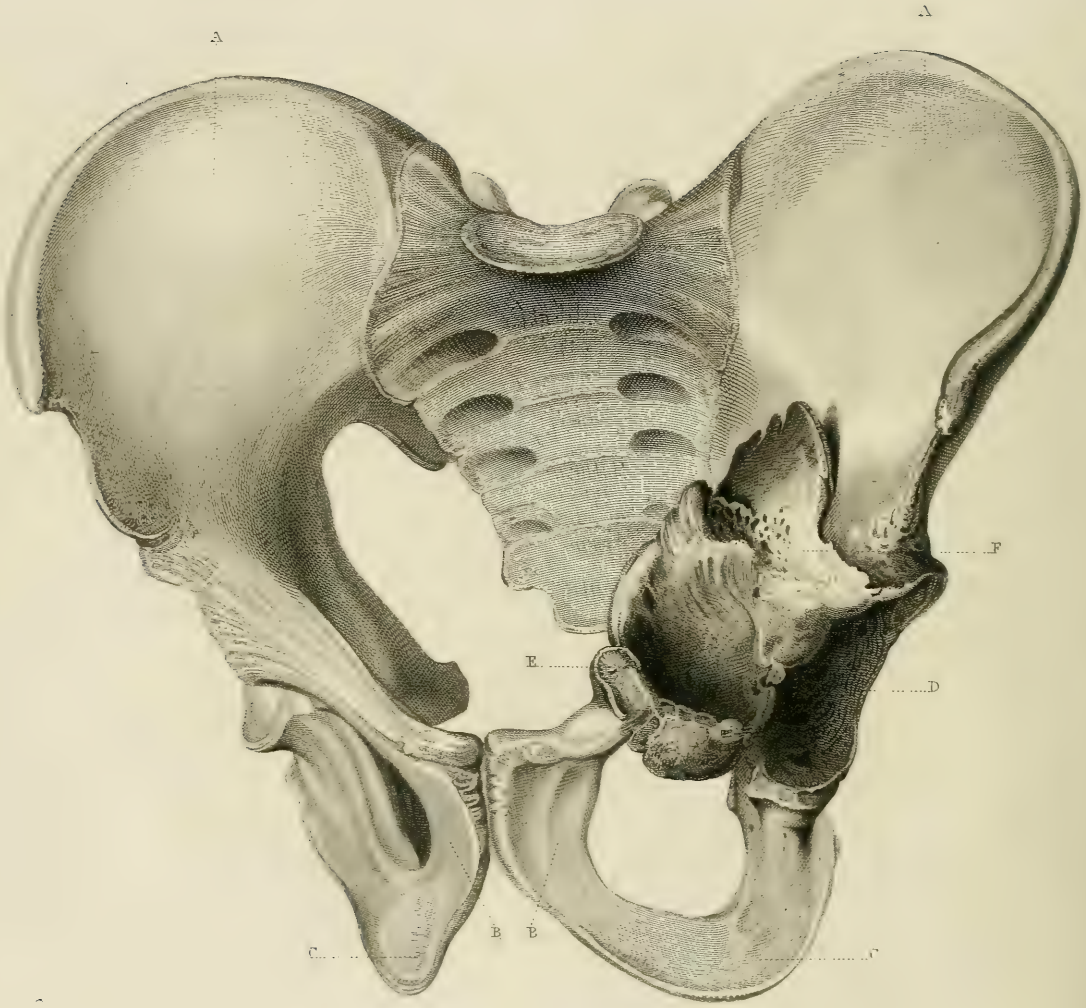

PLATE VI.

Shews the same pelvis, with the thigh-bone removed from it, to expose the new acetabulum formed by ossific inflammation on the junction of the pubes and ilium.

AA. Ilia
BB. Pubes
CC. Ischia
D. Acetabulum which was occupied by the trochanter major
EF. The new acetabulum.

Under the line E. the femoral artery and vein took their course.

C
D
A
B

PLATE VII.

Dislocation and fracture of the pelvis.

A. Fracture of the pubes on the left side
B. Fracture of the ischium on the same side
C. Dislocation of the right ilium
D. Laceration of the ilio sacral ligament, and separation of the ilium from the sacrum.

PL.VIII.

Fig. 1.

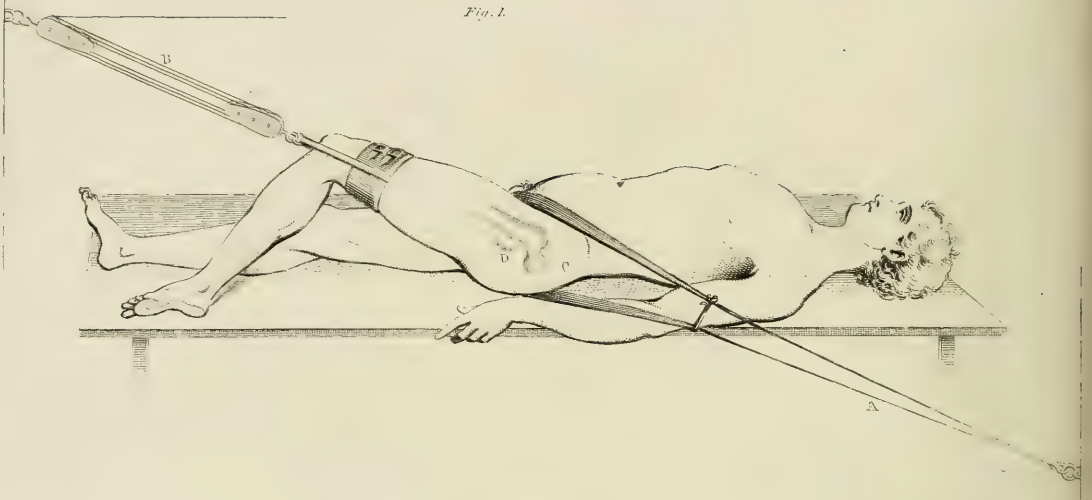

Fig 2

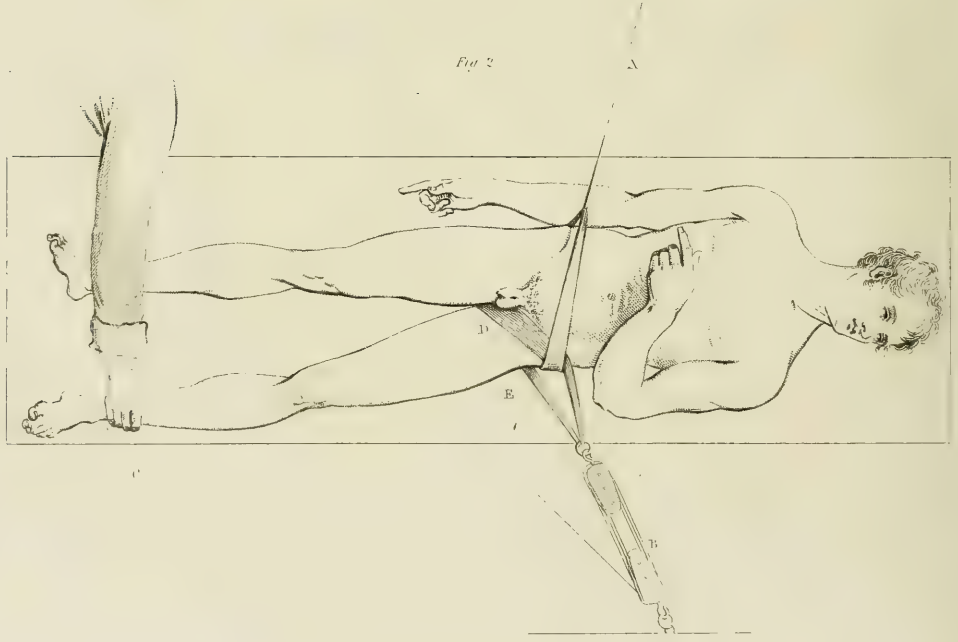

PLATE VIII.

Fig. 1.

Shews the mode of reducing the dislocation *upwards*, on the dorsum ilii.

A. The band passed between the thighs to fix the pelvis
B. The pulley fixed above the knee, and the direction shewn in which the thigh is to be drawn; viz., obliquely across the sound thigh, two thirds of its length downwards
C. Head of the bone upon the dorsum ilii
D. Acetabulum.

Fig. 2.

Dislocation in the foramen ovale.

A. Bandage to fix the pelvis
B. The pulley to draw the head of the os femoris outwards and upwards
C. The surgeon's hand grasping the ancle to draw the one leg across the other, and to throw the head of the bone outwards
D. Head of the bone in the foramen ovale
E. Acetabulum, into which the head of the bone is to be brought.

PL.IX.

Fig 3.

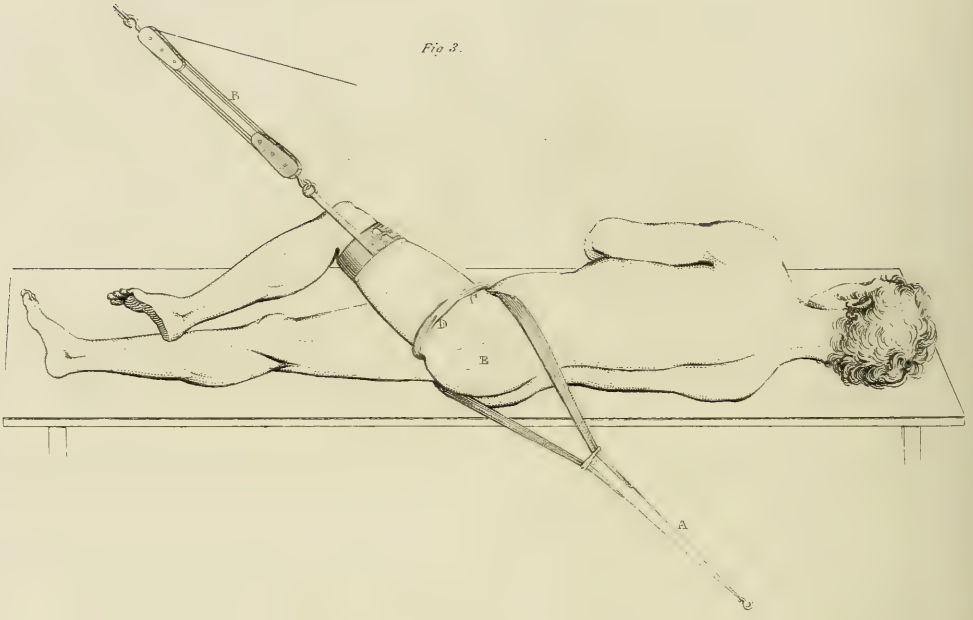

Fig 4.

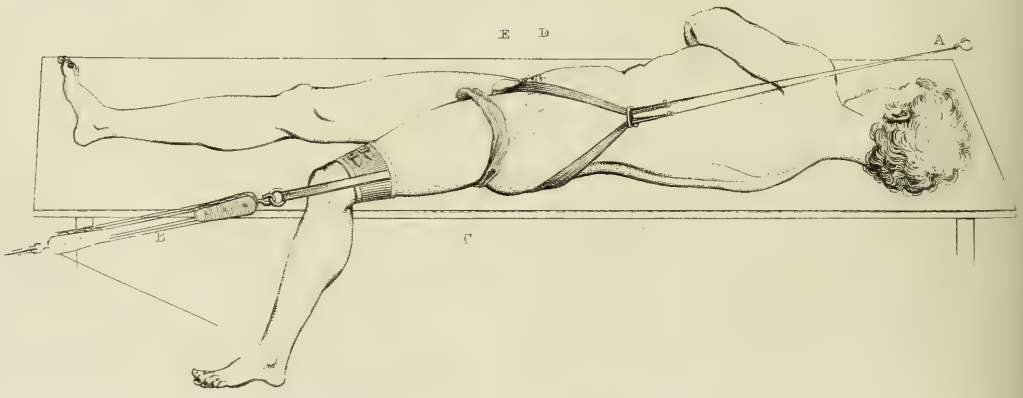

Published by Asher & Cooper 1822

PLATE IX.

Fig. 3.

This is a view of the mode of reducing the dislocation into the ischiatic notch.

A. The bandage which fixes the pelvis, and which passes between the thighs

B. The pullies fixed above the knee, and extending in a direction across the middle of the sound thigh

C. A band surrounding the thigh, by which the surgeon is to elevate the bone when the extension has been for some time continued

D. The acetabulum

E. The head of the bone in the ischiatic notch.

Fig. 4.

This figure shews the best mode of reducing the dislocation of the os femoris upon the pubes.

A. The bandage to fix the pelvis passing upwards and forwards

B. The pullies which draw the bone downwards and backwards

C. A band passed around the thigh, to enable the surgeon to raise the head of the bone during the extension

D. Head of the os femoris on the pubes

E. The acetabulum: above and before which the head of the bone rests upon the junction of the pubes and ilium.

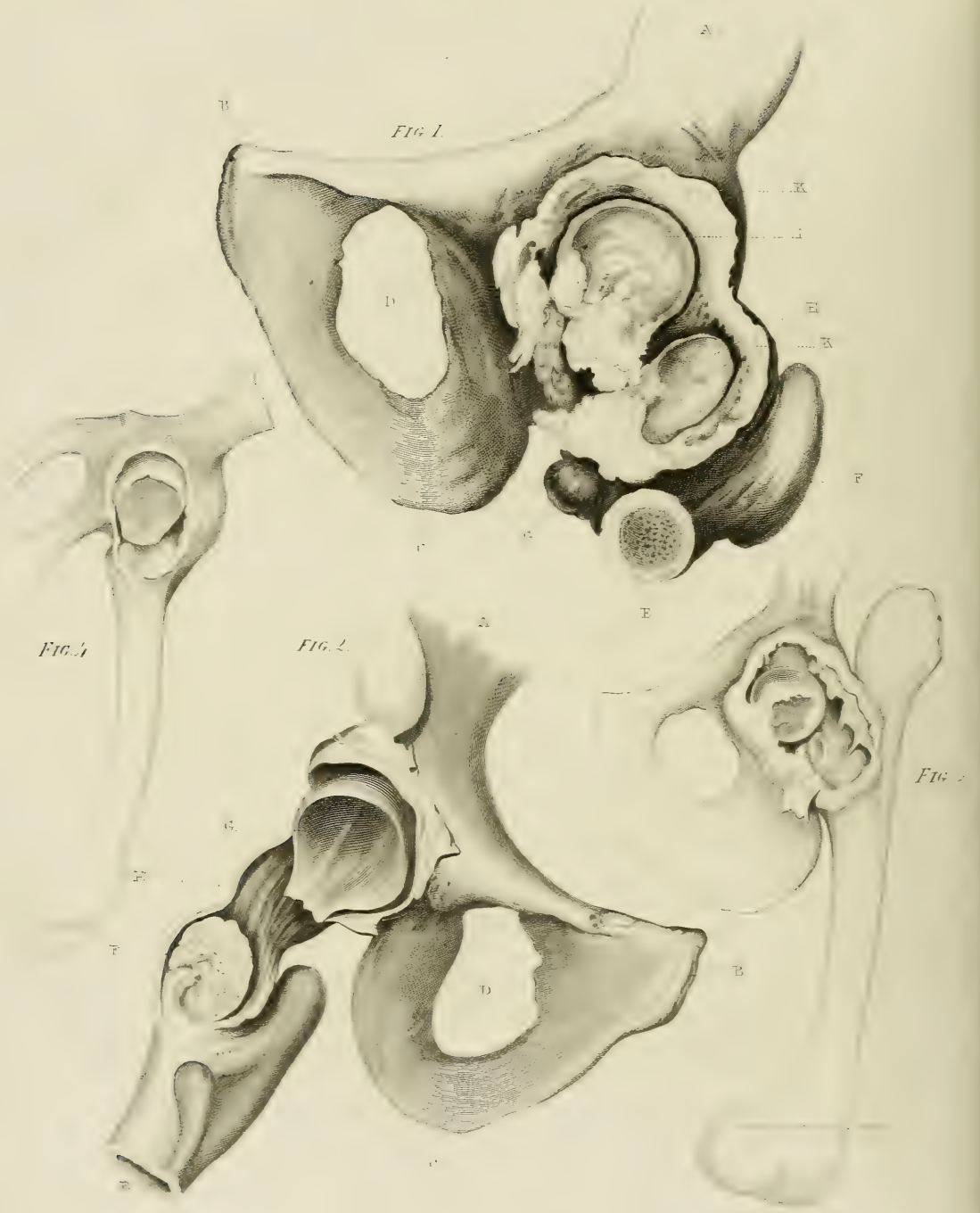
A
B
FIG. 1.
K
I
D
H
N
F
C
G
E
FIG. 4.
FIG. 2.
A
G
H
F
D
B
C
FIG. 3

PLATE X.

Shews fractures of the neck of the thigh-bone in man, and in other animals, as they usually appear on dissection.

Fig. 1.

Ligamentous union shewn.

A. Ilium
B. Pubes
C. Ischium
D. Foramen ovale
E. Os femoris
F. Trochanter major
G. Trochanter minor
H. Neck of the thigh-bone broken within the capsular ligament, and in a great degree absorbed, as it generally is soon after the accident: its surface smooth from friction, and rounded to roll upon the hollow of the head of the bone
I. Head of the bone, hanging in the acetabulum by the ligamentum teres only, smoothed by one bone rubbing against the other: a portion of its surface having ligament secreted upon it
K. The capsular ligament exceedingly thickened; more especially on that part of the joint which is opposite to the foramen ovale.

Fig. 2.

A. Ilium
B. Pubes
C. Ischium
D. Foramen ovale
E. Os femoris
F. Broken cervix femoris, in a great degree absorbed
G. The head of the bone, supported by the ligamentum teres, and having no other connection with the body: its surface smoothed by friction when the person begins to walk.

In each of these preparations the head and neck of the bone, conjointly, would not form more than one third the natural length of those parts.

Fig. 3.

The neck of the bone broken in a dog, and no union is produced but by ligament.

Fig. 4.

The neck of the thigh-bone broken and ununited but by ligament. The ligament in this experiment was not injured in breaking the bone.

Fig. 1.

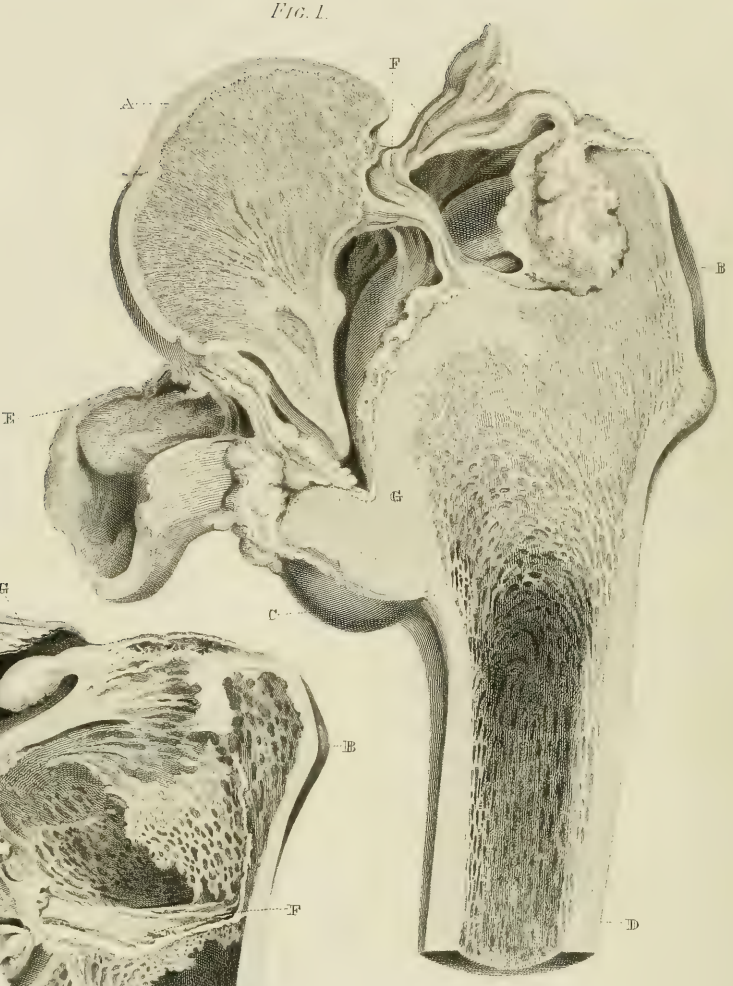

Fig. 2.

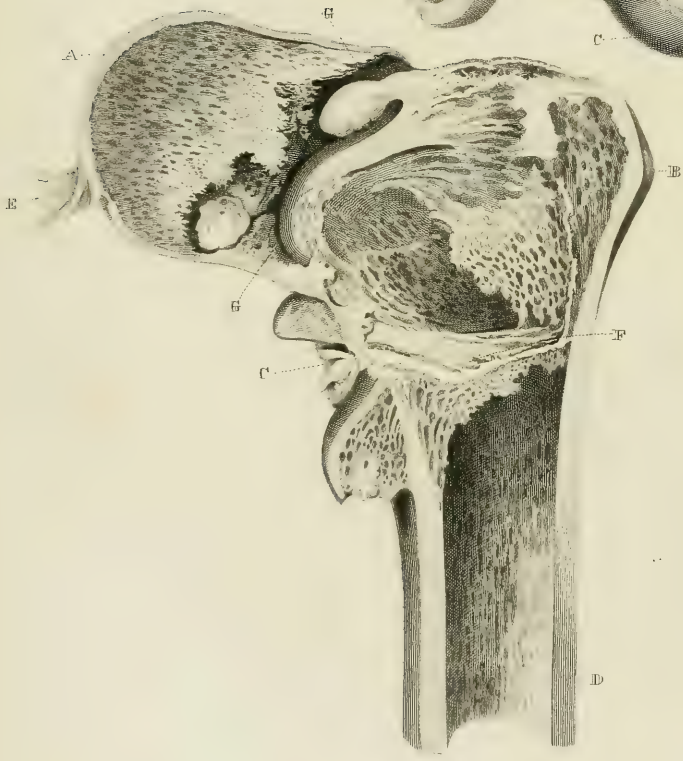

Published by Astley Cooper, 1823

PLATE XI.

Fig. 1.

Shews a preparation of Mr. Langstaff's. A fracture of the thigh-bone united, as it usually is, by ligament.

A. Head of the thigh-bone
B. Trochanter major
C. Trochanter minor
D. Shaft of the os femoris
E. Capsular ligament excessively thickened
F. Ligamentous productions uniting the neck to the head of the bone
G. A fork formed in the trochanter minor, which received the head of the bone, and prevented its further descent.

Fig. 2.

Shews a preparation of Mr. Langstaff's. The upper part of the thigh-bone broken within the capsule and external to it. That external to the capsule firmly united by bone, and that within it ununited.

A. Head of the thigh-bone
B. Trochanter major
C. Trochanter minor
D. Shaft of the bone

E. Ligamentum teres, in its usual situation as regards the head of the bone, and, as will be seen, not at its centre.

F. Fracture of the thigh-bone external to the capsule, firmly and well united by bone

G. Fractured cervix within the capsule, still remaining ununited, even by ligament.

PL. XII.

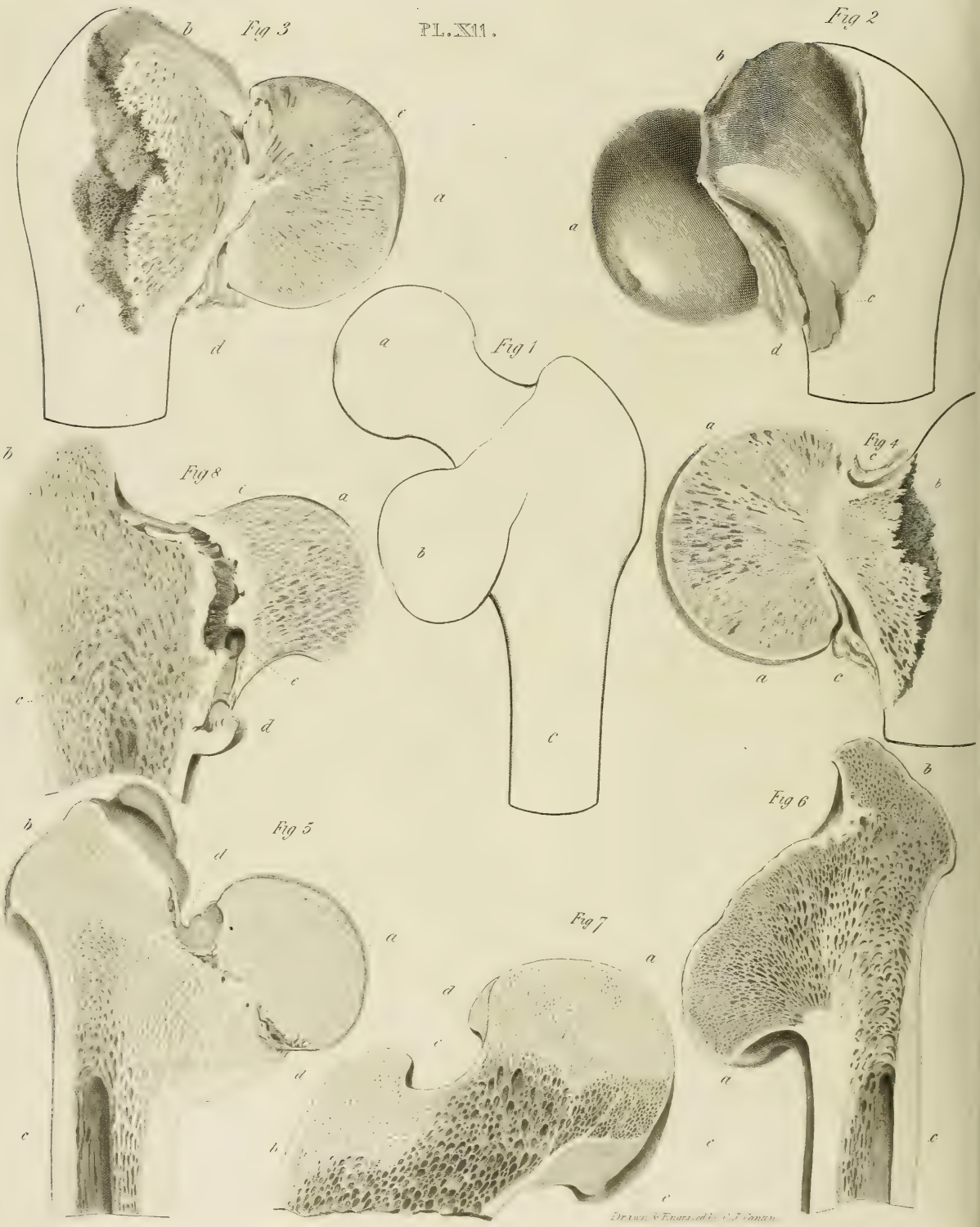

Drawn & Engraved by C. J. Cantan

PLATE XII.

Contains views of the altered state of the neck of the thigh-bone, by which it is rendered incapable of supporting the superincumbent weight of the body, gradually becoming absorbed, and the head of the bone descends to the trochanter minor.

Fig. 1.

Is a diagram of the upper part of the thigh-bone, to shew the change in figure it undergoes from a softened and absorbed state of its cervix.

A. Natural position of the head of the bone
B. Head of the bone fallen to the trochanter minor
C. Shaft of the thigh-bone.

Fig. 2.

Head of the thigh-bone fallen; neck of the bone absorbed and shortened, so that the head and trochanter are brought together.

A. Head of the bone
B. Trochanter major
C. Shaft of the bone
D. Ligament attached to the remains of the cervix.

Fig. 3.

Shews in a section the internal view of fig. 2. The cervix femoris in a great degree obsorbed; the head of the bone and trochanter major in contact.

A. Head of the thigh-bone

B. Trochanter major

C. Shaft of the bone

D. Ligament entering between the head and cervix

E. Cervix femoris in a great degree absorbed. This disease occurred on both sides in the same subject.

Fig. 4.

Section of the head and neck of the thigh-bone, the neck in a great degree absorbed.

A. Head of the os femoris

B. Trochanter major

CC. Remains of the cervix and ligament.

Fig. 5.

Head and neck of the thigh-bone sunken down an inch and a quarter towards the trochanter minor; neck of the bone absorbed, shortened, and a line formed at the part at which it yields to the superincumbent weight, which gives it the appearance of having been fractured; wholly, in some sections of it, partially, in others.

A. Head of the thigh-bone

B. Trochanter major

C. Shaft of the bone

DD. Line of absorption of the phosphate of lime: in the recent state a ligamento cartilaginous substance is found.

I have several sections of this state of the bone; two in which the line of absorption extends quite through; two in

which it extends partially through; and one in which the line of abs orption has taken quite a different direction.

Fig. 6.

Shews the greatest descent of the head of the thigh-bone which I have seen. Let this section be brought in comparison with fig. 1, and the great alteration which it has undergone will be at once obvious: the head of the bone, instead of being at A. is at B. of fig. 1, pressed down by the superincumbent weight of the body.

A. Head of the bone
B. Trochanter major
C. Shaft of the bone.

Thus the neck of the thigh-bone undergoes great changes in form, length, and direction.

Fig. 7.

Shews the changes which are sometimes found in old and bed-ridden persons.

A. Head of the thigh-bone
B. Trochanter major
C. Cancelli of the neck of the bone increased in coarseness by absorption, so as to render the bone weaker, and, when dried, diaphanous
D. Piece of bone added to the upper part of the cervix
EE. A larger piece of bone added to the lower part of the cervix, to support the weakened neck of the bone.

If sections are made transversely of the neck of the thigh-

bone in old persons, the neck of the bone is found so exceedingly spongy, as to be unable to bear even slight concussion.

Fig. 8.

Is a fracture of the neck of the thigh-bone in a person between thirty and forty years of age. The preparation was lent me by Mr. Herbert Mayo.

The bone was shortened an inch only, because a fork in the trochanter minor has caught the neck of the bone, and prevented its further descent. The person lived nine months after the accident; and, notwithstanding the age being favourable, the bones being nearly in apposition, ligamentous union only was produced.

A. Head of the bone
B. Trochanter major
C. Shaft of the bone
D. Fork in the trochanter minor
E. Fracture united by ligament only.

It is curious to observe how little the head of the bone is changed in this fracture after nine months. Any other bones in the body but those forming parts of articulations would be loaded with ossific matter.

PL. XIII.

FIG. 6.

FIG. 4.

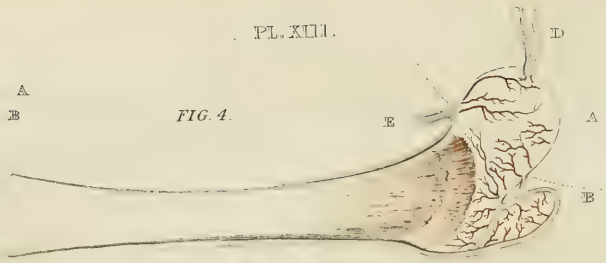

FIG. 5.

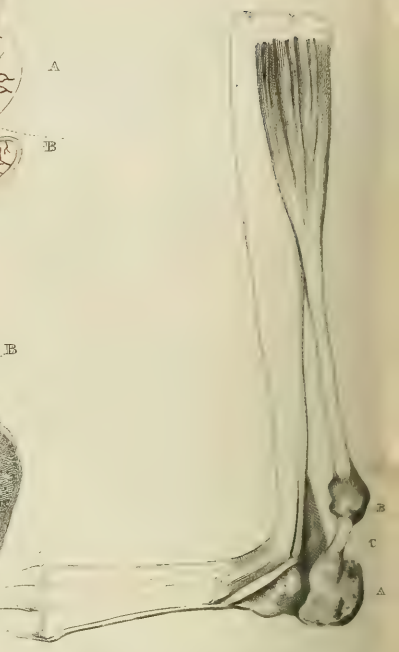

FIG. 1.

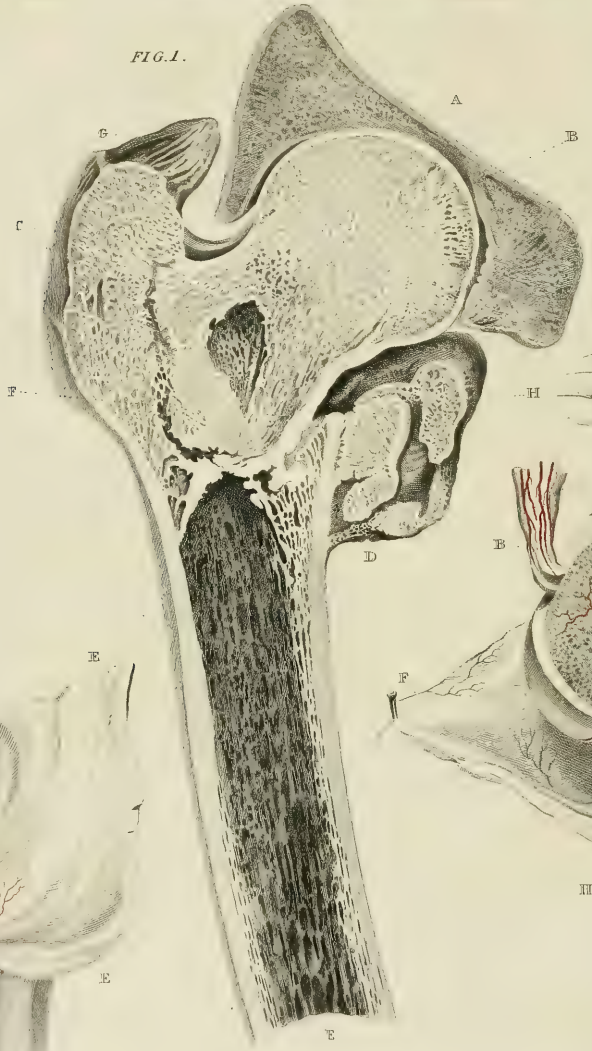

FIG. 2.

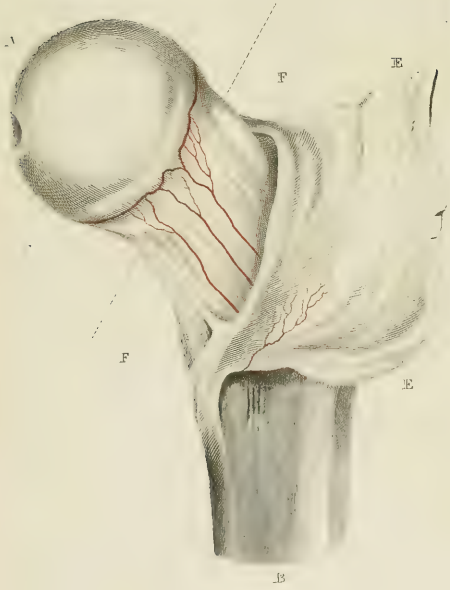

FIG. 3.

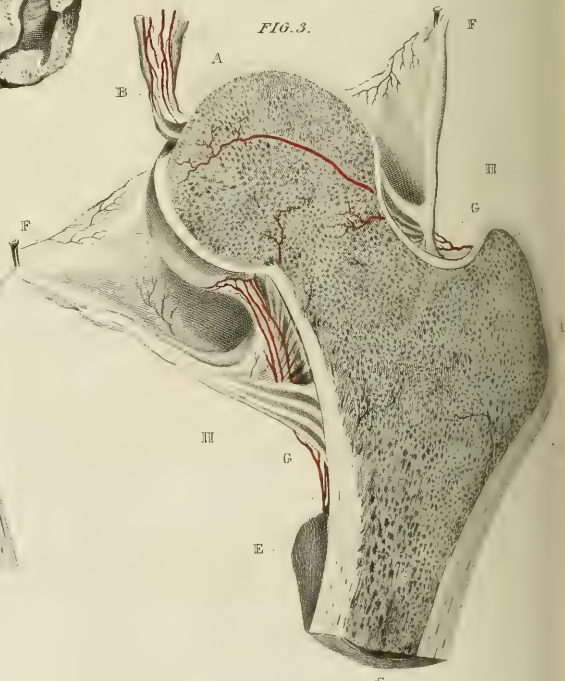

Drawn & Engraved by C. J. Canton.

PLATE XIII.

Fig. 1.

Fracture of the cervix femoris, sent me by Mr. Powell, surgeon, of Coram-street, Brunswick-square, in which the neck of the thigh-bone has been forced into the cancellated structure.

A. Acetabulum
B. Head of the thigh-bone
C. Trochanter major
D. Trochanter minor
E. Shaft of the thigh-bone
F. Neck of the thigh-bone united to the cancelli, into which it had been forced
G. Addition to the trochanter major, which occasionally rested on the ilium
H. Addition to the trochanter minor, which occasionally rested on the left of the acetabulum; and thus the bone became supported by these processes under the weakened state of the cervix.

Fig. 2.

Anatomical view of the head of the thigh-bone and capsular ligament.

A. Head of the thigh-bone
B. Thigh-bone
C. Reflected synovial surface, vessels seen under it

D. Depression for the ligamentum teres

EE. Capsular ligament, and synovial secreting surface

F. Place of reflection of the synovial surface

G. Reflected ligament upon the neck of the bone, which sinks into its pores, and envelopes the neck of the bone as a periosteum; conveying vessels, but differing from periosteum in the strength, arrangement and appearance of its fibrous structure.

Fig. 3.

A. Head of the bone

B. Ligamentum teres

C. Thigh-bone

D. Trochanter major

E. Trochanter minor

F. Capsular ligament

GG. Insertion of the capsular ligament into the bone

H. A band of reflected ligament and synovial secreting surface with its vessels opposite the trochanter minor. Nearer to the bone the reflection of the ligamentous periosteum is seen

H. Another band opposite the trochanter major, the blood-vessels in it

I. The reflected ligament forming a sheath to the bone is seen upon the cervix femoris.

In reviewing what I have written on the structure of the head and neck of the thigh-bone, I fear that some misconception might arise of the passage, page 121, in which I say that the head and neck of the bone are supplied with vessels from the reflected ligament and ligamentum teres. Now I do not mean that this is the only supply, for it is well known that vessels pass through the interior of the neck of the bone; but as these are torn through by the fracture, only those of the untorn reflected ligament and ligamentum teres remain, and it is principally those of which I have given a view in the plate, No. 13. In the fetal bone, in this plate, the interior vessels are slightly tinted.

Fig. 4.

Fætal thigh-bone.

A. Head of the bone
B. Trochanter major
C. Shaft of the bone
D. Ligamentum teres, with its vessels
E. Ossific vessels of the head of the bone.

Fig. 5.

Extremity of the os calcis, cut off and drawn up by the action of the gastrocnemius muscle, in the rabbit.

A. Os calcis

B. Portion of bone detached from it

C. Union by ligament.

Fig. 6.

Longitudinal section of the head of the thigh-bone in a dog, in part within and in part external to the ligament.

A. Head of the bone

B. Portion of the head of the bone broken off longitudinally, and reunited by an ossific process. In this experiment, both the capsular ligament and periosteum afforded nourishment to the bone.

FIG. 1

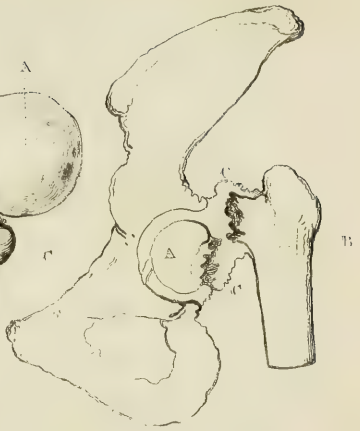

FIG. 2

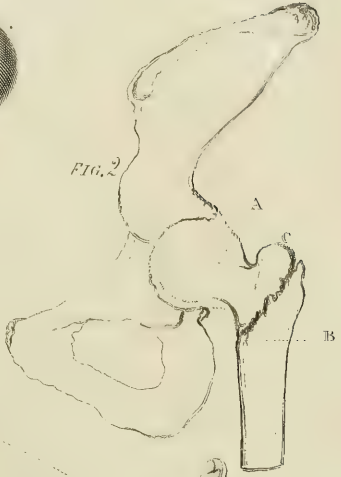

FIG. 3

FIG. 4

FIG. 5

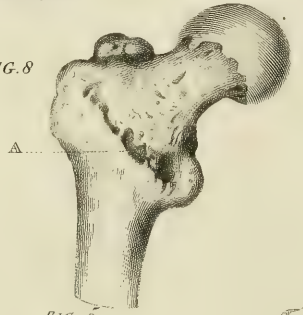

FIG. 6

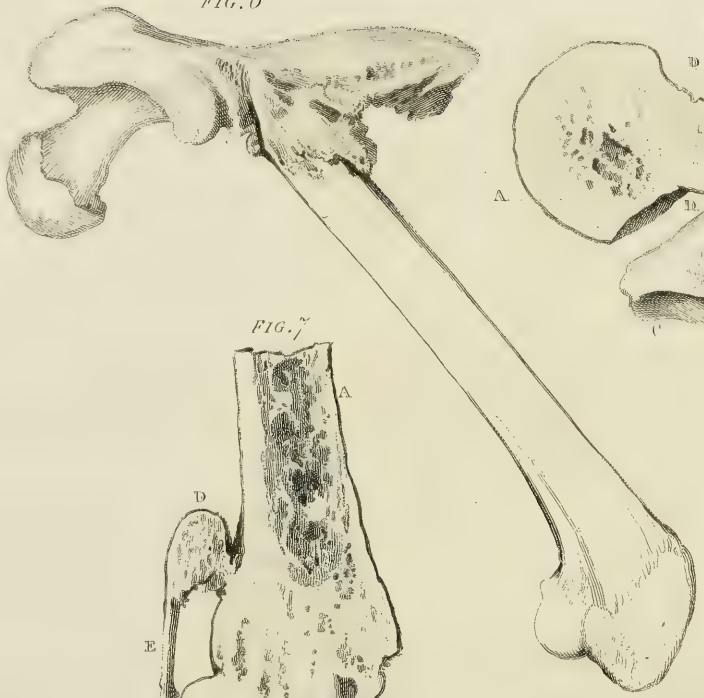

FIG. 7

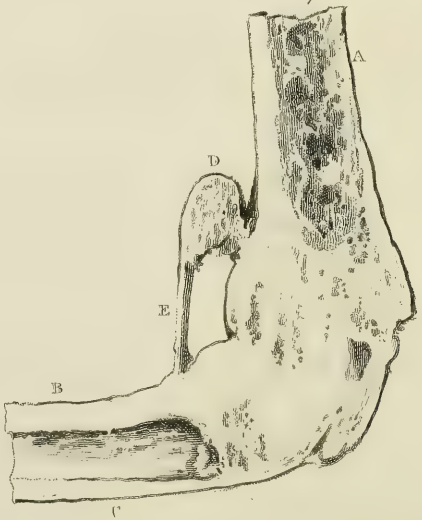

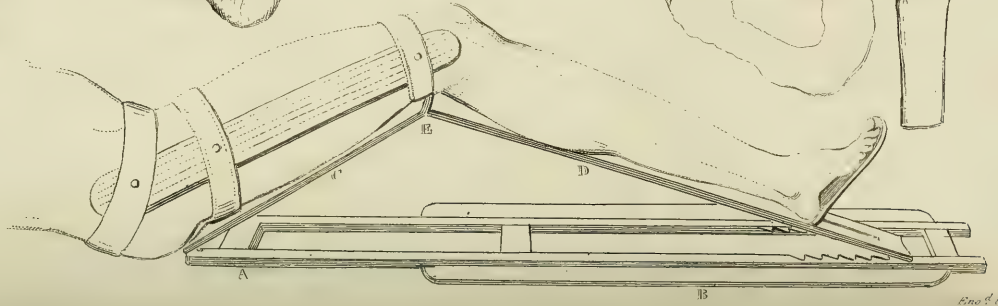

Drawn by H. Thompson.

Engd. by J. Kinnear.

PLATE XIV.

Shews the seat of fracture of the cervix femoris within the capsular ligament.

A. Head of the bone
B. Cervix femoris
C. Capsular ligament.

Fig. 2.

Exhibits the seat of fracture of the trochanter major, often mistaken for fractured cervix femoris. This fracture unites by bone.

A. Head of the bone
B. Shaft of the os femoris
C. Fracture through the trochanter.

Fig. 3.

Fracture of the trochanter, sent me by Mr. Oldknow, of Nottingham.

A. Head of the bone
B. Broken trochanter major
C. Broken trochanter minor
D. Neck of the thigh-bone
E. Shaft of the bone.

Fig. 4.

Shews the bone sent me by Mr. Roux, in which the neck of the os femoris is driven into the cancellated structure of the shaft of the bone, where it unites by means of bone, as in Mr. Powell's case.

Fig. 5.

The inclined plane for simple fracture of the thigh and trochanter major.

A. Frame to rest upon the bed
B. Two lateral supporters to A.
C. The plane for the thigh
D. The plane for the leg
E. The joint.

Two boards, nailed together, with the inclination as described in the plate, answer nearly the same purpose.

Fig. 6.

The thigh-bone fractured below the trochanter minor, and drawn into a most deformed union by the action of the psoas and iliacus internus muscles.

Museum, St. Thomas's Hospital.

Fig. 7.

Dislocation of the knee from ulceration of the ligament, with subsequent anchylosis of the tibia forwards, at right angles with the thigh-bone, and of the patella to the thigh-bone.

A. Shaft of the bone
BC. Tibia projecting forwards, and anchylosed to the os femoris
D. Patella anchylosed
E. Ligamentum patellæ.

Amputated by Mr. Cline.

Museum, St. Thomas's Hospital.

Fig. 8.

Fracture of the human thigh-bone through the trochanter major, in which ossific union has taken place, the fracture being external to the ligament.

A. Fracture.

This case shews the tendency to eversion of the knee and foot in this injury, and the necessity for guarding against it by attention to the position of the foot during the union.

Cooper, 1822

C.J. Cauton

PLATE XV.

The thigh-bone broken just above its condyles and united. Laceration of the rectus muscle, and great overlapping of the bone.

A. Os femoris
B. Tibia
C. Patella
D. Rectus muscle lacerated
EE. Os femoris broken and overlapping, but united
F. Point of the os femoris projecting through the rectus muscle, preventing complete extension, and exceedingly limiting the flexion of the joint.

In Mr. Patey's possession.

PL. XVI.

Fig. 4.

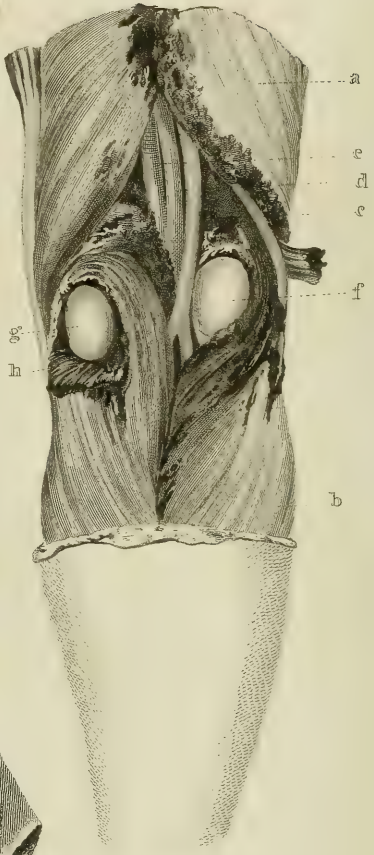

Fig. 2.

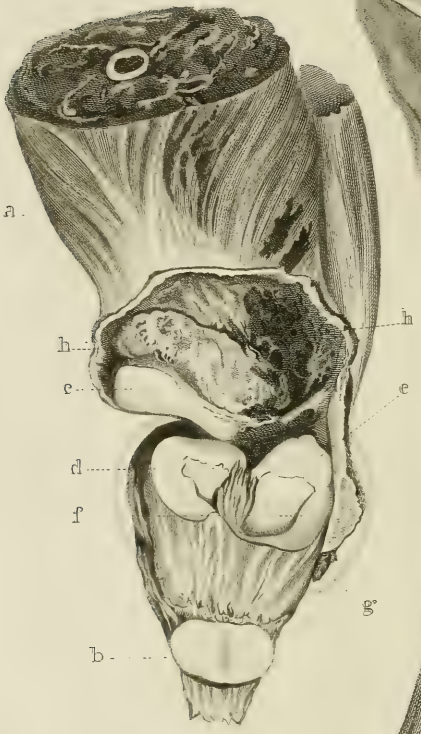

Fig. 1.

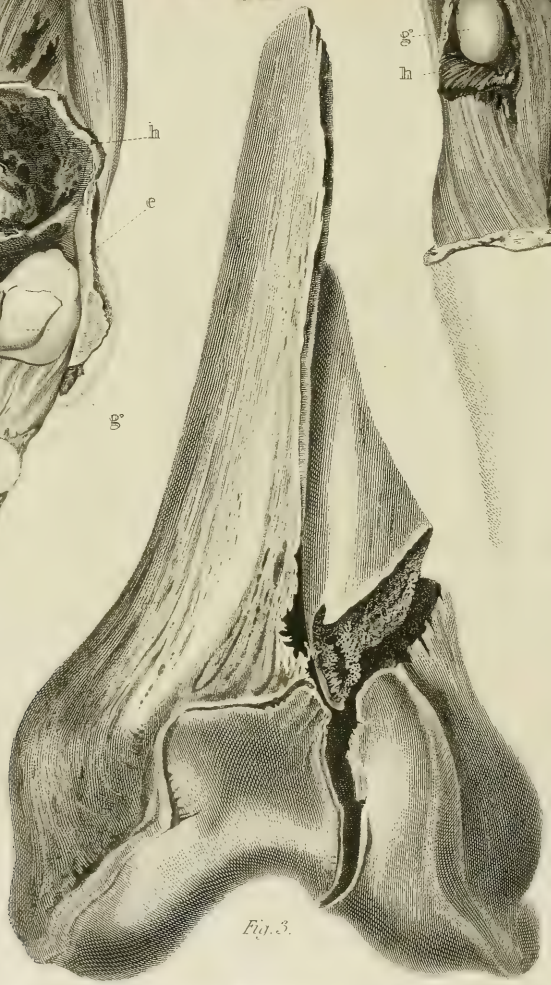

Fig. 3.

PLATE XVI.

Fig. 1.

Shews an anterior view of a dislocation of the thigh at the knee-joint outwards.

A. Muscles of the thigh
B. Patella
C. External condyle of the os femoris, which had pushed through the ligaments and skin
D. One semilunar cartilage
E. The other semilunar cartilage
F. Head of the tibia
G. Leg
HH. Capsular ligament.

Fig. 2.

Posterior view of the same knee.

A. Muscles of the thigh
B. Gastrocnemius
C. Sciatic nerve
D. Popliteal vein
E. Popliteal artery
F. External condyle, which had torn the capsular ligament and muscles posteriorly

G. Internal condyle, which had also torn the ligament and muscles

H. Torn ligaments.

From Mr. Oliver of Brentford.

Fig. 3.

Shews the thigh-bone in a compound fracture at its condyles into the knee-joint.

Museum, St. Thomas's Hospital.

Fig. 4.

Longitudinal fracture of the patella, in which the separation of the bone is very slight, yet it is united by ligament only.

A. Tendon of the rectus femoris

B. Ligamentum patellæ

C. Patella

D. Ligamentous union.

Drawn by Mr. Sylvester.

Museum, St. Thomas's Hospital.

FIG. 1.

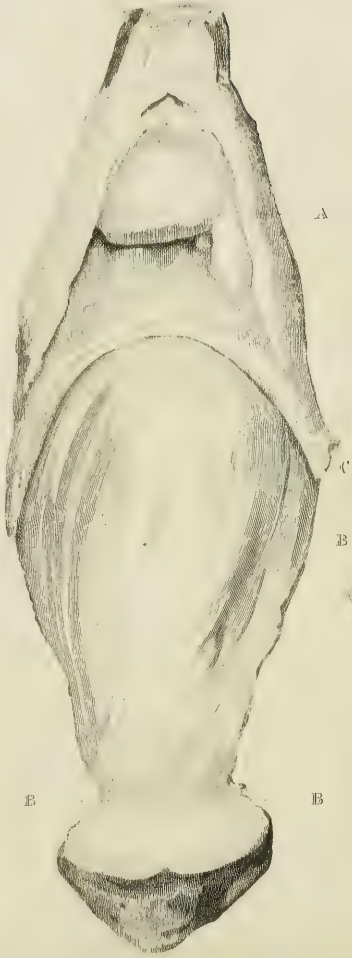

FIG. 2

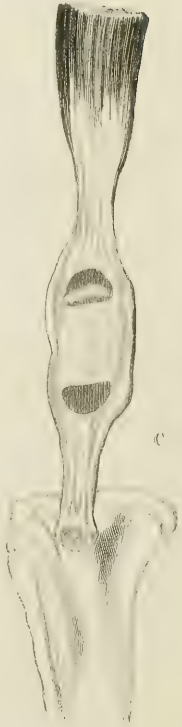

FIG. 6.

FIG 3

FIG 4.

FIG. 5.

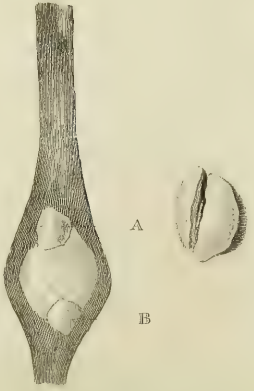

FIG. 7

PLATE XVII.

Different views of fracture of the patella.

Fig. 1.

Fracture of the patella, with ligamentous union and great separation of the bone.

The extent of separation depends upon the degree of laceration of the capsular ligament, and of the tendons of the vasti muscles which are spread over it.

A. Upper portion of the patella drawn up by the action of the rectus and vasti
B. Lower portion of the bone
C. to A. Original ligament
C. to B. New ligament, which, from its length, excessively diminished the power of the extensor muscles.

Fig. 2.

Patella of a dog broken and united by ligament.

Fig. 3.

Patella of a rabbit broken.

A. Coagulated blood between the bones.

Fig. 4.

Patella of a rabbit broken.

A. The blood absorbed, and adhesive matter in its stead.

Fig. 5.

Patella of the rabbit broken and united by ligament; from A. to B.

Fig. 6.

Longitudinal fracture of the patella in the dog.

A. One portion
B. The other.

Ligament seen between the two.

Fig. 7.

Patella broken longitudinally, so that there is no separation, and it is united by bone.

A. Rectus muscle
B. Ligamentum patellæ
C. Longitudinal fracture united.

By its side is seen the patella separated and macerated, and there was slight ossific union.

All in the Museum, St. Thomas's Hospital.

PL. XVIII.

FIG. 1

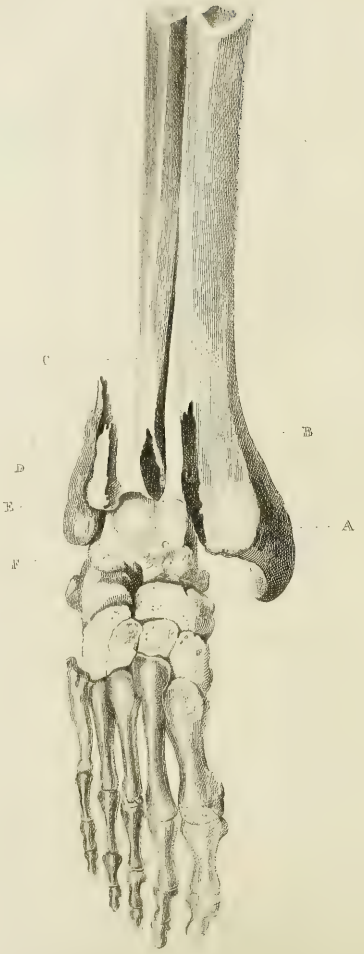

FIG. 4.



FIG. 3.

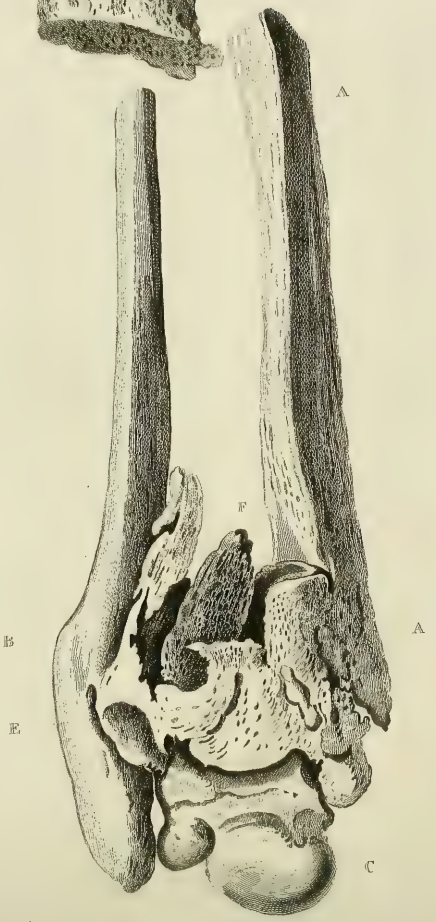

FIG. 2

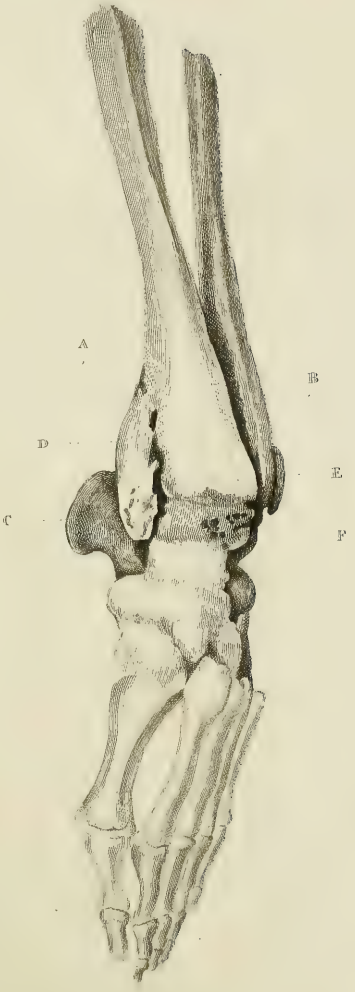

Published by Astley Cooper, 1822

PLATE XVIII.

Fig. 1.

Shews the dislocation of the tibia inwards at the ancle-joint.

A. Malleolus internus of the tibia thrown on the inner side of the astragalus
B. A portion of the tibia split off
C. Fibula broken
D. Broken portion of the tibia adhering by ligament to the fibula
E. Malleolus externus of the fibula, with the broken portion of the tibia adhering to it
F. Astragalus thrown outwards.

Museum, St. Thomas's Hospital.

Fig. 2.

Shews the dislocation of the tibia outwards at the ancle-joint.

A. Tibia
B. Fibula
C. Os calcis
D. Fracture of the tibia at the malleolus internus, which has become reunited

E. Extremity of the fibula broken

F. Tibia thrown on the outer side of the articulatory surface of the astragalus, to which it is anchylosed.

Museum, St. Thomas's Hospital.

Fig. 3.

Shews a fracture of the tibia and fibula at the ancle-joint, sent to me by my friend, Mr. Hammick, Surgeon of the Plymouth Naval Hospital.

A. Tibia fractured

B. Fracture of the fibula

C. Astragalus

E. Shell of the bone surrounding a fragment of bone, and so completely enclosing it that it could not be removed, and amputation became necessary.

Fig. 4.

The fragment of bone seen separately.

FIG. 1.

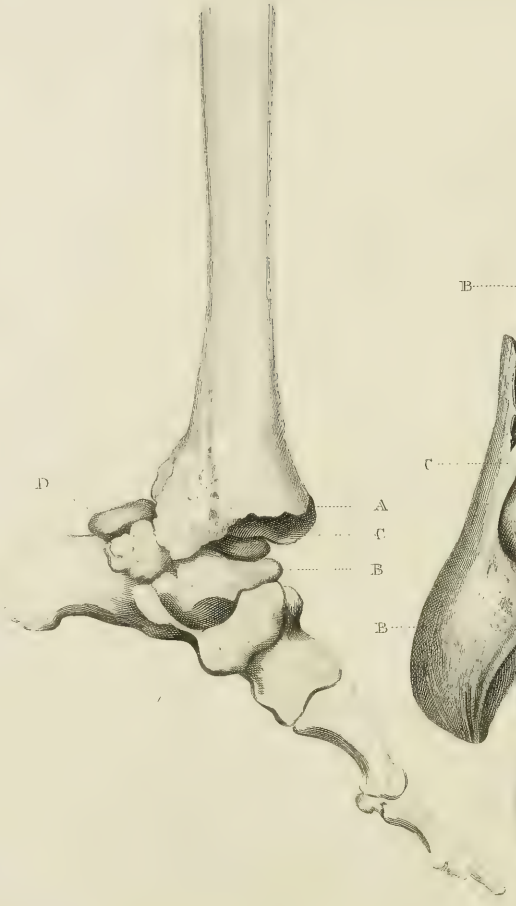

FIG. 3.

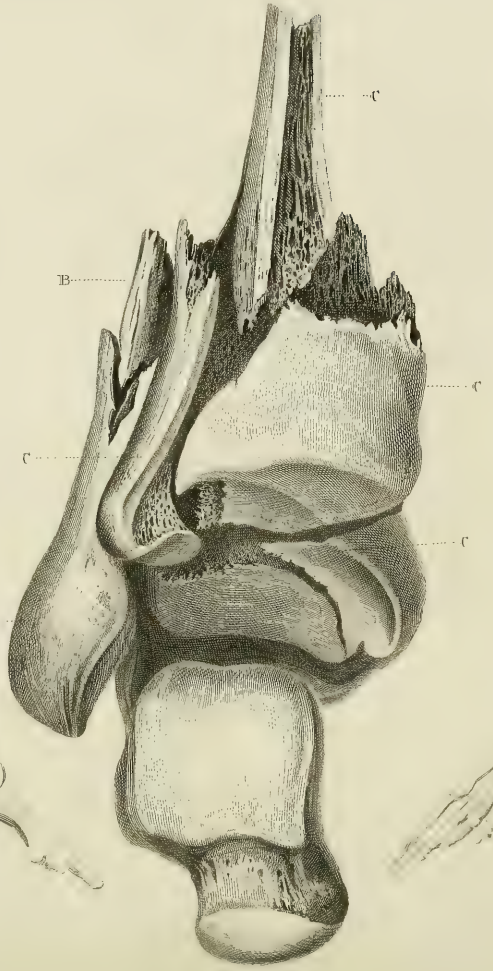

FIG. 2.

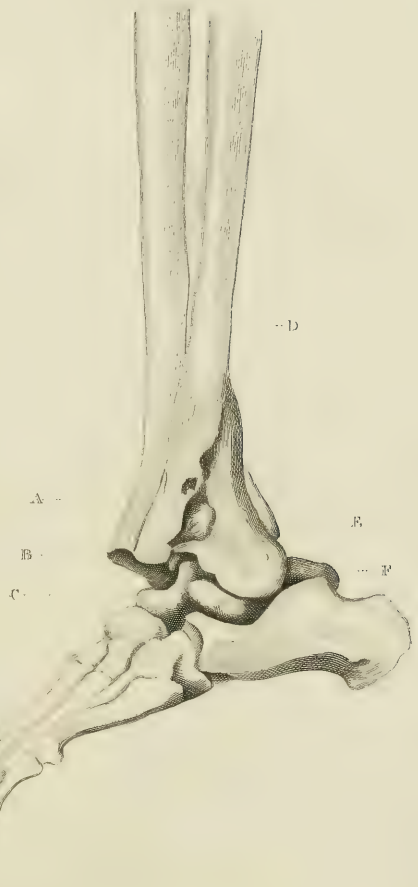

Published by Astley Cooper, 1822

PLATE XIX.

Partial dislocation of the tibia forwards, at the ancle-joint.

Fig. 1.

A. The tibia thrown forward over the os naviculare
B. The astragalus
C. New articulatory surface of the tibia
D. The portion of the astragalus behind the tibia.

Fig. 2.

Opposite view of fig. 1.

A. The tibia thrown forwards
B. New articulatory surface of the tibia
C. Astragalus
D. Fibula broken and reunited
E. Malleolus externus of the fibula
F. Astragalus behind the tibia.

Fig. 3.

Comminuted fracture of the tibia at the ancle-joint, which rendered amputation necessary.

A. Astragalus
BB. Fibula fractured
CC. Tibia shattered into the joint.

PL. XX.

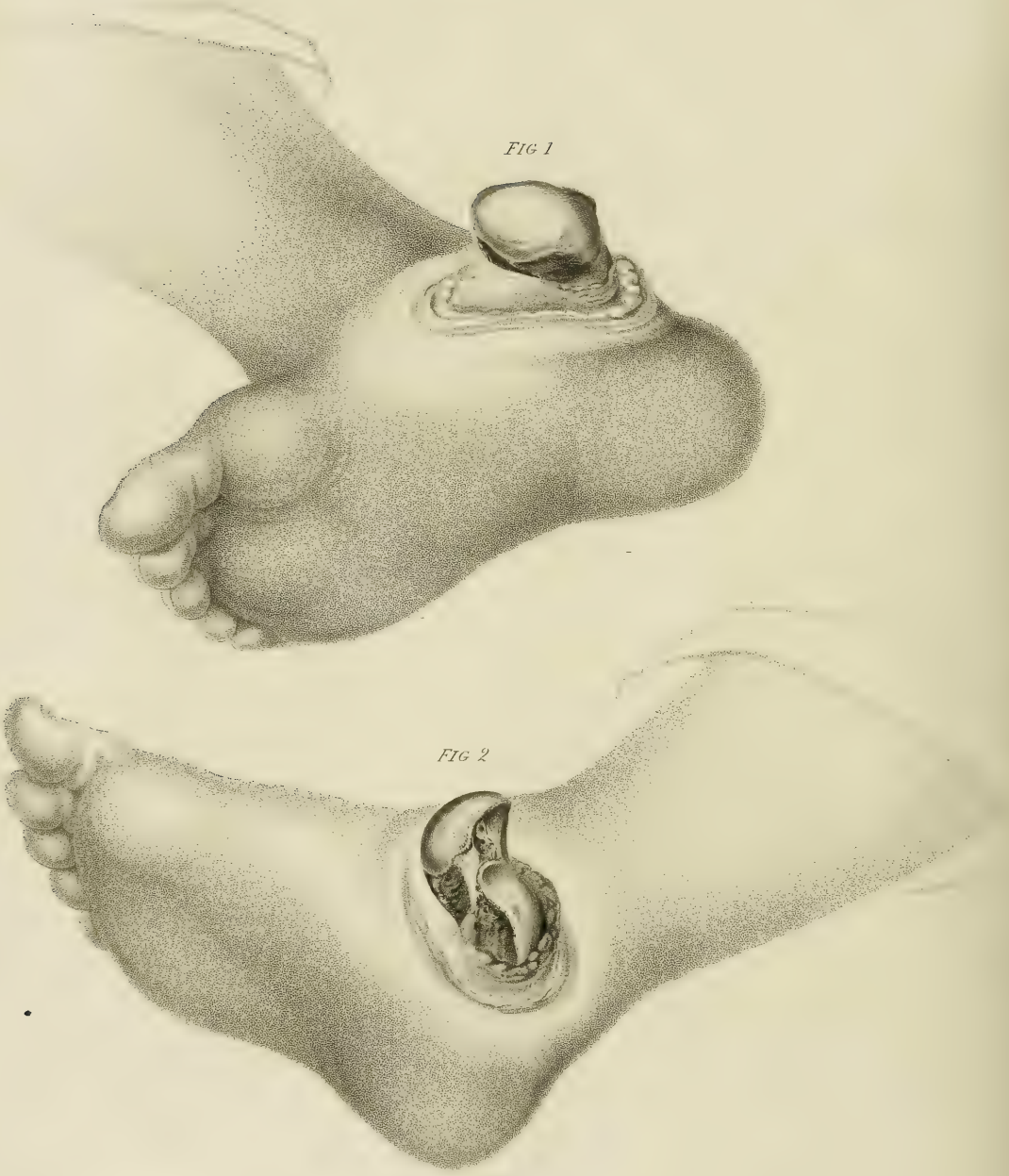

Drawn & Engraved by J. Sutton

Published by Arthur Cooper Sc.

PLATE XX.

Two views of dislocation of the astragalus, in the case of Mr. Downes, in whom the astragalus sloughed away. The drawing was made when the bone began to loosen.

PL. XXI.

PLATE XXI.

Dislocation of the os humeri in the axilla, as it appears in the first dissection of the parts.

A. Clavicle
B. Scapula
C. Os humeri, with the biceps before, and triceps behind, the bone
D. Subscapularis
E. Teres major
F. Latissimus dorsi
G. Pectoralis major
H. Nerves of the axillary plexus and axillary artery and vein, which are seen cut across at the lower part of the plexus; the cutaneous nerve seen passing through the coraco brachialis muscle
I. Coracoid process
K. Head of the bone dislocated in the axilla
L. Capsular ligament and tendon of the subscapularis muscle torn, through which laceration the head of the bone escaped from the glenoid cavity.

FIG. 2

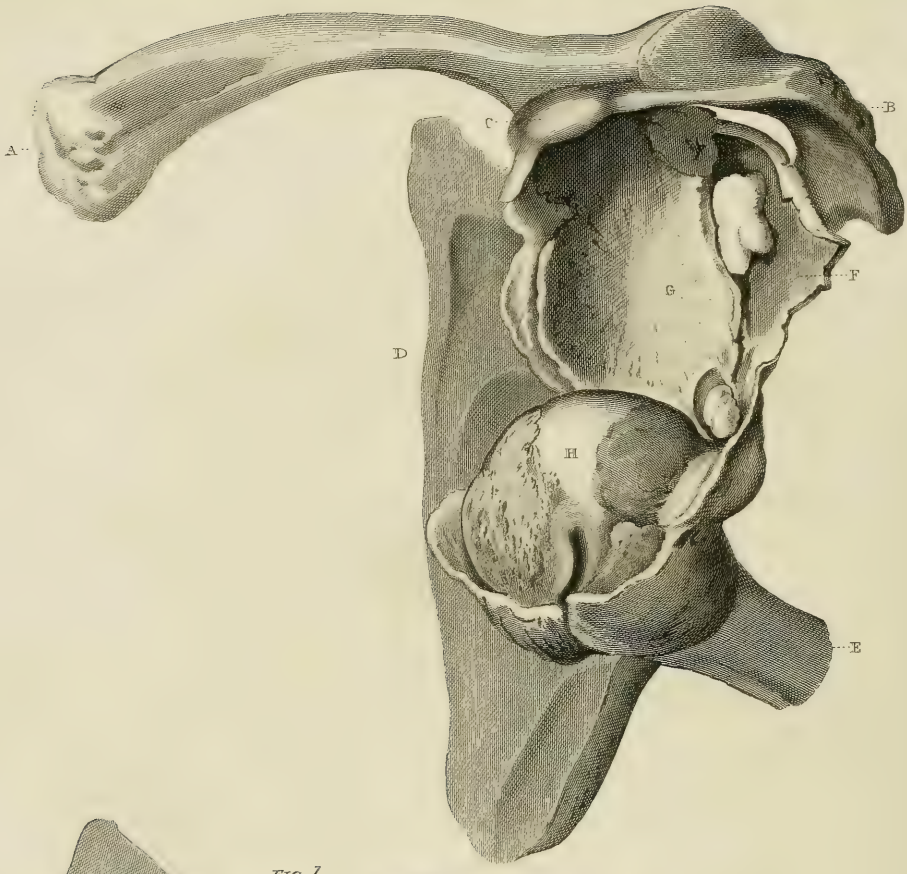

FIG. 1

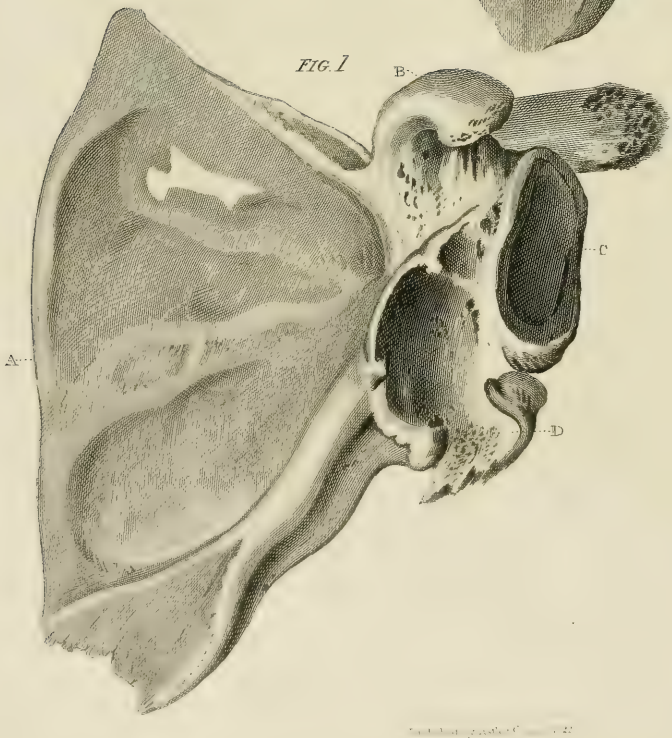

PLATE XXII.

Fig. 1.

Shews the new socket which has been formed on the inner side of the inferior costa of the scapula, in a dislocation of the os humeri into the axilla.

A. The scapula
B. The coracoid process of the scapula
C. The glenoid cavity, with the acromion above it
D. The new socket for the head of the os humeri.

Fig. 2.

Partial dislocation of the os humeri forwards. This drawing was made from the dissection of Mr. Patey, in Dorset-street.

A. Clavicle
B. Acromion
C. Coracoid process
D. Scapula
EE. Os humeri; head of the bone somewhat altered
F. Glenoid cavity
G. New smooth cavity for the head of the os humeri, which extended from the edge of the glenoid cavity to the coracoid process of the scapula.

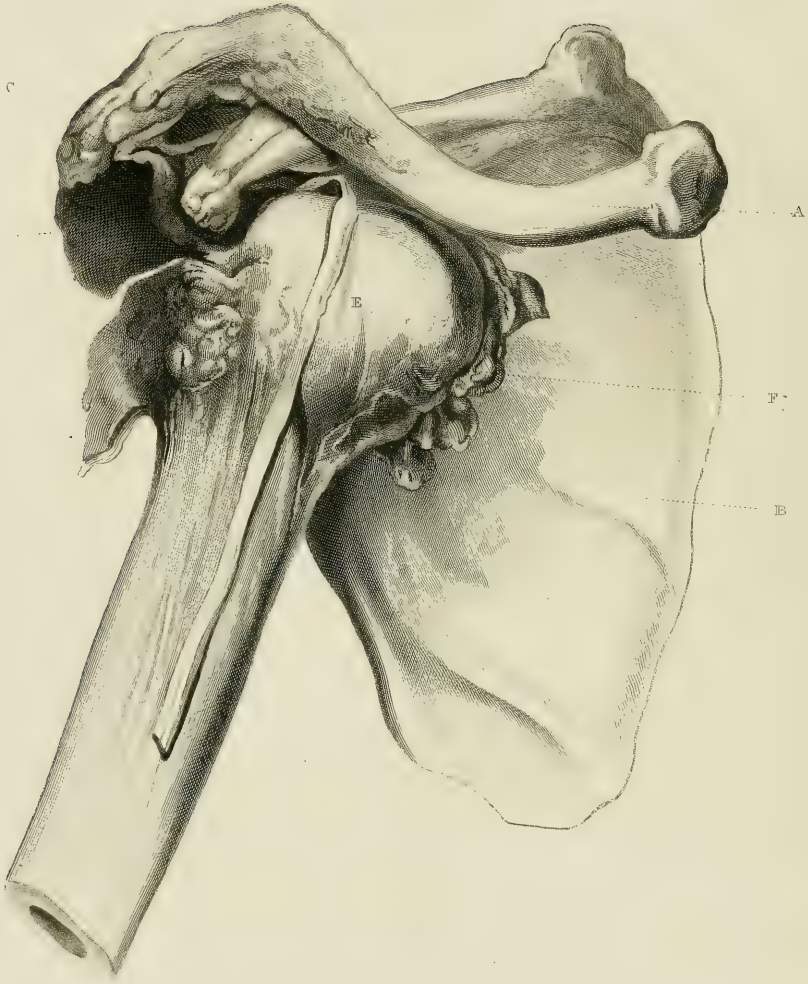

Published by Arch[illegible]

PLATE XXIII.

Fig. 1.

Dislocation of the os humeri forwards, under the clavicle, and behind the pectoral muscle.

A. Clavicle
B. Scapula
C. Acromion
D. Glenoid cavity of the scapula, from which the os humeri had been thrown; and on the inner side of this cavity is seen the coracoid process
E. The head of the os humeri, with the tendon of the biceps passing over it; the head of the bone under the middle of the clavicle, in the centre of the scapula, and on the inner side of the coronoid process
F. Portions of the new ligament, which enclosed the head of the bone

Removed from a patient in St. Thomas's Hospital by Mr. Coleby.

Museum, St. Thomas's Hospital.

FIG. 1

FIG. 2

PLATE XXIV.

Fig. 1.

Shews a dislocation of the os humeri in the axilla.

A. The clavicle

BB. The scapula

C. The os humeri

D. The biceps flexor cubiti

EE. Subscapularis muscle

F. Laceration of the capsular ligament, and of the tendon of the subscapularis

G. Head of the bone thrown on the inner side of the inferior costa of the scapula.

Fig. 2.

Dislocation of the ulna and radius backwards.

A. Os humeri

B. Ulna

C. Radius

D. Biceps flexor cubiti, inserted into the tubercle of the radius

E. Brachialis internus, inserted into the coronoid process of the ulna

F. Triceps extensor cubiti, inserted into the olecranon

G. Internal condyle of the os humeri

H. Olecranon and coronoid process, thrown behind the articulatory surface of the os humeri; the coronoid process is received into the posterior cavity of the humerus.

Museum, St. Thomas's Hospital.

FIG. 3

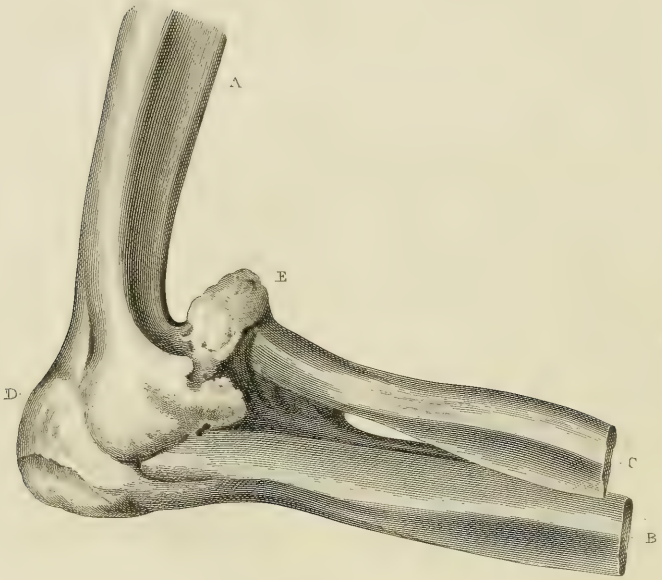

FIG. 1

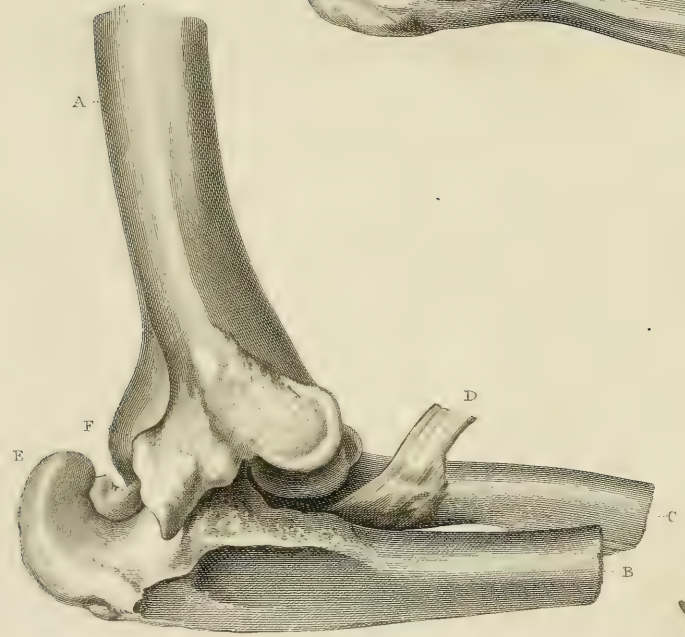

FIG. 2

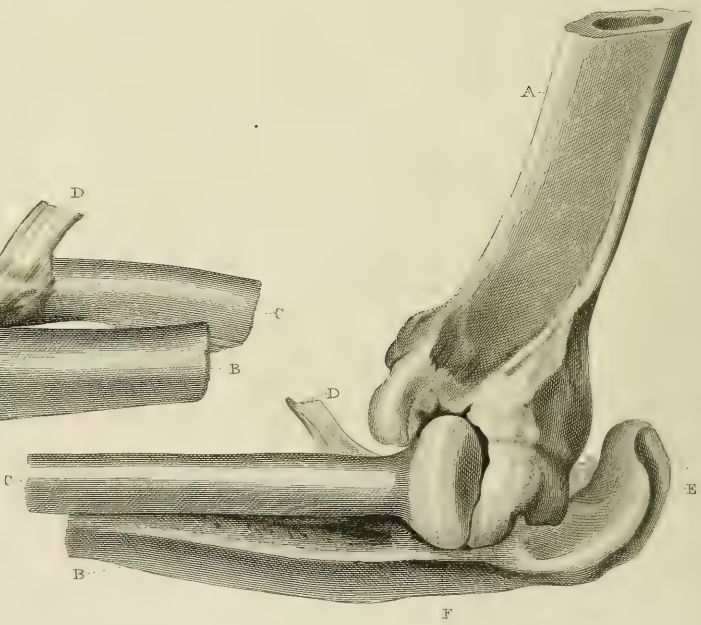

PLATE XXV.

Fig. 1.

A dislocation of the ulna backwards.

A. Os humeri
B. Ulna
C. Radius
D. Insertion of the biceps flexor cubiti into the tubercle of the radius
E. Olecranon thrown behind the os humeri
F. Some appearance of injury to the internal condyle of the os humeri.

Museum, St. Thomas's Hospital.

Fig. 2.

Opposite view of the same preparation.

A. Os humeri
B. Ulna
C. Radius
D. Insertion of the biceps into the tubercle of the radius
E. Olecranon thrown backwards
F. Head of the radius, which, by its pressure against the external condyle of the os humeri, has produced a socket there for itself.

Fig. 3.

Dislocation of the Radius. The bone is thrown upon the external condyle, and upon the coronoid process of the ulna.

A. Os humeri

B. Ulna

C. Radius

D. Olecranon

E. Head of the radius. The coronary ligament and a part of the interosseous ligament is torn through, and the head of the bone is thrown upon the coronoid process of the ulna, and external condyle of the os humeri.

Museum, St. Thomas's Hospital.

PL. XXVI.

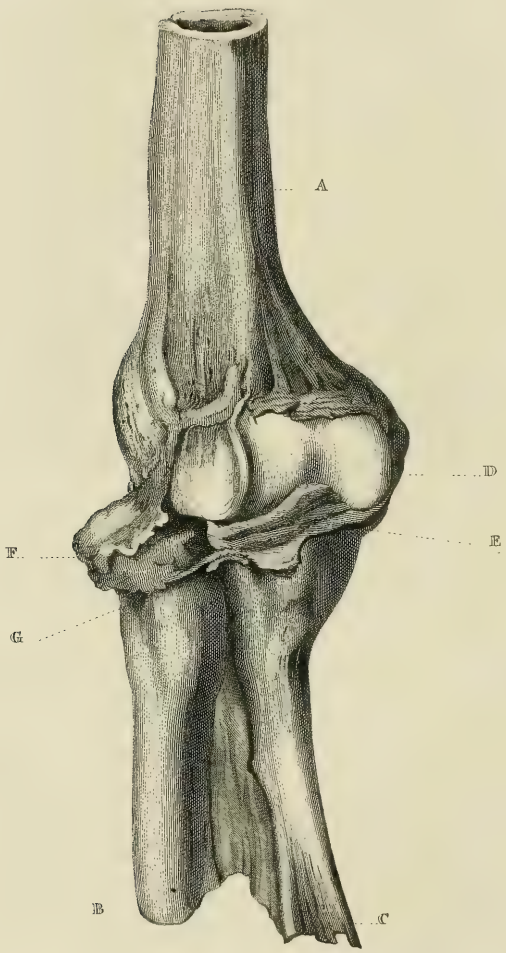

Published by Ashley Cooper &c.

Engraved by C. J. Canton.

PLATE XXVI.

Shews a dislocation of the radius backwards, behind, and to the outer side of the external condyle of the os hum i.

A. Os humeri
B. Radius
C. Ulna
D. Internal condyle of the os humeri
E. Coronoid process of the ulna; the capsular ligament being opened to shew D. and E.
F. The head of the radius dislocated backwards and outwards
G. The coronary ligament torn through.

Given by Mr. Poingdestre. Drawn by Mr. Sylvester.

Museum, St. Thomas's Hospital.

FIG. 3

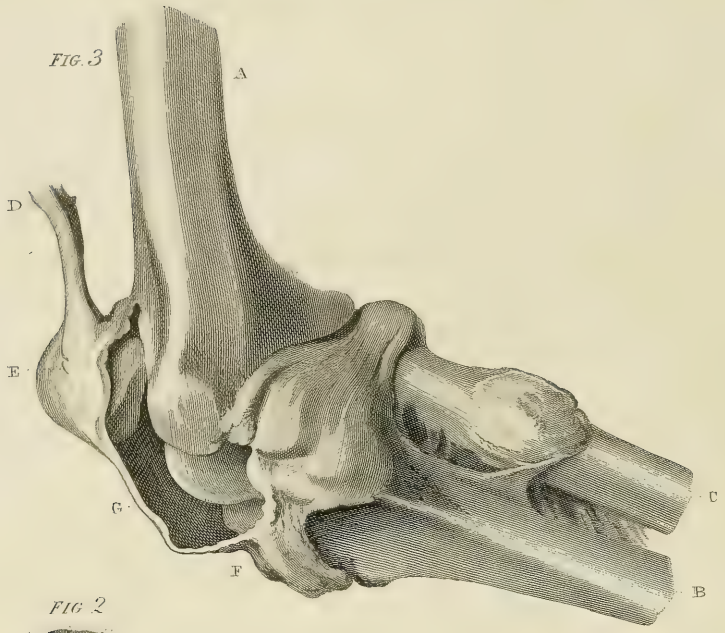

FIG. 2

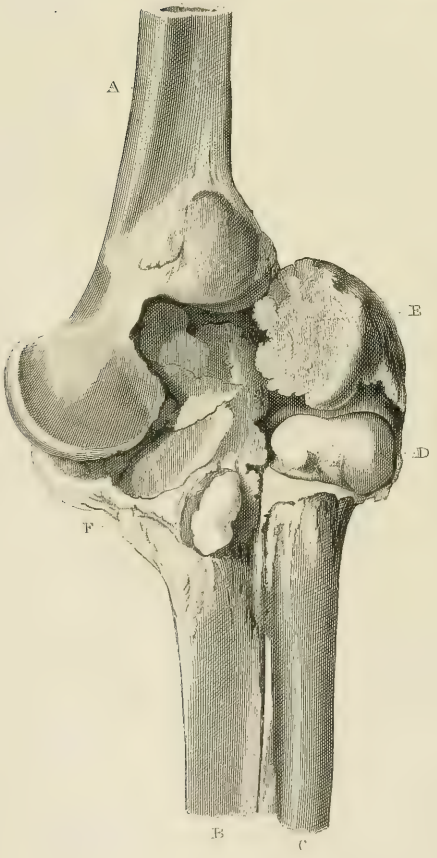

FIG. 1

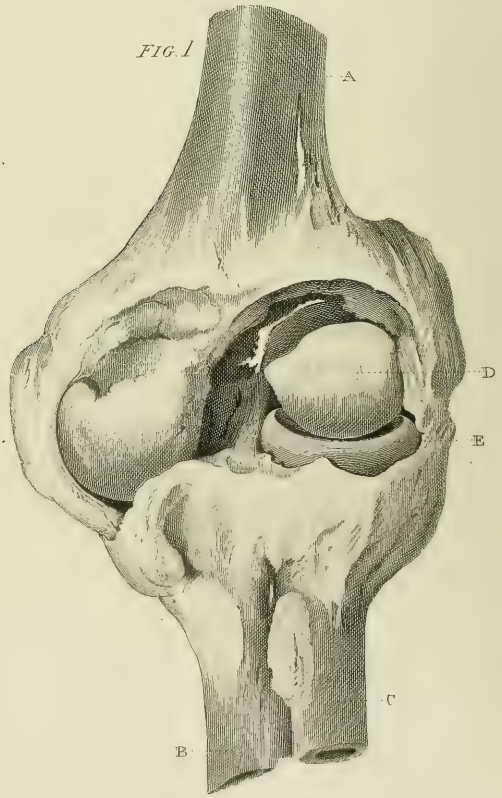

PLATE XXVII.

Fig. 1.

Shews a fracture of the external condyle of the os humeri, still disunited.

A. Os humeri
B. Ulna
C. Radius
D. Fractured external condyle within the ligament; no attempt made to unite it; the broken portion unaltered
E. Head of the radius

Museum, St. Thomas's Hospital.

Fig. 2.

Fracture of the external condyle of the os humeri, and of the coronoid process of the ulna.

A. Os humeri
B. Ulna
C. Radius
D. Head of the radius
E. External condyle fractured externally to the capsular ligaments; great attempts made by nature to unite it, and the form of the bone changed

F. Coronoid process of the ulna broken off, and united by ligament only to the ulna; no attempt made to produce ossific union. This portion of the coronoid process was seated within the capsular ligament.

Museum, St. Thomas's Hospital.

Fig. 3.

Fractured olecranon.

A. Os humeri
B. Ulna
C. Radius
D. A portion of the triceps extensor cubiti
E. Olecranon broken and drawn up by the triceps
F. Shaft of the ulna where the olecranon is broken from it
G. The new ligament, which has joined the olecranon to the ulna.

Museum, St. Thomas's Hospital.

FIG. 3.

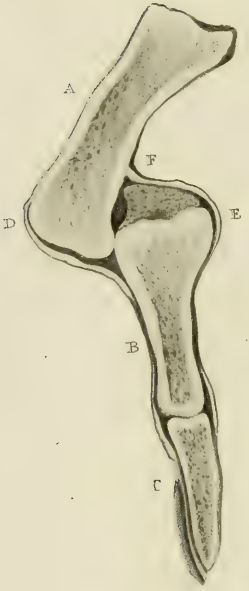

FIG. 4.

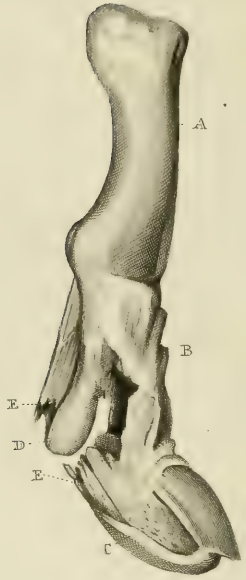

FIG. 2.

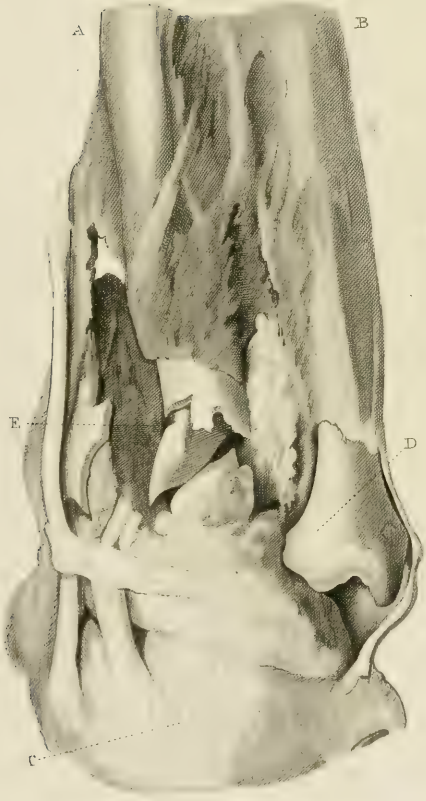

FIG. 1.

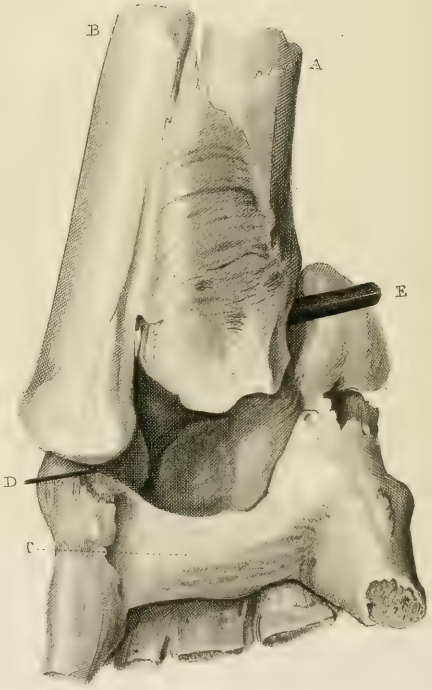

Published as the Act directs 1822

PLATE XXVIII.

Fig. 1.

Shews a fracture of the inferior extremity of the radius, and dislocation of the ulna forwards.

A. Radius
B. Ulna
C. Ligamentum annulare carpi
D. Ulna thrown forwards upon the os orbiculare
E. Broken extremity of the radius: the shaft of the bone thrown forwards, and the lower extremity of the bone remaining in its natural situation. On the shaft of the bone, just above the fracture, is seen the attachment of the pronater quadratus.

Museum, St. Thomas's Hospital.

Fig. 2.

Shews a compound dislocation of the ulna backwards, with a compound and comminuted fracture of the radius.

A. Radius
B. Ulna
C. Carpus
D. Ulna dislocated backwards, being thrown behind the extremity of the radius

E. Fragments of the broken radius extremely comminuted: the tendon of the extensor carpi radialis brevior torn through.

Museum, St. Thomas's Hospital.

Fig. 3.

Dislocation of the second phalanx of the finger forwards, and of the first backwards.

A. First phalanx
B. Second phalanx
C. Third phalanx
D. Dislocated extremity of the first phalanx
E. Dislocated second phalanx
F. New capsular ligament covering the ends of the dislocated bones.

Fig. 4.

Compound dislocation of the first phalanx of the thumb.

A. Metacarpal bone
B. First phalanx thrown backwards
C. Second phalanx
D. First phalanx dislocated
E. Tendon of the flexor longus pollices torn through.

In the treatment of this accident the end of the bone is to be sawn away.

Museum, St. Thomas's Hospital.

PL. XXVIII.

FIG. 1.

FIG. 2.



FIG. 5.

FIG. 3.

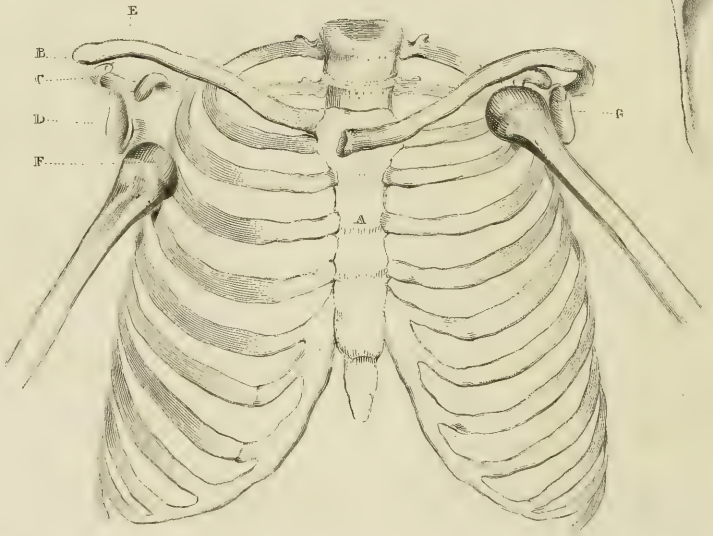

FIG. 4.

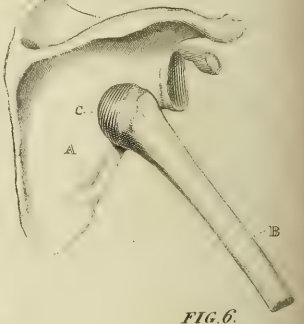

FIG. 6.

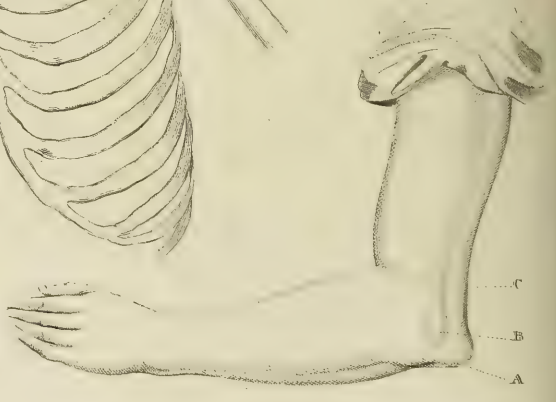

Published by Astley Cooper 1822.

Drawn & Engraved by C. J. Canton.

PLATE XXIX.

Fig. 1.

Shews a view of a dislocation of the os humeri into the axilla on the right side.

Fig. 2.

Is a view of the dislocation of the os humeri forwards, behind the pectoralis major, and under the clavicle.

Fig. 3.

The bones of the trunk, shewing the seats of dislocation of the clavicle and os humeri.

A. Sternal end of the clavicle thrown upon the sternum
B. Scapular end of the clavicle thrown upon the spine of the scapular
C. Spine of the scapular
D. The glenoid cavity
E. Coracoid process
F. Head of the os humeri thrown into the axilla
G. Head of the os humeri thrown forwards upon the second rib under the clavicle, and upon the inner side of the coracoid process in the dislocation forwards.

Fig. 4.

Shews the situation of the head of the os humeri, when dislocated backwards upon the scapulæ.

A. Dorsum scapulæ
B. Os humeri
C. Head of the os humeri on the dorsum scapulæ.

Fig. 5.

Shews a dislocation of the astragalus outwards.

A. Malleolus externus
B. Astragalus thrown outwards: the foot resting upon its outer edge.

Fig. 6.

A. Ulna thrown back
B. Radius thrown with the ulna
C. Hollow above the elbow.

PLATE XXX.

Fig. 1.

Shews the mode which I almost constantly pursue of reducing recent dislocations of the os humeri, by placing the heel in the axilla, and by extending the arm either from above the elbow or from the wrist.

Fig. 2.

Mode of reduction by the pulley; shewing the manner in which the scapula is fixed by a bandage which receives the arm, and the pullies applied above the elbow; as well as the direction in which extension is to be made in dislocation in the axilla. If the dislocation be forwards under the clavicle, the arm must be somewhat lowered to avoid the coracoid process.

Fig. 3.

Shews the mode of reducing the dislocation downwards, by the knee in the axilla.

PL. XXXI.

1

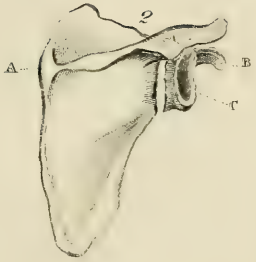

2

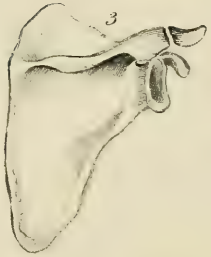
3

4

5

6


7


8

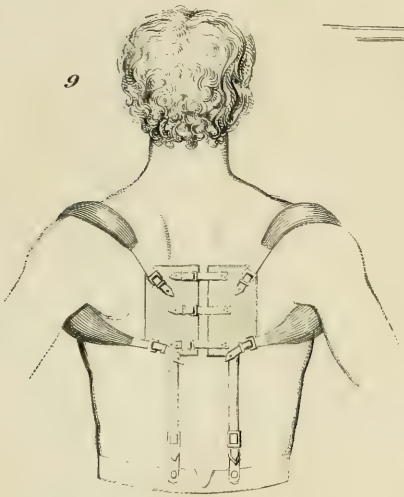
9

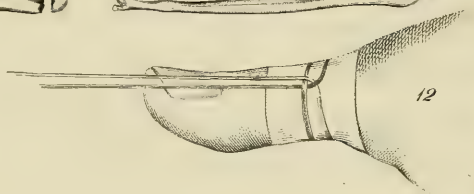
12

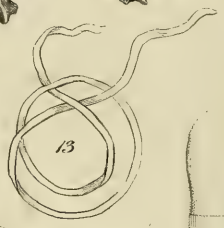
13

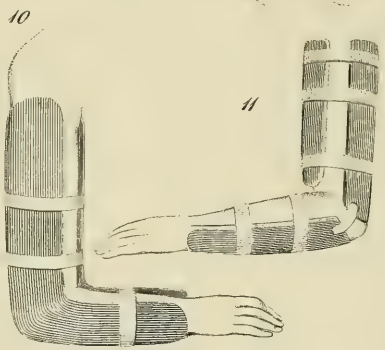
10
11

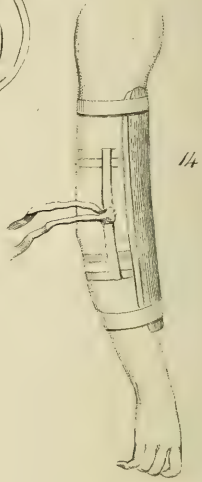
14

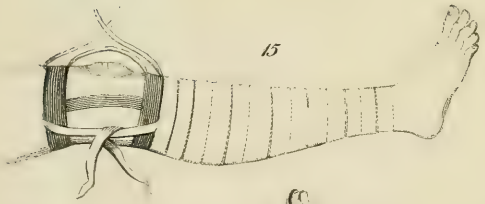
15

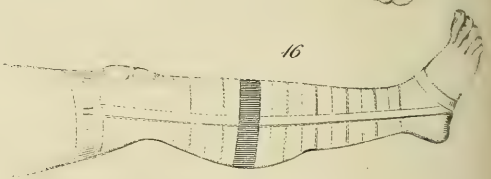
16

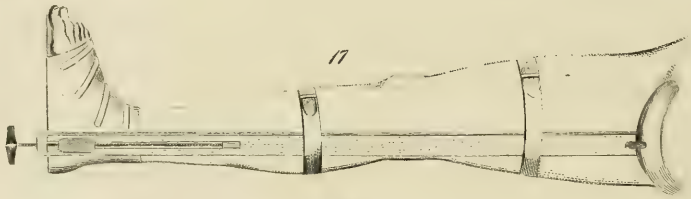
17

18

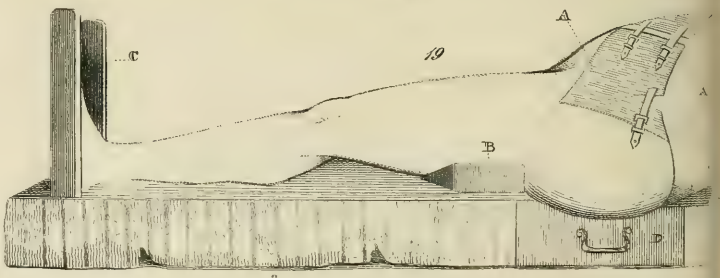

Published by Astley Cooper. 1822.

PLATE XXXI.

Fig. 1.

Shews an altered state of the neck of the thigh-bone from disease, which might be mistaken for fracture and union. The same appearance, in a less degree, is sometimes seen in the upper part of the thigh-bone in very old persons; the head and neck of the bone falling down upon its shaft at the trochanter minor, and the neck of the bone absorbed.

Fig. 2.

Fracture of the cervix scapulæ.

A. Spine of the scapula
B. Coracoid process
C. Glenoid cavity broken off by a fracture through the neck of the scapula.

Fig. 3. Fracture of the acromion.
—— 4. Fracture of the cervix humeri.
—— 5. Fracture of the internal condyle of the os humeri.
—— 6. Fracture of the external condyle of the os humeri.
—— 7. Fracture of the olecranon.
—— 8. Fracture of the coronoid process of the ulna.

Fig. 9. Clavicle bandage, with the pads under the axilla, to throw the head of the os humeri from the side; used in fractured clavicle; in dislocations of that bone; and in fracture of the cervix scapulæ.

—— 10. Lateral splints for fractures of the elbow-joint.

—— 11. Back splint for the arm, with the hinge at the elbow, for fractures of the condyles when requiring motion.

—— 12. Mode of reduction of the thumb.

—— 13. Loop used for the foregoing purpose, called by sailors the *clove hitch*, composed of two circles, with the ends between them.

—— 14. Bandage for the fracture of the olecranon.

—— 15. Common mode of bandaging for the fractured patella.

—— 16. Leathern strap buckled above the patella, with another strap passing under the foot, which I employ for fractured patella.

—— 17. Long splint for fractured thighs. Its upper part rests against the pubes, and is buckled around the upper part of the thigh. The splint passing down on the inner side of the thigh and leg, with a screw to add to its length, and a boot attached to it to confine the splint to the foot.

Fig. 18. Splint, with a foot-piece on each side, for dislocations and fractures at and near to the ancle-joint.

Fig. 19.

Bandage used in the case, related by Mr. Harris, of Reading, of injury to the upper part of the thigh-bone.

A. A pad buckled around the pelvis, to support the trochanter
B. Wedge to support the thigh-bone
C. Foot supporter
D. Portion of the mattress which drew out to slide a bed-pan under the patient.

PLATE XXXII.

Fig. 1.

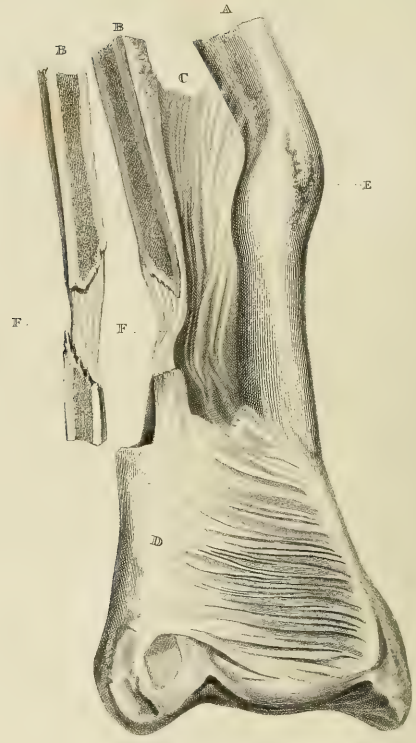

Fig. 3.

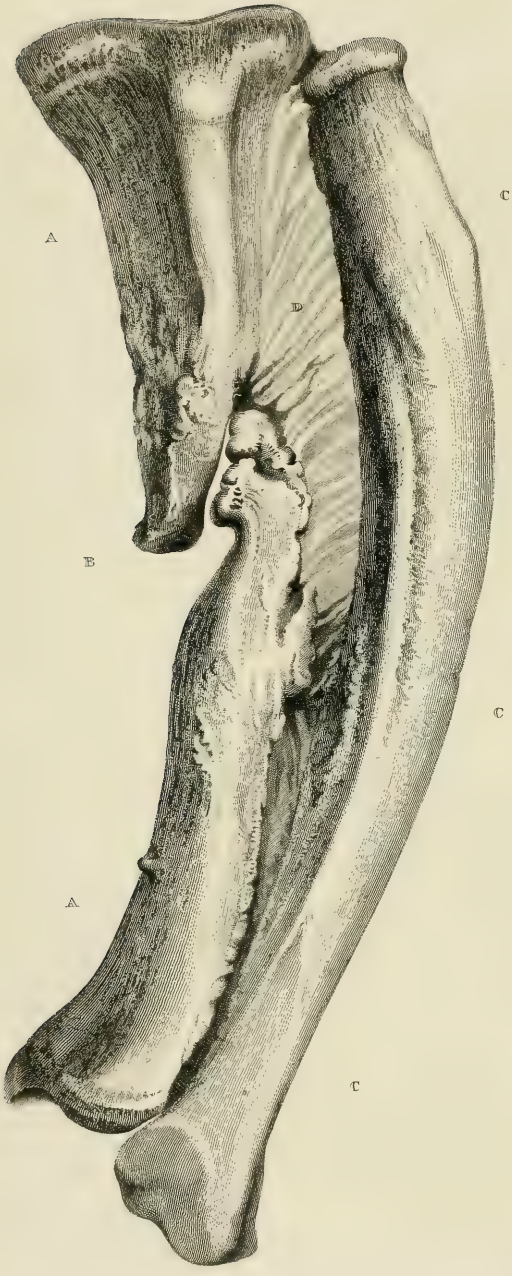

Fig. 2.

Drawn & Engraved by C. J. Canton.

Published by Astley Cooper, 1824.

PLATE XXXII.

Fig. 1.

Shews the union of the radius after fracture, and a ligamentous union of the ulna. Mr. Cline used to attribute the want of union, in such cases, to the muscles drawing the bones from each other, hence the pronator quadratus would produce this effect; in the os humeri, the coraco brachialis would, in a similar manner, prevent union. Whatever prevents pressure of one bone against the other, will have a tendency to produce that effect. Want of pressure is one principle of nonunion.

A. Radius
BB. Section of the ulna
C. Interosseous ligament
D. Pronator quadratus muscle
E. United radius
F. Ulna united by ligament.

Fig. 2.

Fracture of the cranium, and a portion of bone removed by the trephine.

A. Os frontis
B. Parietal bone
C. Large aperture in the skull remaining unfilled, except at its edges, although it had the appearance of being an accident of ancient date.

D. Fracture ununited.

In examining these cases, I have found that the pericranium has been much thickened at the aperture. The dura mater greatly thickened beneath the openings, and a ligamentous substance unites the dura mater to the pericranium. Some ossific matter is added to the edge of the opening in the bone, but unless the opening be small, it is rarely filled by bone.

Fig. 3.

Tibia ununited after fracture; yet in these cases the person walks with a much less halt than would be expected by the surgeon who had not witnessed similar examples.

AA. Tibia

B. Nonunion of the tibia

CCC. Fibula enormously enlarged and curved, so as to bring the foot near to the axis of the body. The upper part of the fibula little less than the tibia

D. Interosseous ligament

A lady from Salisbury, whom I lately saw, walked extremely well across my room, although her tibia was ununited after fracture.

Fig. 1.

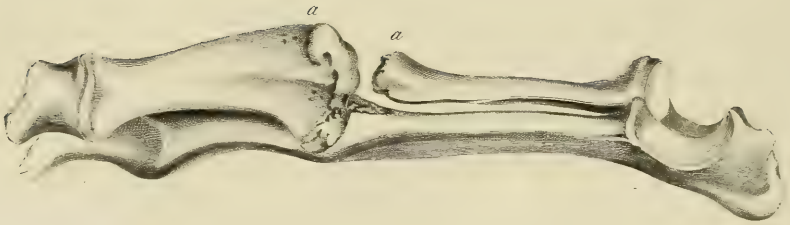

Fig. 2.

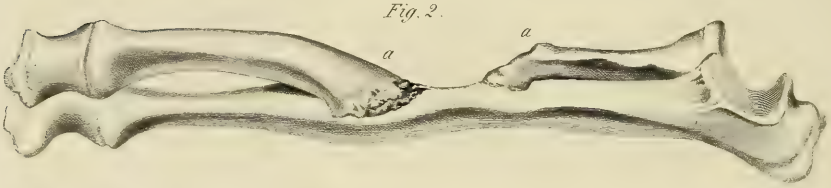

Fig. 3.

Fig. 4.

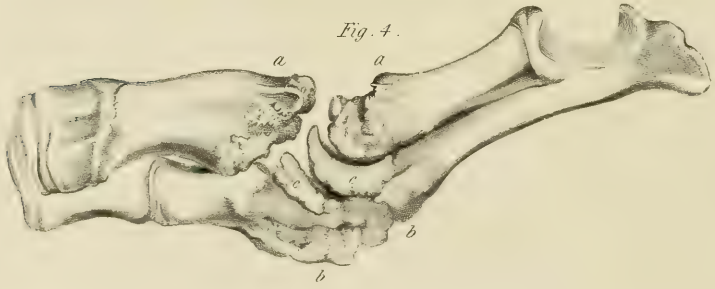

Published by Astley Cooper. 1824.

PLATE XXXIII.

Fig. 1.

Shews the radius of a dog, from which half an inch of bone had been removed. It had not united, but, from the appearance of the callus, probably would have united had the animal lived longer than two months.

AA. Space produced by the removal of the bone.

Fig. 2.

Portion of the radius removed, an inch in length. Mode of union shewn.

AA. Each end of the radius united with the ulna only.

Fig. 3.

Two inches of the radius removed. A ligamentous union of the radius to the ulna was produced, and the ulna was enlarged opposite to the space produced by the removal of the radius.

Fig. 4.

Is a curious result of an experiment in which an inch of bone was removed from the radius, and the ulna was accidentally broken at the time. The radius produced callus,

which did not reach from bone to bone, but the ulna, at its fractured part, sent in two portions of bone to fill the space between the ends of the radius.

A A. Space between the ends of the radius

B B. Fracture of the ulna, with two portions of bone proceeding into the inter-space of the radius.

This experiment explains the cases of apparent union between remote portions of bone, when a piece of the tibia has been removed, and the fibula at the same time fractured: this is fully exemplified in the case published by Mr. Dunn, a very intelligent surgeon at Scarborough, who has had the kindness to send me a cast of the leg of his patient.

PL. XXXIV.

FIG. 1.

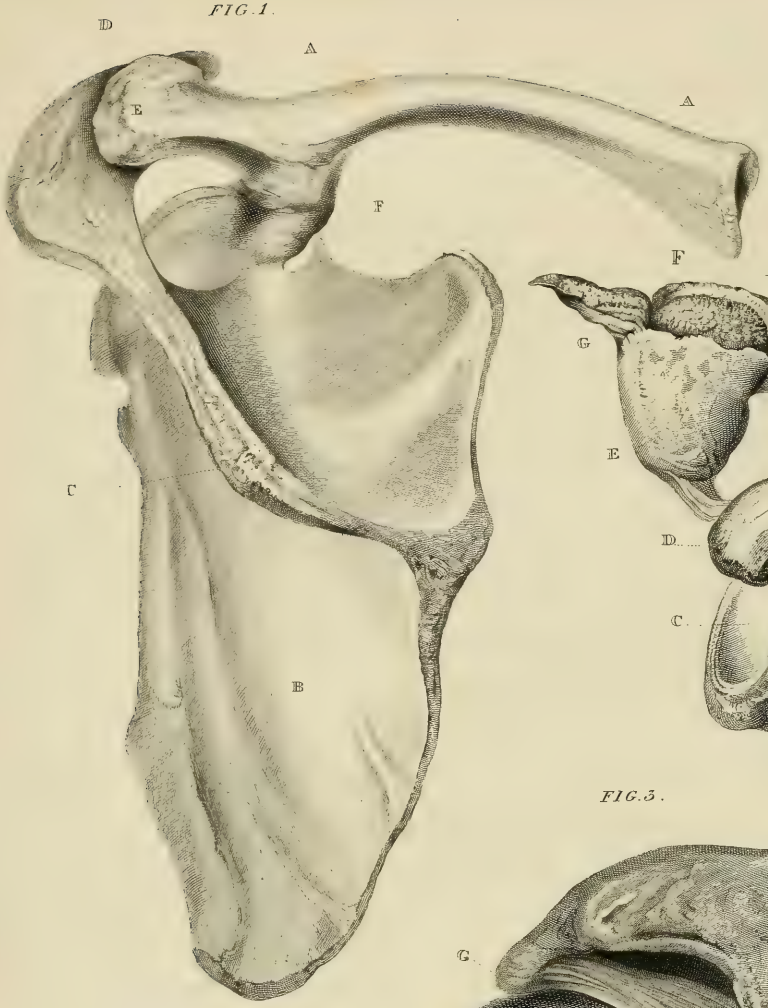

FIG. 4.

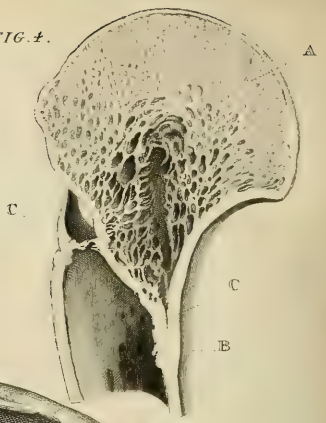

FIG. 2.

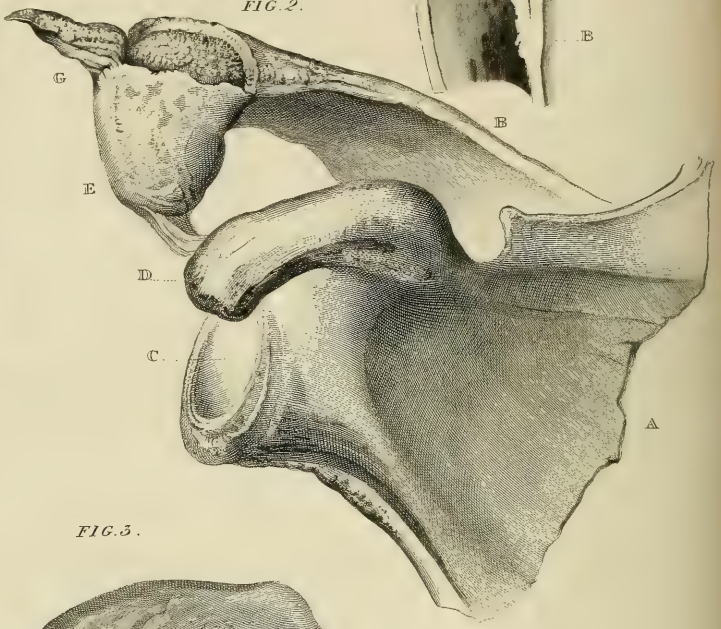

FIG. 3.

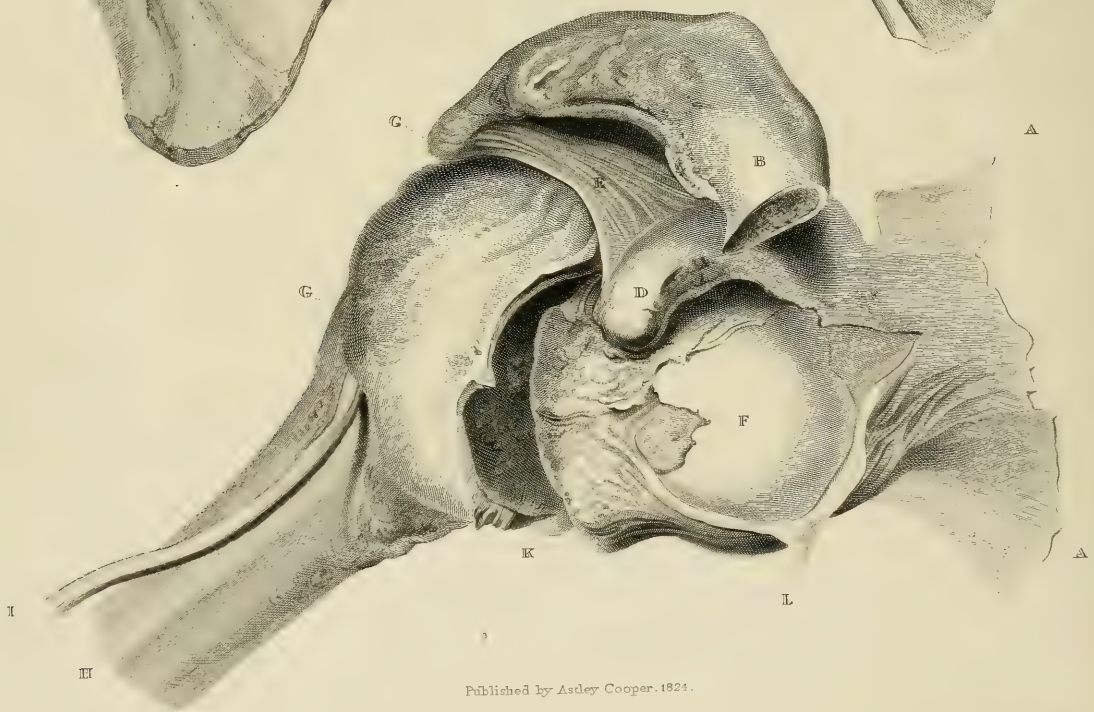

Published by Astley Cooper. 1824.

PLATE XXXIV.

Fig. 1.

Shews a dislocation of the scapular end of the clavicle upon the acromion; the clavicle is seen projecting over the spine of the scapula.

A A. Clavicle
B. Scapula
C. Spine of the scapula
D. Acromion
E. Scapular end of the clavicle thrown over the acromion
F. The conoid ligament almost entirely converted into bone, and anchylosing the clavicle to the scapula.

Fig. 2.

Shews a fracture of the acromion united by ligament.

A. Portion of the scapula
B. Spine of the scapula
C. Glenoid
D. Coracoid process
E. Acromion
F. The fracture of the acromion united at its edge by the ligament
G. Which has been turned aside to shew ligamentous granulations upon the broken surfaces.

Fig. 3.

Is a very curious preparation of dislocation of the os humeri in the axilla, and fracture of the cervix within the capsular ligament, forming there a new joint, the fracture not having united.

AA. Scapula
B. Portion of the clavicle
C. Acromion
D. Coracoid process of the scapula
E. Acromio coracoid ligament
F. Head of the os humeri dislocated
G. Tubercles of the os humeri
H. Os humeri
I. Tendon of the biceps
K. The new joint from the fracture.

Fig. 4.

Fracture of the os humeri below the capsular ligament united.

A. Head of the os humeri
B. Os humeri
CC. Fracture united.

F. WARR, PRINTER, RED LION PASSAGE, HOLBORN.
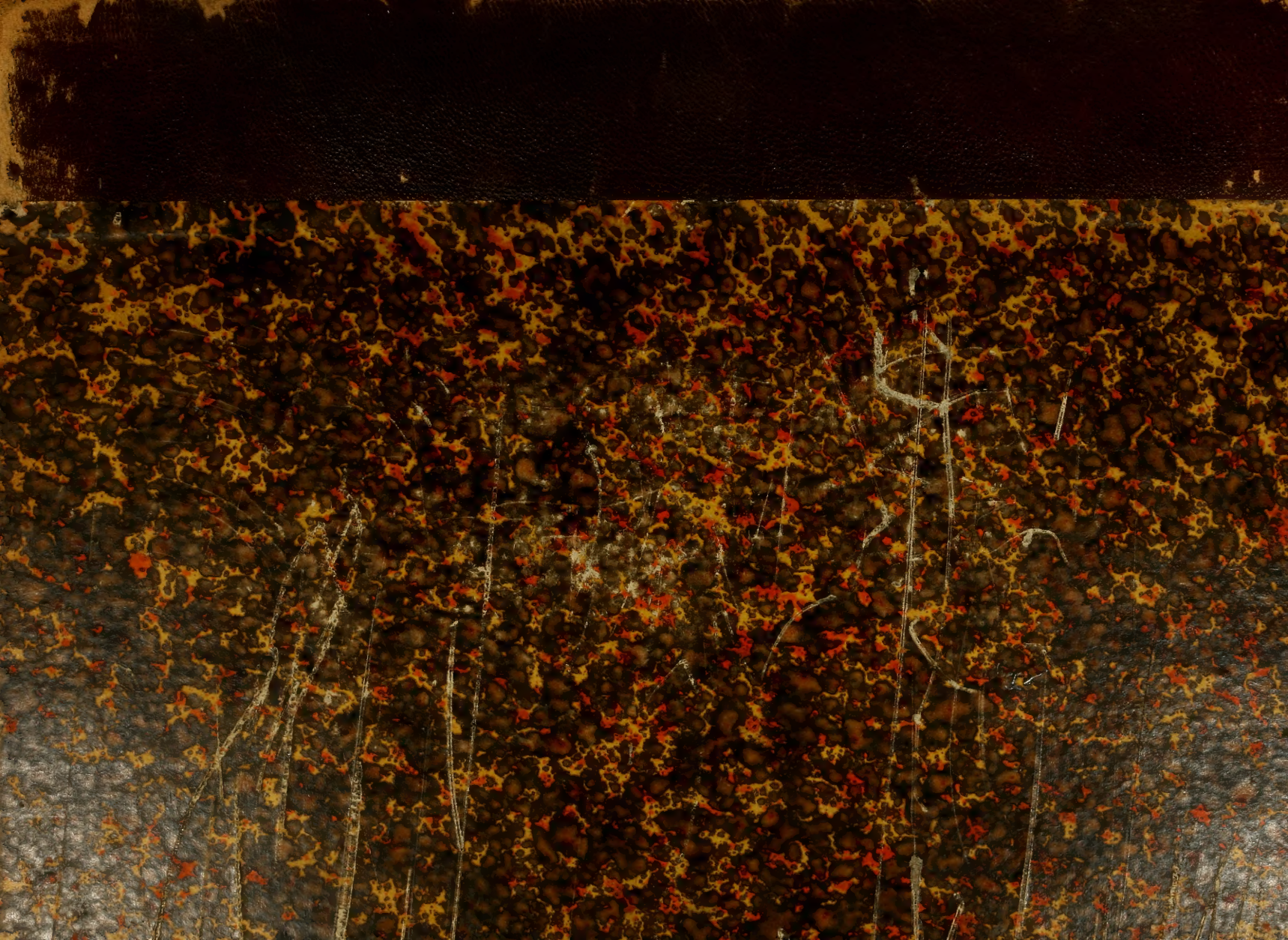
JAN 10 1907